

Radiographic Estimation of Post-Mortem Interval using Caudal Vena Cava Gas Changes in Dogs

Ibrahim Abdul-Azeez Okene^{1,3*}, Noordin Mohamed Mustapha² and Suleiman Omeiza Asuku³

¹Department of Clinical Studies, Faculty of Veterinary Medicine, Universiti Malaysia Kelantan, City Campus, Pengkalan Chepa, Kelantan, Malaysia

²Department of Pathology and Microbiology, Faculty of Veterinary Medicine, Universiti Putra Malaysia, Selangor, Malaysia

³A Faculty of Veterinary Medicine, University of Maiduguri, Maiduguri, Nigeria

***Corresponding Author:** Ibrahim Abdul-Azeez Okene, Department of Clinical Studies, Faculty of Veterinary Medicine, Universiti Malaysia Kelantan, City Campus, Pengkalan Chepa, Kelantan, Malaysia.

Received: July 23, 2019; **Published:** August 20, 2019

Abstract

Determining the post-mortem interval is essential in re-enacting the chronology of events for the forensic investigation of crimes involving death. The age-old invasive necropsy technique for the time of death estimation included evaluation of algor mortis, rigour mortis, livor mortis, imbibition, among others. Diagnostic imaging has opened a new era in the forensic investigation based on the principle that internal organismal changes can be appreciated and evaluated. Earlier studies observed gas development in tissues correlating to post-mortem interval. Post-mortem imaging is gradually making way for a non-invasive approach involving imaging. In this study, serial observation of post-mortem gas development in the caudal vena cava was done with the objective of determining the progression of gas formation in relation to post-mortem interval in canine carcasses. Five male dogs of similar body conditions were euthanized using 6% pentobarbital at 6 mg/kg body weight. Serial post-mortem abdominal radiographs were taken six (6) hourly until 24 hours at an ambient temperature of 22°C - 33°C. The ratio of the luminal height of the caudal vena cava to the height of the vertebral body of the fifth thoracic vertebra revealed no statistically significant differences across 24 hours post-mortem interval. However, gas intensity within the caudal vena cava lumen progressed synchronously with post-mortem interval. Assessment of gas intensity and luminal size to 5th lumbar vertebral body ratio of the caudal vena cava is a reasonable estimate of early post-mortem interval in dogs. Further field studies are necessary to test the applicability of estimating early post-mortem interval using radiographic changes in the caudal vena cava in dogs.

Keywords: Caudal Vena Cava; Dogs; Forensic Radiology; Gas Formation; Post-Mortem Interval Estimation

Abbreviations

CVC: Caudal Vena Cava; TVB: Thoracic Vertebral Body; °C: Degree Celsius

Introduction

Forensic science is a process entailing detailed investigation and collection of evidence regardless of whether there is a specific legal case or pending inquiry [1]. Some essential features or factors such as the scene(s) of crime investigation, DNA analysis, ballistic test, and toxicology are all encompassed in forensic science.

Forensic veterinary radiology is the application of knowledge and skills of veterinary radiology to the elucidation of facts in the Courts [2]. It deals with the use of X-rays and other imaging technologies to aid in investigating and gathering of evidence for use in the court of law, in civil and criminal cases. Wilhelm Roentgen pioneered the use of radiography for forensic purpose as early as 1896 when he resolved a gunshot case with the then newly discovered x-rays [3]. Computed tomography and magnetic resonance imaging are increasingly for non-invasive post-mortem examination to cause of death or injury as well as for identification of remains at local medical examiner offices or the scenes of mass casualties [4]. The first forensic application of computed tomography was a description of the pattern of gunshot injury to the head by Wullenweber, *et al* [5].

Post-mortem radiographic examination of animals is often performed in judicial investigations to rule out injuries and fractures due to cruelty or illegal hunting or poaching activities [6,7]. Radiography can detect changes which cannot easily be seen on routine necropsies [1] such as the presence of gas in luminal organs, size measurement of fluid containing lesions including cysts and seroma. Literature describing post-mortem changes seen on the radiograph of animals is scanty while knowledge of routine post-mortem radiographic findings is needed to help differentiate ante-mortem injuries and post-mortem artefacts especially in cases involving medico-legal investigation [8]. Many physicochemical changes begin to take place in the body immediately or shortly after death and progress in an orderly fashion until the body disintegrates [4]. These post mortem changes produce putrefaction by-products as they progress, which destroys evidence of identity, injuries, and natural disease [4]. Example of such changes includes the putrefactive gas formation that occurs in the vascular system, body cavities and soft tissues secondary to the decomposition of cadaver/carcass making post-mortem radiological interpretation in both human and animal a problematic task [9,10]. The progression of post-mortem gas formation in body tissues can be utilized in estimating post-mortem interval owing to the ability of imaging modalities such as radiography to pick up gas intensities [10]. Determining the time of death, otherwise called post-mortem interval is of value in re-enacting events surrounding a crime [11,12].

In medical forensic radiography (computed tomography and magnetic resonance imaging), thoracic post-mortem comprising of intracardial and sub-endocardial gas, as well as clotting with the sedimentation of the blood components, were considered normal findings [13] and secondary to cardiopulmonary resuscitation [14]. In retrospect, such normal gas formation can be harnessed in the quest for reliable post-mortem interval estimation. Estimation of post-mortem interval for medico-legal investigation is one of the significant challenges faced by the forensic practitioner tasked with providing precise and detailed evidence needed by the courts [2]. This needs to be done within a short time frame to avoid loss of details since the longer the post-mortem interval, the less accurate the estimation is because of environmental influence [15].

Consideration of whether a significant survival period (time from injury or terminal illness to death) is seen to have preceded the post-mortem interval is vital before any judgment can be passed for legal purpose. The survival interval is best established by considering the pre-existing natural diseases and evaluating the types, severity, and number of injuries present and the deceased's response to them. Significantly, general investigation about the presence of an individual in an area where a crime has been committed is of significant interest in estimating the post-mortem interval [2]. Ascertaining the estimated post-mortem interval helps the investigators in narrowing their thinking, thereby substituting and delineating specific events and suspect(s) although "the margin of error remains large and unpredictable, even in controlled research conditions, let alone for the more variable environment of an actual scene of death" [16]. Summarily, lots of research has been carried out to establish the cause of death in different case scenarios, but it remains controversial as to whether there is any sole, dependable and perfect means of post-mortem interval estimation for the forensic purpose [17].

In veterinary forensic practice, it is more tasking to select issue a single method for estimation of post-mortem interval in the context of the wide variety of species involved and their peculiarities [2]. However, reports from forensic veterinary pathologists on estimated post-mortem intervals proved useful in the investigation of a breach in the regulations that guide and protect the welfare of animals [2].

In this study, the serial post-mortem gas formation in the caudal vena cava of the dogs was observed with the objective of correlating same with early post-mortem interval estimation. This study helped to generate base-line information for practitioners and researchers in veterinary forensic radiology on the progression of post-mortem gas formation in the caudal vena cava for field application.

Materials and Methods

Five adult dogs sourced from the local city council were fed and hydrated ad libitum at the Animal Holding unit, Faculty of Veterinary Medicine, Universiti Putra Malaysia. They were euthanized with 6% pentobarbital (Euthetal®) at 6 mg/kg body weight. Serial lateral thoracic radiographs were taken at 6-hour intervals for 24 hours. Obtained images were observed for gas intensity changes and luminal height of the caudal vena cava. The luminal height of the caudal vena cava was measured and correlated with the height of the 5th thoracic vertebral body (VB) as described by Holloway and Fraser [18]. The caudal vena cava (CVC) under routine radiography emerges via the right crus of the diaphragm and slopes slightly cranio-ventrally before merging with the caudal outline of the heart. Carcasses were kept at a standard ambient temperature of 22 - 33°C on left lateral recumbency during the study period and were only manipulated every 6 hours for radiography positioning.

Results of 6-hourly values of the ratio of the height of the 5th thoracic vertebral body to the luminal height of the caudal vena cava were plotted on a graph and presented in figure 1. Both heights were measured in centimetres using meter rule, and the ratios are presented without units. Thus, increasing value of ratios indicates a decreasing denominator value (caudal vena cava) and vice versa.

Results and Discussion

The caudal vena cava, as shown in figure 1, is the closely similar luminal size as the height of the 5th thoracic vertebral body.

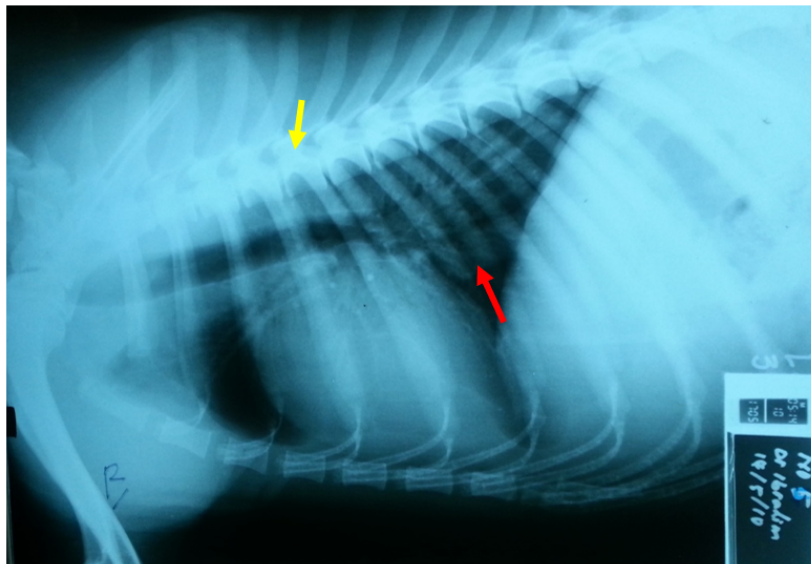


Figure 1: Showing the comparative luminal height of caudal vena cava (red arrow) to the 5th thoracic vertebral body height (yellow arrow).

Mean ± SD of ratios obtained from the 0-hour radiographs (0.98 ± 0.07) were within the approximate average size of the caudal vena cava, as described by Holloway and Fraser [18] and Thrall [7]. There was no statistically significant difference in CVC luminal size changes during the 24-hour study period (Table 1).

	0 hour	6 hours	12 hours	18 hours	24 hours
Dog 1	1.00	1.00	1.00	0.90	0.90
Dog 2	1.00	0.95	0.95	0.87	0.85
Dog 3	0.9	0.85	0.83	0.81	0.80
Dog 4	1.10	1.00	1.00	0.95	0.94
Dog 5	0.89	0.88	0.88	0.85	0.82
Average	0.98	0.94	0.93	0.88	0.86

Table 1: Showing the ratio of the luminal height of the CVC and the height of the body of T₅ on the left lateral thoracic view.

Graphical representation of the luminal ratio changes in table 1 revealed a closely linear pattern for average values (Figure 2). An R-value of 0.946, it signifies a strong correlation between the post-mortem CVC changes and post-mortem interval. Besides, it provides an avenue to generate a representative linear equation to predict early post-mortem interval. This is the unique outcome of this study, which is the first to report this phenomenon.

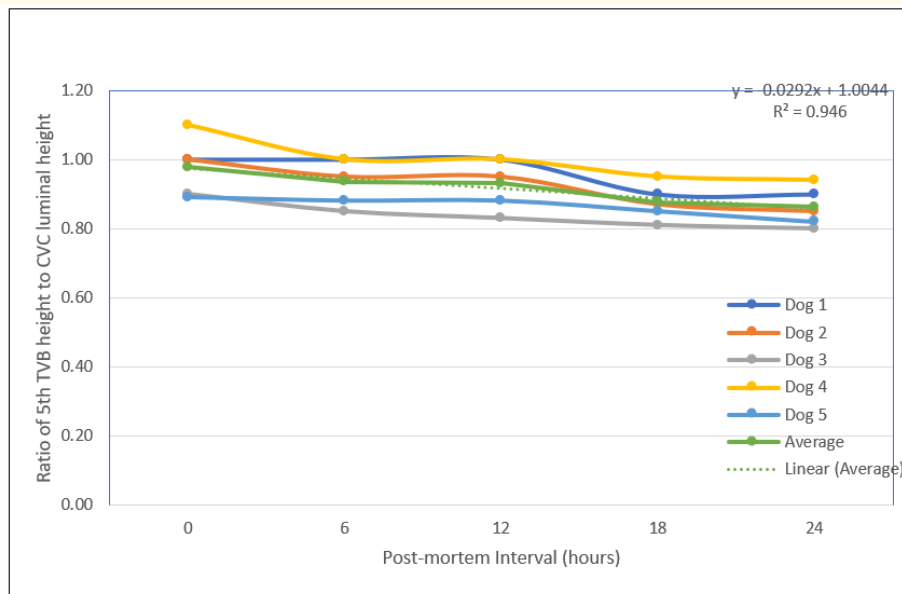


Figure 2: Showing the graphical representation of Table 1 and the linear relationship between average 5th Thoracic Vertebral Body (TVB) height and CVC luminal height.

Nevertheless, gas changes within the lumen were observed to progressively increase in intensity from 0 to 24 hours post-mortem (Figure 3a-3e). Heng, *et al.* [10] reported similar gas changes in the caudal vena cava lumen of the which they attributed to the antegrade movement of putrefactive bacteria present within the gastrointestinal tract especially the stomach and the intestine immediately pre-mortem. These organisms after death might have migrated from the GIT through the venous blood collection by the portal vein into the sinusoid of the liver where via the hepatic veins gets into the caudal vena cava and proliferate resulting in gas production. Peculiar to this study, however, is the early detection of gas by the 6th-hour post-mortem, in comparison to the 8 hours post-mortem reported by Heng, *et al* [10]. The 2-hour margin of detection obtained in this study is essential in the rapid deductive analysis of evidence trail in criminal investigations.

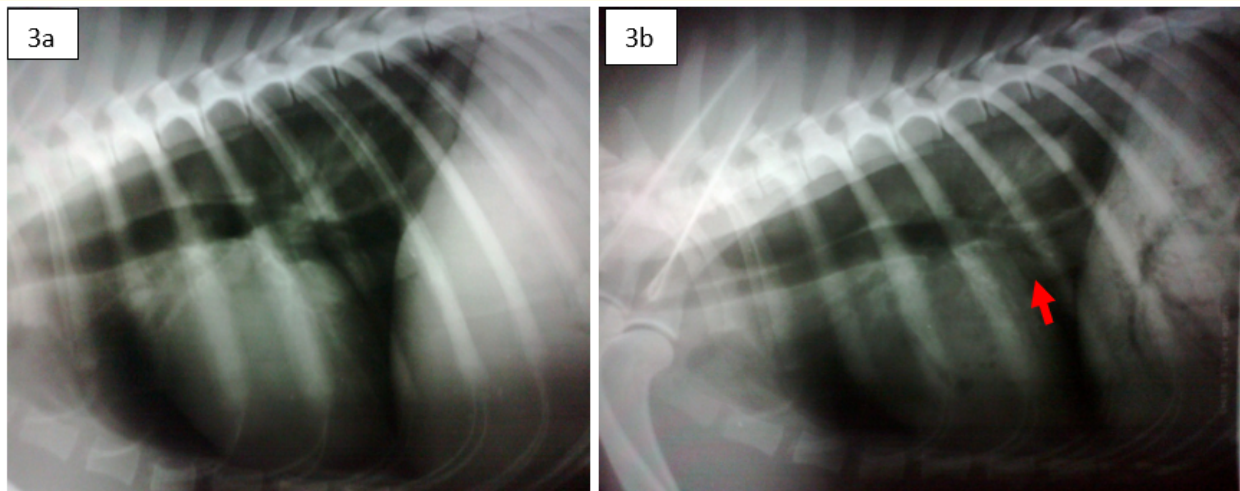


Figure 3a: Showing caudal vena cava at 0-hour post-mortem, and 3b showing the presence of gas pocket in the caudal vena cava (red arrow) at 6-hours post-mortem.

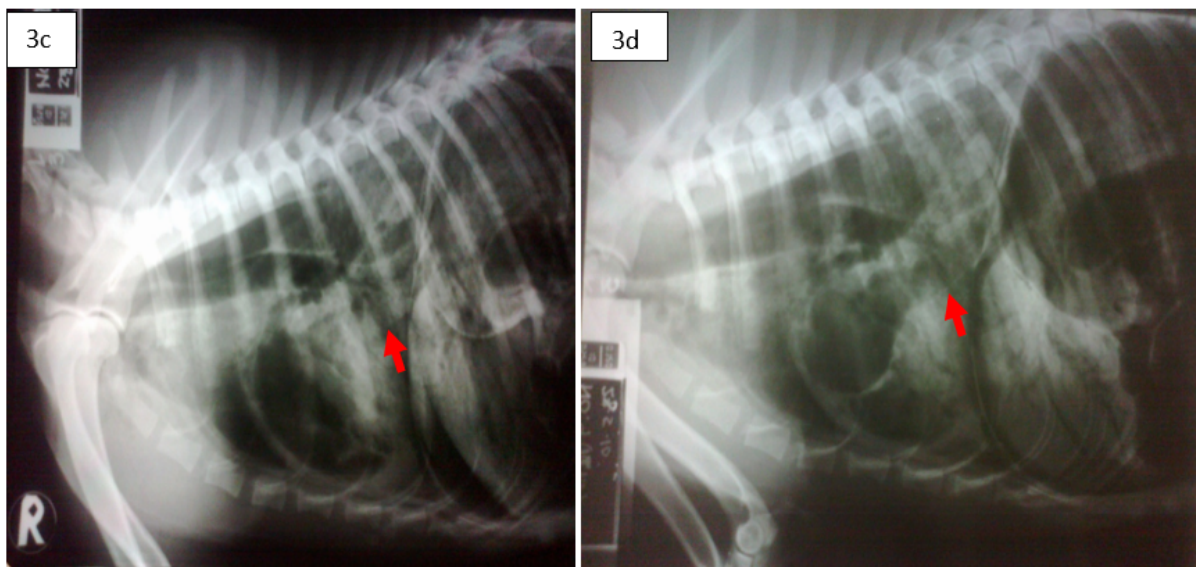


Figure 3c: Showing a progressive increase in gas in the caudal vena cava (red arrow) at 12-hour post-mortem and 3d with a marked increase of gas in the caudal vena cava lumen (red arrow) at 18-hours post-mortem.

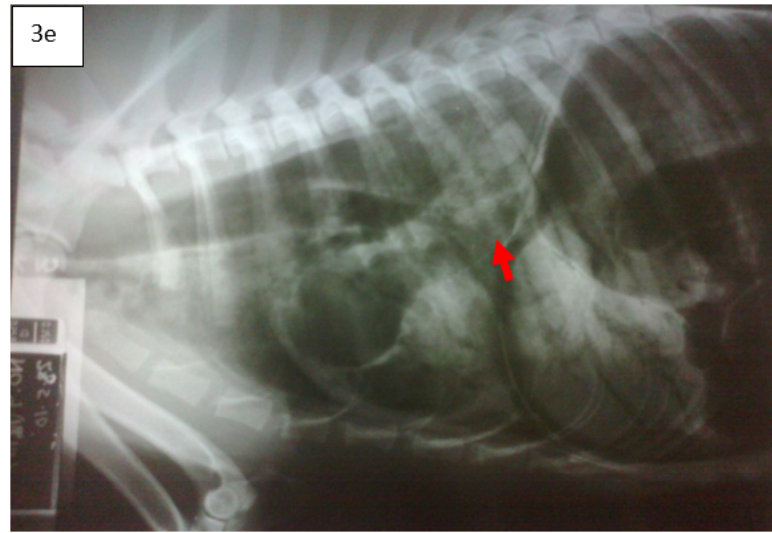


Figure 3e: Showing marked gas presence in the caudal vena cava (red arrow) at 24-hours post-mortem.

Rapid progression of gas formation in the caudal vena cava at 6-hours post-mortem is suggestive of an early putrefactive process occurring in the ambient condition existing during the study period (22°C night to 32°C during the day). This environmental factor explains the disparity with earlier reports of 8 hours in which experimental conditions warranted storage in a cold room before each radiography session. In this study, the dog carcasses were placed in the open post-mortem room for the 24 hours to mimic natural ambiance in Malaysia (temperature and relative humidity). Moreover, adequate measures were taken strictly following the international guidelines on the use of injectables during the euthanasia protocol, thus excluding the possibility of bacterial contamination [10,19].

Conclusion

The caudal vena cava is a good indicator for radiographic estimation of post-mortem interval in dogs. This study has revealed that gas accumulation and luminal height changes do occur in the caudal vena cava beginning from 6-hours post mortem. Progression of gas formation in the caudal vena cava follows a closely linear pattern that can be used for estimation of early post-mortem interval for field application. These findings may then be used as a guide for providing baseline data in estimating post-mortem interval in dogs for forensically related cases, and it may also be explored by extension for medical forensics.

Acknowledgements

The authors wish to acknowledge the Malaysian Ministry of Science Technology and Innovation for providing the research grant for this study through the eScience Fund.

Conflict of Interest

The authors declare that there is no financial interest or any conflict of interest existing relating to this manuscript.

Bibliography

1. Cooper JE and Cooper ME. "Introduction to veterinary and comparative forensic medicine". Blackwell Publishing, Oxford, Ames, IA (2007).
2. Munro R and Munro H. "Forensic veterinary medicine". *Post Mortem Investigation in Practice* 33 (2012): 262-270.

3. Brogdon BG. "Textbook of Forensic Radiology". Boca Raton: CRC Press (1998).
4. Thali MJ, *et al.* "Forensic Veterinary Radiology: ballistic-radiological 3D Computer tomographic reconstruction of an illegal lynx shooting in Switzerland". *Forensic Science International* 171.1 (2007): 63-66.
5. Wullenweber R, *et al.* "A computer tomographical examination of cranial bullet wounds". *Zeitschrift für Rechtsmedizin* 80.3 (1977): 227-246.
6. Munro R and Munro H. "Animal abuse and unlawful killing: Forensic veterinary pathology". Saunders Elsevier, Edinburgh (2008).
7. Thrall DE. "Textbook of Veterinary Diagnostic Radiology". WB Saunders, Philadelphia (2018).
8. Mirza FH and Makdoom PA. "Importance of correct interpretation of post-mortem artefacts in medico-legal autopsies". *Journal of Pakistan Medical Association* 48.2 (1998): 49-50.
9. Dirnhofer R, *et al.* "VIRTOPSY: Minimally invasive imaging guided virtual autopsy". *Radiographic* 26.5 (2006): 1305-1333.
10. Heng HG, *et al.* "Serial postmortem thoracic radiographic findings in Canine Cadavers". *Forensic Science International* 188.1-3 (2009): 119-124.
11. Henssge C. "Death time estimation in casework: The rectal temperature time of death nomogram". *Forensic Science International* 38.3-4 (1988): 209-236.
12. Henssge C. "Temperature based method II in: Estimation of the time since death in the early postmortem period". 2nd Edition, London (2002): 43-102.
13. Jackowski C, *et al.* "Virtopsy: Postmortem imaging of the human Heart in situ using MSCT and MRI". *Forensic Science International* 149.1 (2005): 11-23.
14. Shiotani S, *et al.* "Cardiovascular gas on non-traumatic post-mortem computed tomography (PMCT): The influence of cardiopulmonary resuscitation". *Radiation Medicine* 23 (2005): 225-229.
15. Polson G and Knight. "The Essential of Forensic Medicine". 4th Edition, Pergamon Press, Oxford (1985).
16. Knight B. "The Evolution of method for estimating the time of death from body temperature". *Forensic Science International* 36.1-2 (1988): 47-55.
17. Swift B. "Method of time since death estimation within the early post mortem interval". *Journal of Homicide and Major Incident Investigation* 6 (2010): 97-112.
18. Holloway A and Fraser M. "BSAVA Manual of Canine and Feline Radiography and Radiology". British Small Animal Veterinary Association (2013).
19. Stawicki SP, *et al.* "The dead continue to teach the living: examining the role of computed tomography and magnetic resonance imaging in the setting of postmortem examinations". *Journal of Surgery Education* 65.3 (2008): 200-205.

Volume 4 Issue 7 September 2019

©All rights reserved by Ibrahim Abdul-Azeez Okene, *et al.*