

Clinical and Radiographic Evaluation of Osteodisc Allograft Impregnated with Mesenchymal Stem Cells for Replacement of Normal Cervical Disc in Dog

Shaghaegh Rafatpaneh Baigi¹, Davood Sharifi^{1*}, Mohammadreza Golbakhsh², Sarang Soroori¹, Fatemeh Aramesh¹ and Alireza Bashiri¹

¹Department of Veterinary Surgery and Radiology, Faculty of Veterinary Medicine, University of Tehran, Tehran, Iran

²Department of Orthopedic Surgery, Sina Hospital, Tehran University of Medical Sciences, Tehran, Iran

***Corresponding Author:** Davood Sharifi, Department of Veterinary Surgery and Radiology, Faculty of Veterinary Medicine, University of Tehran, Tehran, Iran.

Received: October 24, 2018; **Published:** December 01, 2018

Abstract

Cervical disk problems are very common among both humans and dogs. Anterior discectomy and fusion (ACDF) is the surgical method of choice in people. Nevertheless, it will inevitably lead to adjacent segment involvements in the long run. Ventral slot, which is the preferred surgical treatment in dogs with cervical discopathy, similarly leads to domino lesions.

This study was designed to address the need for a more practical method of treatment in dogs, which could be extrapolated to people in future.

8 mongrel dogs were selected, 2 of which served as donors of cervical osteodisc allografts. The remaining 6 dogs formed two groups of recipients, the first group received osteodisc allograft impregnated with a mesenchymal stem cells in C3-C4 intervertebral space. The second group received the transplantation without mesenchymal stem cells. 6 months after the surgery, both groups were subject to neurological examination and radiographic evaluation.

The dogs showed no sign of neurological impairment and no pain was elicited in the cervical area. Upon radiographic examination, no dislocation of the osteodisc allograft could be detected. Osteophyte formation was observed. osteodisc density was heterogeneous, spinal canal had normal shape in 4 dogs, and fine fractures were detected in 4 dogs.

In conclusion osteodisc allograft seems to be a viable option in treating cervical disk problems in dogs.

Keywords: Cervical; Disc; Dog; Spine; Stem Cellst

Introduction

Intervertebral disc degeneration is a common process in cervical vertebrae and generally the result of the natural aging process [1]. Cervical pain is considered one of the major debilitating factors which not only imposes considerable emotional and socioeconomic strains on the patient [2], but also inflicts tremendous burden upon the national health care system of every country.

Intervertebral discs are chondral tissue attached to vertebral body and comprise 30% of the vertebral column length. Intervertebral discs are responsible for stabilizing the body and are thus extremely important for maintaining balance and equilibrium [3]. Moreover, the complex structure of these discs enable it to absorb forces inflicted on the body during normal physical activities [3].

Among the various methods of treatment developed for intervertebral disc disease in the cervical region, surgery appears to be the most reliable approach. Anterior cervical discectomy and fusion (ACDF), especially when only one disc space is affected, is usually the

surgical treatment of choice [4-7]. Nevertheless, long-term reports document an incidence of domino effect at the adjacent sites and the recurrence of neurologic symptoms. Domino lesions or adjacent segment disease are in part considered to be the resulting from abnormal stresses on a single intervertebral space caused by fixation [4-8]. Within 10 years after the first surgery, subsequently about 25% of patients require a 2nd surgery at an adjacent site [9].

Numerous alternatives to ACDF have been investigated including total disc replacement with use of artificial discs, which has proved to be almost as effective as ACDF. Although total cervical disc replacement could potentially be a significant treatment option for spinal disorders, the precise role and potential utility of this procedure in comparison to other available treatments remain uncertain [7].

Cervical intervertebral disc disease, both types I and II of Hansen classification and cervical spondylomyelopathy or Wobbler's syndrome are amongst the most common spinal cord problems in dogs [10,11]. Various surgical techniques have been described for the treatment of cervical intervertebral disc disease, including ventral slot, ventral slot and decompression (VSD), VSD with fixation and dorsal laminectomy [10-12]. Many authors using these surgical techniques claim a 70 - 90% success rate [12]. However, similar to humans, adjacent segment disease and domino lesions pose a considerable risk in dogs too. In one study, use of artificial implants for cervical disc arthroplasty in dogs was introduced. Nonetheless, adverse effects including metal corrosion or wear of the bearing surface cannot be underestimated [12].

All of these shortcomings present a need for a more reliable treatment option, which would pose fewer risks to the patient in the long run and eliminates further operations in the future. The purpose of this study was to determine the feasibility of utilizing osteodisc allografts impregnated with mesenchymal stem cells in the dog. Furthermore, survey the changes made to the allograft after being transplanted by means of radiographic evaluation. To the author's knowledge, this is the first study contemplating the clinical outcome and radiographic evaluation of osteodisc allografts impregnated with mesenchymal stem cells as a substitute to conventional surgical methods in the dog.

Materials and Methods

Eight healthy, adult, medium-sized (25 ± 5 kg) mongrel dogs were randomly selected for the purpose of this study. Firstly, all of the dogs received vaccination and anti-parasite therapy. Two of the dogs were selected as donors and were subjected to radiographic and magnetic resonance imaging to ensure the health of the cervical vertebral column and intervertebral discs. Transplantation surgeries were carried out on two sessions. On each session, one of the donors was humanely euthanized and afterwards cervical vertebrae were freshly harvested under aseptic measures in the operating room.

A total of three intervertebral discs along with end-plates on both sides and a portion of vertebral bodies were isolated (Figure 1) and kept in sterile saline (0.9% sodium chloride solution) in order to be transplanted in three recipient dogs.

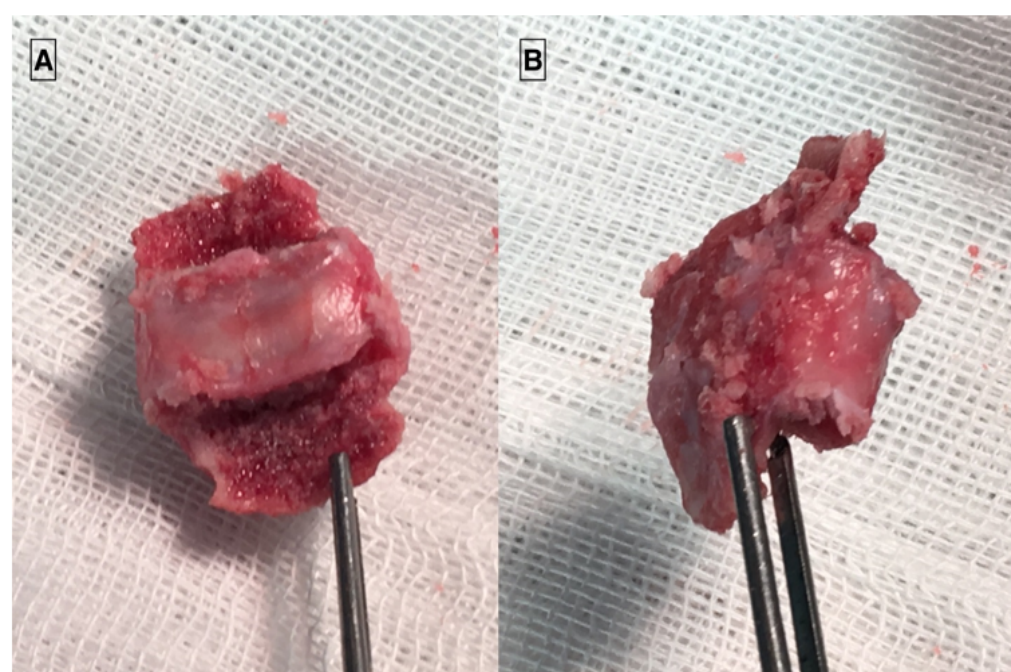


Figure 1: The osteodisc allograft before transplantation. A) The osteodisc allograft seen from the dorsal aspect, B) The allograft from the caudal aspect.

Each of the recipient dogs were premedicated with an intramuscular injection of Ketamin (10 mg/kg, Alfasan, The Netherlands) and Xylazine (0.5 mg/kg, Alfasan, The Netherlands) and afterwards the ventral cervical area was thoroughly clipped and prepared aseptically. After receiving an intravenous prophylactic dose of Cefazolin (22.5 mg/kg, Exir, Iran), anesthesia was induced with an intravenous cocktail of Ketamin (5 mg/kg) and Diazepam (0.25 mg/kg, Caspian Tamin, Iran). Following endotracheal intubation, inhalation anesthesia was maintained with Isoflurane. With a ventral approach to the cranial cervical region, the third and fourth cervical vertebrae were identified and the respective intervertebral disc along with endplates on both cranial and caudal aspects were removed using pneumatic air drill. On the first session, the allograft osteodisc transplants impregnated with 1 ml broth of autologous mesenchymal stem cells in platelet rich plasma were transplanted in the three dogs. On the second session the same process was repeated except for the use of autologous mesenchymal stem cells in platelet rich plasma. Fixation of the transplant was achieved using two screws. Routine closure of the surgical site preceded the radiographic evaluation of the cervical vertebra to ensure the correctness of the procedure.

Afterwards a protective brace around the neck was placed and the dogs were transferred to their respective cages. Post-operative care consisted of analgesia achieved by intramuscular injection of Tramadol (2 mg/kg q12h, Alborz Darou, Iran) for 3 days and changed to oral Tramadol (4 mg/kg q12h, Alborz Darou, Iran) for 5 days. Intravenous Cefazolin (22.5 mg/kg q12h) was administered for one week. The neck brace was removed two weeks post-operatively. Physical and neurological examination of the dogs were performed 1 week, 1 month and 6 months' post operatively.

After 6 months, neurologic exam and radiographic evaluation of all 6 dogs were performed, following which they were humanely euthanized.

Mesenchymal stem cells

In each of the three recipient dogs in the first group, approximately 10 cc bone marrow was harvested in a heparinated syringe (700 u/ml) under aseptic conditions from the greater trochanter of humerus at the shoulder joint. Cell extraction and culture was undertaken in the laboratory according to established principals. For obtaining platelet rich plasma, 10 cc blood was drawn from the jugular vein of each of the 3 dogs in the first group prior surgery. The platelet rich plasma was then prepared in the laboratory and a syringe containing mesenchymal stem cells in platelet rich plasma was delivered to the operating room to utilize for each recipient dog.

Diagnostic imaging

All 6 recipient dogs underwent radiographic evaluation immediately after surgery, and 6 months after surgery. Sedation was achieved with intramuscular injection of Ketamin (10 mg/kg, Alfasan, The Netherlands) and Xylazine (0.5 mg/kg, Alfasan, The Netherlands) and afterwards an intravenous cocktail of Ketamin (5 mg/kg) and Diazepam (0.25 mg/kg, Caspian Tamin, Iran).

To perform a lateral view, the dogs were placed in lateral recumbency, with the head extended in a true lateral position. The radiographs were taken with Carestream's Direct view Classic CR.

Results

Physical and neurological examination findings

Routine physical and neurological examination were performed at 1 week, 1 month and 6 months post-operatively.

All of the 6 dogs were ambulatory 1 week after surgery. Neck pain was a common finding among all of the dogs which limited range of neck motion. Pain was elicited by putting the neck through extension, flexion and movement to the left and right sides. Physical and neurological examination findings were otherwise unremarkable.

One month post-operatively, the routine examination was repeated for all of the dogs. The pain in the neck region had subsided and extension and flexion exercises were met with much less resistance. The ambulation of the dogs were all normal and clinical findings were unremarkable. 6 months after the operation, the final examination was carried out. All of the 6 dogs were walking and running normally with no signs of lameness or ataxia. Neurological examination results were within normal limits and no evidence of neurological deficit was detected. No pain was elicited by extension, flexion and movement to both side in the neck region.

Diagnostic imaging results

Radiographic evaluation of recipient dogs 6 months post-operatively demonstrated the allograft in C3-C4 disc space (Figure 2). Osteodisc opacity was heterogeneous in all of the 6 dogs. No dislocation of the allograft was observed in any of the dogs. One of the dogs from the second recipient group which did not receive mesenchymal stem cells in the surgery site, showed signs of discopathy in the adjacent disc space C2-C3. There was mild osteophyte formation discernable in each of the dogs. The complications observed were fine fractures in 2 of the dogs at the body of C4 vertebrae, and in 2 other dogs at the location of the screw in the C3 vertebrae.

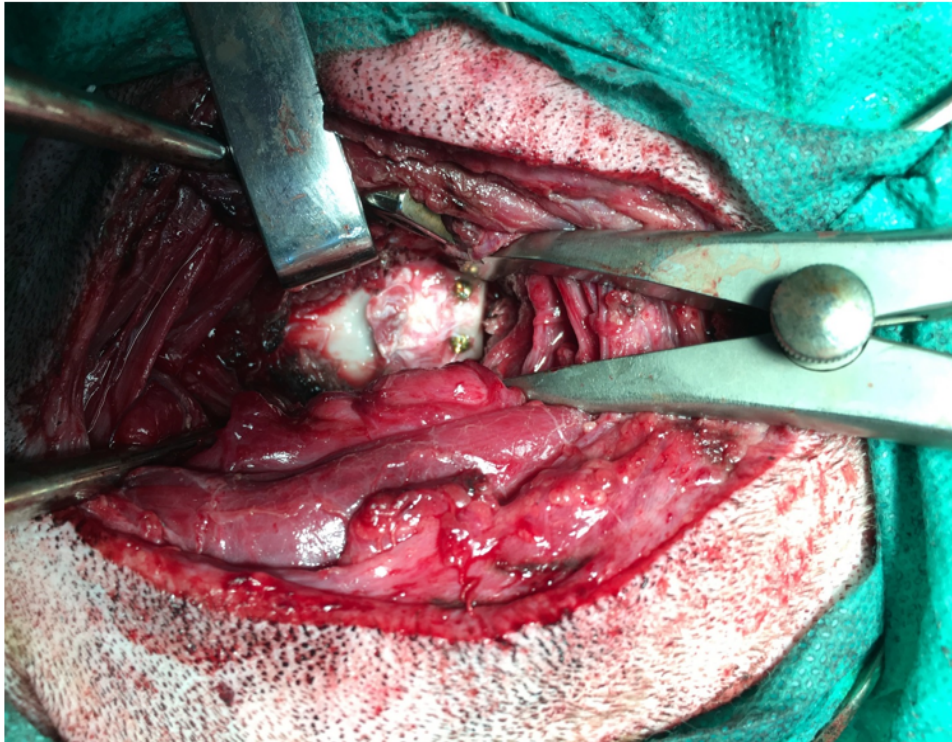


Figure 2: The osteodisc allograft after transplantation.

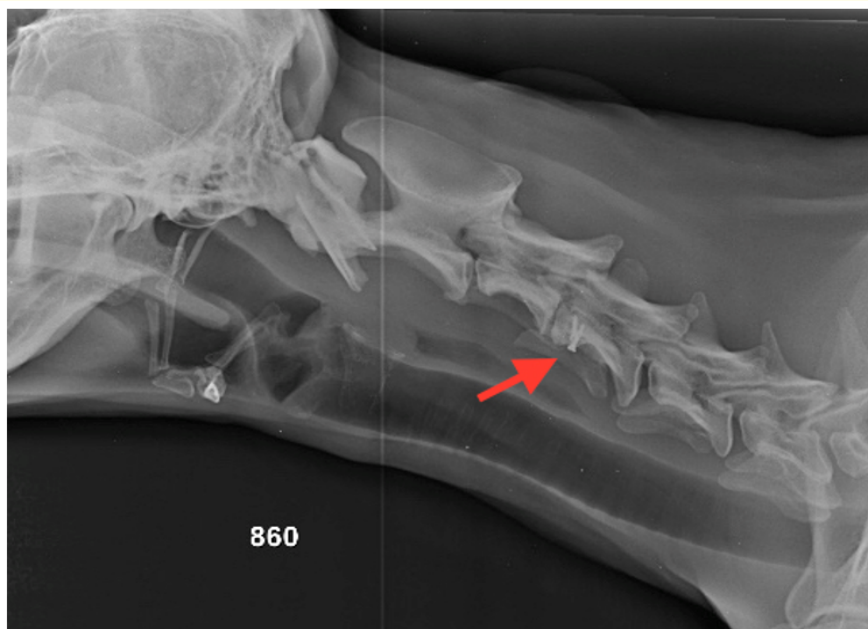

Figure 3: Lateral radiograph taken from one of the recipient dogs 6 months after transplantation surgery. The arrow shows the osteodisc allograft.

Discussion

The most effective method of management for cervical disc disease remain an enigma in both human and dogs. Current surgical treatments that involve discectomy and fusion are successful in eliminating pain but fail to restore disc functionality [13].

Among the first experiments involving allografts to address this issue was the study conducted by Olsen, *et al.* in 1991 in dogs' thoracic vertebral column, transplanting T8 vertebrae along with parts of T7 and T9 attached to it. In this study the allografts had been frozen after harvest, and thawed later to be implanted in the donors' vertebral columns. This study showed that these allografts were able to function normally for 18 months [14].

Another study by Frick, *et al.* in 1994 was conducted. During surgery on the lumbar vertebrae, the disc and very small amounts of adjacent bone and end plates were removed from one space and transplanted into the adjacent disc space in the same dog. This study concluded that despite normal histological characteristics of the transplanted discs, their appearance was aberrant [15].

A more recent study evaluated the results of disc transplantation from healthy female humans who had perished due to trauma. The allografts were freshly frozen. This study concluded that although during the 5-year follow-up, discs showed signs of degeneration, the overall motion and stability of the spinal unit was preserved [16].

This study is unique in the fact that osteodisc allografts were freshly transplanted to recipient dogs and were not subject to freezing. Moreover, the dogs were observed 6 months after the surgery to evaluate gait, neck pain and motion, and neurological status. The dogs in our study demonstrated normal gait and neurological features following the transplantation. Cervical pain could not be elicited 6 months' post-operation. No clinical evidence of pressure on the spinal cord was discerned. To our knowledge no other study has evaluated the dogs' neurological status after osteodisc allograft transplantation.

Although some degree of changes in the nucleus pulposus was to be anticipated, diagnostic imaging failed to demonstrate a considerable pressure on spinal cord. However, evidence of bony changes and osteophyte formations were found in radiography images.

Conclusion

In conclusion, despite changes observed in diagnostic imaging, the clinical picture was favorable for the study dogs.

As for recommendations for future studies, a larger sample size and longer duration of follow-up would be beneficial to reach more accurate results. Since current techniques in addressing cervical disk problems give rise to complications in a matter of years.

Bibliography

1. Buckwalter JA. "Aging and degeneration of the human intervertebral disc". *Spine* 20.11 (1995): 1307-1314.
2. Caridi JM., *et al.* "Cervical radiculopathy: a review". *HSS Journal* 7.3 (2011): 265-272.
3. Coates JR. "Intervertebral disk disease". *Veterinary Clinics of North America: Small Animal Practice* 30.1 (2000): 77-110.
4. Auerbach JD., *et al.* "The prevalence of indications and contraindications to cervical total disc replacement". *Spine Journal* 8.5 (2008): 711-716.
5. Sugawara T. "Anterior cervical spine surgery for degenerative disease: a review". *Neurologia Medico-Chirurgica* 55.7 (2015): 540-546.
6. Matsunaga S., *et al.* "Strain on intervertebral discs after anterior cervical decompression and fusion". *Spine* 24.7 (1999): 670-675.

7. Nanda A., *et al.* "Surgical complications of anterior cervical discectomy and fusion for cervical degenerative disc disease: a single surgeon's experience of 1576 patients". *World Neurosurgery* 82.6 (2014): 1380-1387.
8. Murrey D., *et al.* "Results of the prospective, randomized, controlled multicenter Food and Drug Administration investigational device exemption study of the ProDisc-C total disc replacement versus anterior discectomy and fusion for the treatment of 1-level symptomatic cervical disc disease". *Spine Journal* 9.4 (2009): 275-286.
9. Hilibrand AS., *et al.* "Radiculopathy and myelopathy at segments adjacent to the site of a previous anterior cervical arthrodesis". *Journal of Bone and Joint Surgery* 81.4 (1999): 519-528.
10. Jefferyq ND and McKee WM. "Surgery for disc associated wobbler syndrome in the dog-an examination of the controversy". *Journal of Small Animal Practice* 42.12 (2001): 574-581.
11. Rossmeis! Jr JH., *et al.* "Acute adverse events associated with ventral slot decompression in 546 dogs with cervical intervertebral disc disease". *Veterinary Surgery* 42.7 (2013): 795-806.
12. Adamo PF., *et al.* "In vitro biomechanical comparison of cervical disc arthroplasty, ventral slot procedure, and smooth pins with polymethylmethacrylate fixation at treated and adjacent canine cervical motion units". *Veterinary Surgery* 36.8 (2007): 729-741.
13. Mizuno H., *et al.* "Tissue-engineered composites of anulus fibrosus and nucleus pulposus for intervertebral disc replacement". *Spine* 29.12 (2004): 1290-1297.
14. Olson EJ., *et al.* "Vertebral column allografts for the treatment of segmental spine defects. An experimental investigation in dogs". *Spine* 16.9 (1991): 1081-1088.
15. Frick SL., *et al.* "Lumbar intervertebral disc transfer. A canine study". *Spine* 19.16 (1994): 1826-1834.
16. Ruan D., *et al.* "Intervertebral disc transplantation in the treatment of degenerative spine disease: a preliminary study". *Lancet* 369.9566 (2007): 993-999.

Volume 3 Issue 3 December 2018

©All rights reserved by Davood Sharifi., *et al.*