

## Prolotherapy Treatment in a Dog with Hemiparesis Unilateral by Spinal Cord Compression Associated Adisco Espondiloartrosis

D Rodriguez Velazquez<sup>1,3\*</sup> and LF Hernandez Cejudo<sup>2,3</sup>

<sup>1</sup>Department of Veterinary Medicine, Autonomous University of the State of Mexico, Mexico

<sup>2</sup>Medical Zoo Technician, Certified Specialist Professor Autonomous Mexico State University, Mexico

<sup>3</sup>Hospital Valley, Fray Gregorio Jimenez Basin, Valley Square, Mexico

**\*Corresponding Author:** D Rodriguez Velazquez, Faculty of Veterinary Medicine, Autonomous University of the State of Mexico, University Center El Cerrillo Piedras Blancas, C.P 50200, Toluca, Mexico.

**Received:** September 4, 2015; **Published:** May 26, 2016

### Summary

Prolotherapy is based on the application of substances at the site where the ligaments and tendons are attached to the bone, or in the form intra articular for the regeneration of these structures. In this paper the case of a dog with unilateral hemiparesis by spinal cord compression associated with discoespondiloartrosis which shows the effectiveness of prolotherapy treatment in patients who present with osteodegeneratives diseases and also is compromised nerve function is reported. Monitoring the process of rehabilitation same occurred, confirming the clinical value conferred by the application of treatment for which a satisfactory patient recovery was obtained, thus improving their quality of life.

**Keywords:** Prolotherapy; Hemiparesis; Spinal cord compression; Ligaments

### Introduction

Prolotherapy is a complementary medical therapy and in filtrations based alternative for the treatment of chronic musculoskeletal pain mainly [1]. While it has been used for about 100 years, modern your application lies with the formalization of protocols infiltration by George Hackett, which defined the prolotherapy as “the rehabilitation of an incompetent structure by the generation of new cell tissue”. The mechanism of action had not been clearly established and supported by the evidence of the three most widely used solutions, today is evidenced by biopsy, the enlarged unionhueso-tendon, ligament thickening and strengthening tendons and ligaments [2], also it has been hypothesized stimulation of the release of growth factors that promote healing of soft tissues [3]. Chronic pain experienced by patients and degenerative processes such as discoespondiloartrosis develop when the tissues that support the joints not completely heal after injury or because they occur in congenital or form inherited a type of instability [4]. They are considered then that injections ligament trigger an influx of granulocytes, macrophages and fibroblasts, the release of growth factors and last term, collagen deposition better quality than the tendinous structures or ligament damaged and so thus strengthening ligaments and reducing pain and disability.

In animal studies which have been applied prolotherapy has been demonstrated by biopsy, the enlarged unionhueso-tendon ligament thickening and strengthening tendons and ligaments [2]. Its application in Veterinary Medicine, has been studied for several years in our clinical experience are confident of the effectiveness of prolotherapy treatment mediated improvements that have taken over several years in patients who have been subjected to this. So, this paper attempts to demonstrate once again the efficacy and safety provided by its use in the various congenital and acquired musculoskeletal diseases of dogs and cats.

**Clinical case**

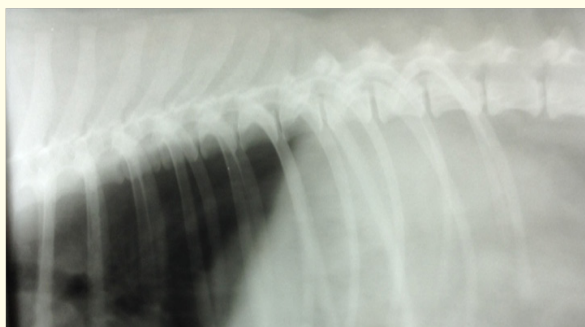
You receive a consultation Roy patient race Husky Siberiano 4 years old which discussed the owners have noticed who struggles to get up and move for three weeks, the day of the consultation, this has been increasing more and more plus. They say it is a very active dog and now much is no longer moving. It presents vaccination and de worming schedule to date.

General physical examination in which the following results are observed is performed.

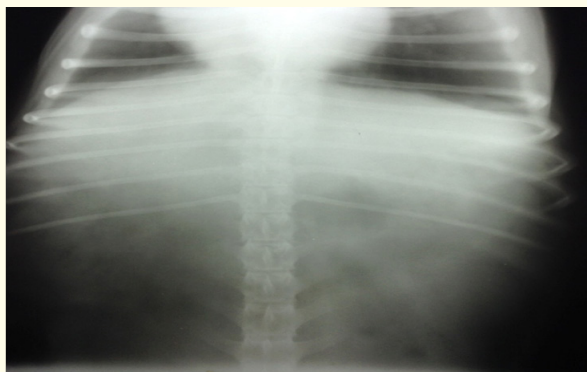
Weight	27.600 kg
Lymph nodes	Normal
Capillary filling time	1 Second
Heart rate	112 L.P.M
Breathing frequency	22 R.P.M
Body temperatura	38.6
reflection Tusigeno	Negative
Lung fields	sounds Normal
Abdominal palpation	Without changes
Palm percussion	Negative
Hydration %	Normal

After performing a physical examination, neurological examination was performed showing alert and responsive and showed a recumbent posture located in space. As for moving the patient examination showed left hemiparesis ataxia with loss of balance at all times. He continued to assess postural reactions mostrando propiocepcion retardada del left forelimb and pelvic. In hemiostancia the animal showed loss of coordination delayed response on the left side [5]. He continued to assess in detail the 12 cranial nerves without finding alterations, resulting pattern of knowing that the injury was not in the central nervous system [6].

Later reflections from the thoracic limbs (extensor radial, triceps and biceps carpus) normal reflexes of the pelvic members (reflejo rotuliano, cranial tibial and gastrocnemius) without visible changes and seobservo pánico or increased common core reflection between observed segments vertebrales T4-T13 and L1-L7 with presence of superficial and deep pain. Due to that observed in the neurological examination, it was decided to perform orthogonal radiographic study (Figure 1 and 2) in the which the decrease was observed in the intervertebral space T7-T8-T9y L1-L2-L3-L4 with formation of “spikes parrot “is observed and also loss of light in the same vertebral canal portion [7].



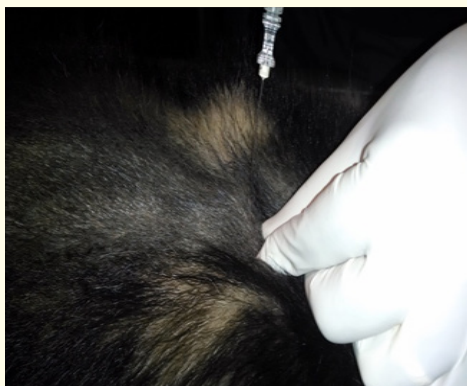**Figure 1:** Radiografía. Toma lateral decubitus left-right in which closure of vertebral spaces is observed throughout the segment, more demarcation between T7 -T8 space -T9 -T10 and L1 -L2 -L3 -L4, note well the “parrot peaks” of the vertebral bodies across the thoracolumbar segment and in the presence of T4-T5 sclerosis space.



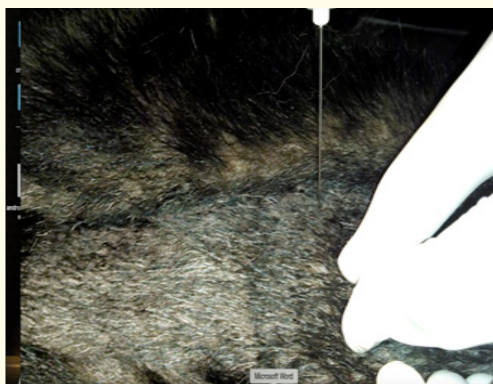**Figure 2:** X-ray. Takes ventro-dorsal thoracolumbar portion, closing the intervertebral spaces more demarcation T7-T8 in the segment, T9 and T10-L1-L2-L3, presence of sclerosis in space T9-T10 shown.

Once complete neurological exam information collated with imaging studies was obtained, the patient is diagnosed with thoracic spinal cord compression associated with discoespondiloatrosis. Spinal cord compression compromises the sensory and motor function of the spinal nervous system. Once there is an injury at this level and due to the instability of the spine by the inability exists in the ligaments damaged, the body alone try to give this missing stability bone formation shaped peak portions ventral vertebral body, in an attempt to prevent further damage that affects the spinal cord [8] is made. Prolotherapy, as mentioned above, directly stimulates proliferation of tissue through the formation of fibroblasts, increasing its strength and stability, causing the rehabilitation of weakened structures or damaged such as ligaments, tendons or joints [6].

It says the owner of the treatment options that exist today, as is prolotherapy and including conservative therapy consisting of use or administration of anti-inflammatory steroid type. However and despite the anti-inflammatory properties of glucocorticoids have been well recognized since the 1960s, current work has not been demonstrated successfully in patients with spinal diseases putting a shadow of doubts about its real utility [9]. The treatment plan of regenerative medicine which consisted of five applications using an irritating solution, a local anesthetic and a vehicle application (50% glucose, saline and lidocaine) is established. Channeled with 0.9% NaCl and sedation protocol was applied in order to immobilize the patient during the procedure, was performed trichotomy and antisepsis ranging from the first thoracic vertebra to the iliac sacrum portion, using a spinal needle 22 gauge proceeded to apply the Remedy in every facet joint the amount of 2 ml per injection (Figure 3, 4). It was applied at the end of each tramadol session at 4 mg per kg avoiding any anti-inflammatory drugs of any kind because these have an adverse effect on the process of inflammation of the tissues [10] and compresses applied local heat with hot water bags in order to increase the flow of solutions subsequent to treatment (Figure 5).



**Figure 3:** Application of prolotherapy injections with disposable spinal needle.



*Figure 4: Application of prolotherapy injections with disposable spinal needle.*



*Figure 5: Application of local heat compresses using hot water bottles.*

From the first application the second session was scheduled 15 days after observing marked improvement, because the dog could move in a better way, he had even slight signs of ataxia hemi lateral but could be incorporated without restrictions. Then a month later was quoted, in which overall patient improvement was observed, so neurological examination was performed again without finding alterations in any phase of the study (Figure 6, 7). The owner it was recommended two sessions with a range of thirty days between sessions to further promote the strengthening of the yellow ligaments.



*Figure 6: The patient performing movements up and climbing stairs is appreciated.*



*Figure 7: The patient performing movements up and climbing stairs is appreciated.*

## Discussion

Cases involving issues of the spine in person difficult and often quite problematic to treat because of the complications that have in the cost-benefit ratio in conventional surgery and other medical therapies [11]. The use of pharmacological therapies using steroidal anti been shown in studies that accelerate degeneration of articular cartilage in osteoarthritis with side effects in the GI tract, liver, heart and kidneys, however interfere with the immune system, thereby decreasing the inflammatory response and pain response to acute and chronic musculoskeletal injuries [12]. The use of prolotherapy in dogs and cats has allowed to be a generous choice due to reports of other authors [11,13,14] which refer positively about their experience in cases which have used in the treatment.

## Conclusion

The use of prolotherapy has shown positive results in patients with chronic degenerative diseases. The results are generally predictable and include mobility and quality of life of the pet along with a reduction and elimination of pain often. However, each animal responds differently. There pathologies acquired and congenital very common that come to fruition in the clinic, which emphasize the discoespondiloatrosis, hip dysplasia and elbow, and other degenerative processes. Thus, the pain that come to experience symptoms patients are high and potentially harmful causing damage in turn in other metabolic systems of the body [14].

## Bibliography

1. Arroyo R. "Prolotherapy and partial rotator cuff tear, another opcionterapeutica: report of a case". *Rehabilitation (Made)* (2007).
2. Alderman D. "Prolotherapy for musculoskeletal pain". *Practical pain management* 7 (2007): 10-5.
3. Kim R, *et al.* "Critical review of prolotherapy for osteoarthritis, low back pain, and other musculoskeletal conditions: a physiatric perspective". *Journal of Physical Medicine and Rehabilitation* 83.5 (2004): 379-389.
4. Reynoso R. "Proloterapia en Medicina Veterinaria". *Memorias cursos* (2003).
5. Scaramal JD and Garibaldi L. "Bases de neurologia clinica en caninos y felinos". *Buenos Aires. Prensa Veterinaria Argentina* (1991): 301.
6. Rodriguez D and Hernandez L. "Uso de proloterapia como tratamiento en perros con discoespondiloartrosis. A proposito de un caso". *Revista Electronica de Veterinaria* 15.1 (2014).
7. Lecouteur A and Grandy J. "Enfermedades de la medula espinal. Tratado de medicina interna veterinaria. Enfermedades del perro y el gato". *5<sup>th</sup> edition Argentina: Inter-Medica* (2002): 677-732.

8. Gomez M., et al. "Herniacion discal intravertebral cervical (Nodulo de Schmorl) en un perro." *Instituto de Anatomía Veterinaria. 2Instituto de Ciencias Clinicas Veterinarias, Universidad Austral de Chile, Casilla 567, Valdivia, Chile Arch med. vet.* 32.1 (2000).
9. Postigo R. "Metilprednisolona en el tratamiento del trauma raquimedular. Analisis de la evidencia". *Revista Medica Clinica Condes* 17.1 (2006): 12-19.
10. Dehaan R. "My experience with prolotherapy in animals: an alternative answer to anterior cruciate ligament and hip dysplasia degeneration". *Journal of Prolotherapy* 1.1 (2009): 54-58.
11. Babette G. "Practical Application of Prolotherapy in Canines: Case Studies". *Journal of Prolotherapy* 1.3 (2009): 179-180.
12. Ochi H. "Effects of long-term administration of carprofenon healing of a tibial osteotomy in dogs". *American Journal of Veterinary Research* 72.5 (2011): 634-641.
13. Roger L. "My Experience with Prolotherapy in Animals an Alternative Answer to Anterior Cruciate Ligament and Hip Dysplasia Degeneration". *Journal of Prolotherapy* 1 (2009): 54-58.
14. Babette G. "A Case for Prolotherapy and Its Place in Veterinary Medicine". *Journal of Prolotherapy* 4 (2012): e870-e885.

**Volume 2 Issue 5 May 2016**

**© All rights reserved by D Rodriguez Velazquez and LF Hernandez Cejudo.**