

## Metabolic Syndrome as a Risk Factor for Idiosyncratic Drug-Induced Autoimmune Hepatitis (DIAIH) Following Nitrofurantoin Exposure

Dana Bielopolski<sup>1</sup>, Yifat Snir<sup>3</sup>, Marius Braun<sup>3,4</sup>, Michal Cohen<sup>3,4</sup>, Hagar Banai<sup>3</sup>, Ana Tobar<sup>2,4</sup>, Amir Shlomai<sup>1,3,4</sup>, Ran Tur-Kaspa<sup>1,3,5</sup> and Assaf Issaschar<sup>1,3</sup>

<sup>1</sup>Departments of Medicine D, Rabin Medical Center-Beilinson Hospital, Petach Tikva

<sup>2</sup>Pathology, Rabin Medical Center-Beilinson Hospital, Petach Tikva

<sup>3</sup>The Liver Institute, Rabin Medical Center-Beilinson Hospital, Petach Tikva

<sup>4</sup>Sackler Faculty of Medicine, Tel Aviv University, Tel Aviv, Israel

<sup>5</sup>Faculty of Medicine Bar-Ilan university, Ramat Gan; Israel

\*Corresponding Author: Dana Bielopolski, Internal Medicine D, Rabin Medical Center, Beilinson Campus, Israel.

Received: November 04, 2020; Published: July 28, 2021

### Abstract

**Background:** Non-alcoholic fatty liver (NAFLD) and metabolic syndrome have been characterized as a risk factors for drug induced liver injury (DILI). Drug-induced autoimmune hepatitis (DIAIH) is a potentially fatal disease, with a wide variety of causative drugs, one of the most common is Nitrofurantoin used for prevention of urinary tract infection. Despite its idiosyncratic pattern of damage, there is no consensus regarding which patients are at increased risk to develop DIAIH following exposure.

**Methods and Results:** Reviewing our institution's medical records between 2000 - 2015 we identified 11 patients who presented with hepatitis following long-term treatment with nitrofurantoin, exhibiting a mixed pattern of elevated liver enzymes. Liver biopsies revealed heavy plasma cells infiltrates and bridging necrosis. Cessation of nitrofurantoin, and administration of steroids normalized liver function tests and reversed symptoms. Prevalence of metabolic syndrome was double then expected among our patients.

**Conclusion:** Nitrofurantoin can cause idiosyncratic DIAIH in patients with metabolic syndrome and should be considered as a risk factor. In the presence of metabolic syndrome or fatty liver, alternative preventive treatment options for urinary tract infection should be sought, otherwise quarterly laboratory follow-up is advised to recognize early and potentially reversible liver damage.

**Keywords:** DILI; Hepatotoxicity; Nitrofurantoin; Fatty Liver

### Abbreviations

AIH: Autoimmune Hepatitis; DIAIH: Drug Induced Autoimmune Hepatitis; DILI: Drug Induced Liver Injury; NAFLD: Nonalcoholic Fatty Liver Disease

### Introduction

Drug Induced Liver Injury (DILI) is an important complication that can occur through use of prescribed medicines, diet supplements or herbal products as alternative medicine. Risk factors of DILI are complex and interrelated; Females [1], the elderly [2] patients with

underlying chronic liver disease [3], obesity and HIV [4] are at greater risk for DILI. Drug characteristics (e.g. medication dose, extent of hepatic metabolism, and drug lipophilicity) also contribute to the DILI risk [5].

Although still controversial, there is accumulating clinical evidence linking nonalcoholic fatty liver disease (NAFLD) with an increased risk or poorer outcome of DILI, independently of other confusing factors. This seems to apply more to certain types of intrinsic DILI (e.g. that are induced by acetaminophen, MTX and volatile anesthetics) than to idiosyncratic DILI, where clinical evidence is even more scarce and circumstantial [6].

Drugs that cause DILI can trigger immune which can lead to a clinical course similar to autoimmune hepatitis (AIH) [7]. Many drugs have been reported to cause this condition, which is named drug-induced AIH (DIAIH) [8-10], Nitrofurantoin being one of the prominent [11-13].

This potentially fatal disease is similar in many aspects to classical autoimmune hepatitis (AIH), with the exception that a drug is identified as the causative agent [14]. Patients developing DIAIH are not different from patients with AIH in terms of histology, serological findings, and treatment response [8], with one fundamental difference - there are no relapses in cases of DIAIH when immunosuppression is discontinued. This stands in sharp contrast to the high relapse rate after withdrawal of immunosuppression in AIH, which in most cases remains a chronic disease [8].

Nitrofurantoin is an antibiotic used in the treatment of recurrent urinary tract infection (UTI) known to cause idiosyncratic hepatotoxicity, where the dose-response curve lies to the right of the lethal dose. However, a sporadically occurring sensitivity factor, such as a fatty liver environment, could shift the dose-response curve for hepatotoxicity to the left, thereby bringing hepatotoxic doses into the therapeutic range [15].

We assembled a series of patients who presented with DIAIH following long-term treatment with nitrofurantoin and in whom an increased prevalence of the Metabolic Syndrome and fatty liver were observed.

## **Methods**

We reviewed Rabin Medical Center liver institute files and hospitalization charts between the years 2000 - 2015 with the help of the institute physicians and identified patients which suffered hepatic injury as a result of prolonged nitrofurantoin exposure.

## **Results**

Reviewing our institution files between the years 2000 - 2015 revealed eleven female patients, mean age 71.5 (range 64 - 84), community residents, and independent in terms of ADL activities, that were evaluated for severe and acute hepatitis.

Their chronic co-morbidities included hypertension (63.6%), diabetes (37%) and dyslipidemia/fatty liver (63.6%). Frequent medications used were mainly anti-hypertensives (See supplementary table 1 for complete description). All patients were treated with nitrofurantoin, 100 mg/day, for urinary tract infection, for periods of 2 months to 3 years before presentation.

Eight patients (72%) presented with symptoms of weight loss, anorexia, shortness of breath, and abdominal discomfort. Ascites and jaundice were prominent findings on physical examination observed in 5 patients. Three patients were asymptomatic and were admitted for evaluation of elevated liver enzyme levels on routine blood test (Table 1).

Patient	(p1)	(p2)	(p3)	(p4)	(p5)	(p6)	(p7)	(p8)	(p9)	(p10)	(p11)
AST u/l	282	1302	848	1177	839	349	364	459	101	103	218
ALT u/l	81	603	545	1150	512	407	905	529	135	82	358
ALP u/l	99	603	148	320	130	355	116	152	101	119	82
Bilirubin	2.71	15.4	14.5	3.87	2.31	4.7	1.91	4.9	0.91	0.8	0.5
Albumin g/dl	3.2	2.4	3	3.5	2.8	3.2	4.4	2.8	3.9	3.5	-
INR	1.71	1.3	1.41	1.25	1.33	1.03	1.06	1.4	1.06	-	-
ANA u/l	1:80	Negative	1:160	Negative	1:32	1:320	1:80	ANA 1:160	Positive	-	1:640
antiSM u/l	Negative	Negative	Negative	-	Positive	-	1:20		Negative	-	Negative
antiLKM u/l	0.7	0.6	0.9	-	0.9	-	-	0.6	-	-	-
IgG Globulin mg/dl	4.2	2.9	5	3.9	6.4	-	-	3.8	3.79	3.1	-

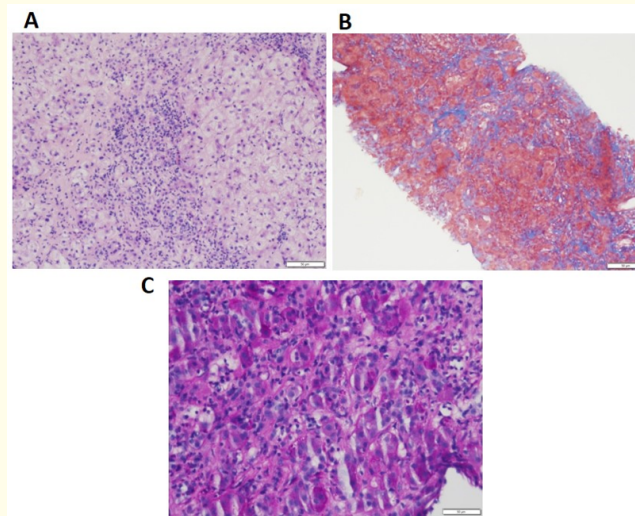
**Table 1:** Laboratory data of patients prior to investigation, correlating the day of admission. (-) parameter was not tested. AST: Aspartate Transaminase, ALT: Alanine Transaminase, ALP: Alkaline Phosphatase, INR: International Normalized Ratio, ANA: Antinuclear Antibody, antiSM: Anti Smooth Muscle, antiLKM: Anti Liver Kidney Antigen.

Upon admission, all patients had a mixed pattern of elevated liver enzymes, both hepatocellular and cholestatic. Aminotransferase levels were 2 to 10 times the upper limit of normal and Bilirubin was elevated. Synthetic liver functions were abnormal in 63% of patients. Eight patients (72%) had elevated anti-nuclear antibody levels, with titers as high as 1:640. Seven patients (63%) had elevated globulin levels (mean 4.1 gr/dl, range 3.8 - 6.4) (Table 2).

Patient	(p1)	(p2)	(p3)	(p4)	(p5)	(p6)	(p7)	(p8)	(p9)	(p10)	(p11)
Nitrofurantoin (dose mg)	100	100	100	100	100	100	100	100	100	100	100
Nitrofurantoin duration (years)	3	2	0.2	0.2	-	1	-	0.5	-	-	-
Steroid dose (mg)	30	30	9 mg (budeson)	20	60	40	-	40	-	-	-
Steroid therapy duration (months)	3	8	-	4	7	2	-	Current			

**Table 2:** Nitrofurantoin therapy prior to investigation and steroid therapy following diagnosis. Prednisone dose was given daily.

All patients underwent ultrasonography. The most prominent abnormality identified, in 37% of patients, was a grainy or fatty liver texture. Liver biopsy, performed in 8 patients (72%), revealed heavy cellular infiltrates in all cases, with 5 patients showing plasma cells and 3 showing bridging necrosis in addition to portal fibrosis (Figure 1). Due to the random nature of biopsies, fatty components were negligible. Detailed description of histology and imaging is available in supplementary table 2.



**Figure 1:** Histopathological sample from a Liver biopsy of patient 5 showing drug induced autoimmune hepatitis (DIAIH). A- H&E staining, X40, showing heavy lymphocyte infiltrate in liver tissue. B- Masson stained liver tissue, X10, showing large area of fibrosis. C- H&E stained liver tissue, X100, exemplifying plasma cell infiltrate.

Cessation of nitrofurantoin was the initial treatment step in all patients, followed in 7 (63%) by administration of steroids (prednisone 0.5 - 1 mg/kg), and in one due to diabetes, budesonide 9 mg. Steroids were used for 2 to 6 months, followed by a slow tapering down. Patients were followed by the Liver Institute until liver function tests normalized, during which time they were clinically asymptomatic.

## Discussion and Conclusion

Pre-existing liver disease seems not to be associated with increased risk of idiosyncratic hepatotoxicity when assessed for the bulk of medications. However, it could pose increased risk of hepatotoxicity when exposed to certain drugs including acetaminophen [16,17] several antibiotics (piperacillin/tazobactam, telithromycin) [18], the antithrombotic agent ticlopidine [19] and the antihypertensive agent losartan [18]. Interaction of a drug with a sporadically occurring inflammatory episode could explain the unpredictable onset of idiosyncratic adverse drug reactions and their apparent lack of relationship to dose [15]. We describe eleven female patients, chronically treated with nitrofurantoin for recurrent UTI, who developed severe hepatic injury after extended exposure to the drug. Severity of damage was assessed either by clinical deterioration, laboratory data, biopsy findings, or a combination of these parameters. In all cases, withholding the offending drug and in some cases adjacent treatment with steroids, reversed the damage as exemplified by laboratory values normalization and clinical improvement.

Bjornsson and colleagues described 24 patients with DIAIH, 11 of them were treated with nitrofurantoin. Their female patients were very similar to the cohort we describe in terms of demographic characteristics, exposure duration, clinical course and recovery. They also

did not witness relapse after steroids withdrawal [8]. DIAIH associated with nitrofurantoin rarely progresses to cirrhosis as hepatitis does not recur upon secession of the stimuli [20].

Another retrospective study observed that 15% of AIH were in fact drug induced, three fourths of cases were attributed either to nitrofurantoin or statins. The authors describe nitrofurantoin induced DIAIH with uniquely prolonged exposure, average latency time as long as one year. Of note, the long latency did not affect clinical outcome [21].

The degree of elevation in liver enzymes has poor correlation with severity of liver disease. Instead, the pattern of liver disease indicates near term and long-term consequences. The cholestatic pattern of hepatitis has the lowest mortality but may lengthen time for normalization of liver tests. Additionally, cholestatic and mixed hepatitis pattern have a small but definite risk of evolution to chronicity [22]. We were struck by the high prevalence of fatty liver, evidenced by radiological documentation, and metabolic syndrome components in our cohort. This finding could account, at least in part, to the susceptibility of our patients to adverse reaction of medication.

In patients with obesity, diabetes, insulin resistance, and nonalcoholic steatohepatitis, the metabolic environment characterized by reduced ATP synthesis and higher ROS levels can increase cytotoxicity [23,24]. These chronic conditions and illnesses predispose drug associated induction of cellular oxidative stress [25]: obesity, insulin resistance, and NAFLD increase cellular oxidants [26], fatty liver increases lipid peroxidation and [27] obesity, insulin resistance, and NAFLD are related to cellular antioxidation [28]. NAFLD and its main associated comorbidity, obesity, may be intertwined with drug - there is increasing awareness of potential DILI risk factors in NAFLD patients for a growing number of drugs [18,28]. In the context of obesity and related metabolic diseases, NAFLD could serve as a background for acute hepatitis, following drug exposure, where the combination increase formation of toxic metabolites [29]. For example, acetaminophen overdose could cause acute liver injury in patients with NAFLD more often than in non NAFLD patients [16].

In conclusion, our patients exhibit double the prevalence rate expected, implying a circumstantial connection between the two. Past series did not relate to this medical condition, and a possible relationship is yet to be elucidated. NAFLD is the most common cause of liver disease worldwide with prevalence increasing in parallel with that of obesity and diabetes [30]. Exposing patients with NAFLD or metabolic syndrome to long term nitrofurantoin treatment could cause acute hepatitis, similar to AIH, related to increased formation of toxic metabolites [29]. However, unlike AIH, drug cessation and in some cases a course of steroids treatment resulted in complete resolution with no clinical or laboratory relapses.

**Future Perspective**

Clinicians should be aware that DIAIH can occur in an idiosyncratic manner and avoid missing a diagnosis with catastrophic consequences [22]. A clinical background of metabolic syndrome in general and NAFLD in particular should be considered as a risk factor for nitrofurantoin induced AIH. Susceptible patients must undergo basic screening prior to treatment, including liver sonography and a blood test for liver enzymes. In those with fatty liver, alternative preventive treatment options must be sought. In the absence of reasonable alternatives, quarterly laboratory follow-up is advised to prevent potentially catastrophic liver damage.

**Financial Support**

No financial support was received in the preparation of this manuscript.

**Patients’ co-morbidities (supplementary table 1)**

P1	P2	P3	P4	P5	P6	P7	P8	P9	P10	P11
Hypertension, hyperlipidemia, diaphragmatic hernia, s/p cholecystectomy, OA	Hypothyroidism, hyperlipidemia	Diabetes, osteoporosis, pacemaker, fatty liver, obesity, dyslipidemia	Fatty liver, hypertension, dyslipidemia, GERD, s/p cholecystectomy	Hypertension, dyslipidemia, diabetes	Epilepsy	Hypertension, dyspepsia, IFG	Hypertension, diabetes, dyslipidemia, IHD, osteoporosis, fatty liver	Reflux, CHF	Hypertension, OA, bilateral varicose veins, dilated thoracic aorta, hypothyroidism, s/p IDC, cholelithiasis	Hypertension, dyslipidemia, hypothyroidism

**Patients’ symptoms (supplementary table 1)**

P1	P2	P3	P4	P5	P6	P7	P8	P9	P10	P11
Ascites, pleural effusion, weight loss	Weakness, malaise, jaundice, ascites	Weakness, jaundice, anorexia, confusion	Routine checkup	Weight loss, anorexia,	Weight loss, hepatitis, hepatic encephalopathy, jaundice	Nausea, metallic taste, reflux	Anorexia, weight loss, jaundice	Cough, metallic taste, weight loss	Routine follow-up	Asymptomatic

Patients' medications (supplementary table 1)

P1	P2	P3	P4	P5	P6	P7	P8	P9	P10	P11
Spiro-lactone, amlodipin, zuclopenthixol, dekinet, amitryptiline, folic acid, omeprazole, simvastatin, tramadex, tribemin	Atorvastatin, eltroxin, zopiclone, omeprazole, ursolit, tribemin	Calcium vitamin d, escitalopram, amlodipine, valsartan alendronate, lansoprazole, pregabalin, metformin, micropirin, repaglinide, simvastatin	Calcium, esto, atenolol, amlodipine, omeprazole, ramipril, simvastatin	Alendronate, calcium carbonate, tolterodine tartrate, metformine	Topiramate, carbamazepine, clobazam, caltrate, eladronate	Micropirin, lansoprazole, vitamin B12	Metformine, micropirin, isosorbide mononitrate, atenolol, losartan	Fusid, micropirin, esomeprazole	Silazapril, elandronate, vitacal+d, micropirin, mebeverine hydrochloride, atenololo, eltroxin, simvastatin	Eltroxin, bisoprolol, micropirin, candesartan

Supplementary Table 1

Patients' imaging (supplementary table 2)

P1	P2	P3	P4	P5	P6	P7	P8	P9	P10	P11
US-liver size normal, lobular borders, grainy texture	US - liver not enlarged, grainy texture, 1.3 cm cyst in the rt. Lobe and a hypoechoic area 1/7 cm to be further evaluated by three phase CT	US - liver size normal, fatty texture, bile ducts not distended, pancreas size and echogenicity normal, spleen not enlarged, homogenous, kidneys normal size, echogenicity and parenchyma, no hydro-nephrosis, no ascites	US - normal including flows	US - Liver and flows normal, bilateral hydro-nephrosis	US - Liver size normal, CBD diameter 1 cm with slight widening of the central intra-liver viles	US- liver and bile ducts normal, fatty liver	US-shrunk-en gall-bladder containing stones, bile ducts not distended but suspicion of sediment in choledocus, pancreas normal, liver size normal, homogenous texture, thickened an-trum/pylorus	CT-bronchiec-tasis with interstitial opacities in lung bases	US- hyperechoic process in left lower lobe likely heman-gioma, gall-bladder not thickened with small stones, bile ducts not distended	US-liver size normal, slightly fatty texture, several cysts to 0/6 cm, spleen normal, bile ducts not distended



**Patients' histology – supplementary table 2**

P1	P2	P3	P4	P5	P6	P7	P8	P9	P10	P11
Fibrosis with plasma cell infiltrate	Severe hepatitis with areas of panlobular necrosis	Not performed	Extended hepatitis, majority of plasma cells, fibrosis	Heavy infiltrates, with fibrotic component, bridging necrosis	Findings compatible with cholestatic hepatitis, plasma cell infiltrates, and bridging necrosis	Not performed	Portal edema and fibrosis with septal formation, moderate activity including plasma cells and mild bile duct damage	Chronic hepatitis, moderate activity including plasma cells, with portal fibrosis	Not performed	Portal and mild lobular hepatitis with portal fibrosis

**Bibliography**

1. Björnsson ES., *et al.* "Incidence, presentation, and outcomes in patients with drug-induced liver injury in the general population of Iceland". *Gastroenterology* 144.7 (2013): 1419-1425, 1425.e1.
2. Abboud G and Kaplowitz N. "Drug-induced liver injury". *Drug Safety* 30.4 (2007): 277-294.
3. "Gather and weigh the evidence when judging whether a drug has induced liver injury". *Drugs and Therapy Perspectives* 23.11 (2007): 23-26.
4. Leise MD., *et al.* "Drug-induced liver injury". *Mayo Clinic Proceedings* 89.1 (2014): 95-106.
5. Edoute Y., *et al.* "Fatal liver necrosis associated with the use of nitrofurantoin". *Israel Medical Association Journal* 3.5 (2001): 382-383.
6. Bessone F., *et al.* "Review article: drug-induced liver injury in the context of nonalcoholic fatty liver disease - a physiopathological and clinical integrated view". *Alimentary Pharmacology and Therapeutics* 48.9 (2018): 892-913.
7. Liu Z-X and Kaplowitz N. "Immune-mediated drug-induced liver disease". *Clinical Liver Disease* 6.3 (2002): 755-774.
8. Björnsson E., *et al.* "Drug-induced autoimmune hepatitis: clinical characteristics and prognosis". *Hepatology* 51.6 (2010): 2040-2048.
9. Germano V., *et al.* "Autoimmune hepatitis associated with infliximab in a patient with psoriatic arthritis". *Annals of the Rheumatic Diseases* 64.10 (2005): 1519-1520.
10. Pelli N and Setti M. "Atorvastatin as a trigger of autoimmune hepatitis". *Journal of Hepatology* 40.4 (2004): 716.
11. Smyk DS., *et al.* "Urinary tract infection as a risk factor for autoimmune liver disease: from bench to bedside". *Clinics and Research in Hepatology and Gastroenterology* 36.2 (2012): 110-121.
12. Amit G., *et al.* "Nitrofurantoin-induced chronic active hepatitis". *Israel Medical Association Journal* 4.3 (2002): 184-186.
13. Stricker BH., *et al.* "Hepatic injury associated with the use of nitrofurans: a clinicopathological study of 52 reported cases". *Hepatology* 8.3 (1988): 599-606.
14. Navarro VJ and Senior JR. "Drug-related hepatotoxicity". *New England Journal of Medicine* 354.7 (2006): 731-739.
15. Roth RA and Ganey PE. "Intrinsic versus idiosyncratic drug-induced hepatotoxicity--two villains or one?" *Journal of Pharmacology and Experimental Therapeutics* 332.3 (2010): 692-697.
16. Michaut A., *et al.* "Acetaminophen-induced liver injury in obesity and nonalcoholic fatty liver disease". *Liver International* 34.7 (2014): e171-e179.

17. Nguyen GC., *et al.* "Hepatitis C is a predictor of acute liver injury among hospitalizations for acetaminophen overdose in the United States: a nationwide analysis". *Hepatology* 48.4 (2008): 1336-1341.
18. Tarantino G., *et al.* "A prospective study of acute drug-induced liver injury in patients suffering from non-alcoholic fatty liver disease". *Hepatology Research* 37.6 (2007): 410-415.
19. Martínez Pérez-Balsa A., *et al.* "Hepatotoxicity due to ticlopidine". *Annals of Pharmacotherapy* 32.11 (1998): 1250-1251.
20. Suzuki A., *et al.* "The use of liver biopsy evaluation in discrimination of idiopathic autoimmune hepatitis versus drug-induced liver injury". *Hepatology* 54.3 (2011): 931-939.
21. Yeong TT., *et al.* "Natural history and outcomes in drug-induced autoimmune hepatitis". *Hepatology Research* 46.3 (2016): E79-E88.
22. Verma S and Kaplowitz N. "Diagnosis, management and prevention of drug-induced liver injury". *Gut* 58.11 (2009): 1555-1564.
23. Begrich K., *et al.* "Mitochondrial adaptations and dysfunctions in nonalcoholic fatty liver disease". *Hepatology* 58.4 (2013): 1497-1507.
24. Koliaki C and Roden M. "Hepatic energy metabolism in human diabetes mellitus, obesity and non-alcoholic fatty liver disease". *Molecular and Cellular Endocrinology* 379.1-2 (2013): 35-42.
25. Han D., *et al.* "Signal transduction pathways involved in drug-induced liver injury". *Handbook of Experimental Pharmacology* 196 (2010): 267-310.
26. Krauskopf J., *et al.* "Application of high-throughput sequencing to circulating microRNAs reveals novel biomarkers for drug-induced liver injury". *Toxicological Sciences* 143.2 (2015): 268-276.
27. Hunt CM., *et al.* "Drug rechallenge following drug-induced liver injury". *Hepatology* 66.2 (2017): 646-654.
28. Massart J., *et al.* "Role of nonalcoholic fatty liver disease as risk factor for drug-induced hepatotoxicity". *Journal of Clinical and Translational Research* 3.1 (2017): 212-232.
29. Fromenty B. "Drug-induced liver injury in obesity". *Journal of Hepatology* 58.4 (2013): 824-826.
30. Rinella ME. "Nonalcoholic fatty liver disease: a systematic review". *Journal of the American Medical Association* 313.22 (2015): 2263-2273.

**Volume 9 Issue 8 August 2021**

**©All rights reserved by Dana Bielopolski., *et al.***