

The Possible Protective Effects of Carvedilol and Alpha Lipoic Acid Addition to Risedronate on Experimental Model of Glucocorticoid Induced Osteoporosis in Rats

Monira A Selim*, Samia H Abou El-Seoud, Ahmed I Yassin and Amany A Abdin

Pharmacology Department, Faculty of Medicine, Tanta University, Egypt

*Corresponding Author: Monira A Selim, Assistant Lecturer of Pharmacology, Pharmacology Department, Faculty of Medicine, Tanta University, Egypt.

Received: August 01, 2018; Published: August 27, 2018

Abstract

Background: Even though glucocorticoids are used in treatment of many diseases, yet they have many side effects such as osteoporosis. This study was designed to investigate effects of carvedilol and alpha lipoic acid comparable to risedronate on glucocorticoid induced osteoporosis.

Methodology: 56 male Wistar rats were divided into seven equal groups: Group 1: normal control, group 2: received methylprednisolone (MP) served as untreated osteoporosis-induced group, group 3: Osteoporosis-induced rats treated by risedronate, group 4: Osteoporosis - induced rats treated by carvedilol, group 5: Osteoporosis - induced rats treated by alpha lipoic acid (ALA), group 6: Osteoporosis - induced rats treated by risedronate and carvedilol, group 7: Osteoporosis - induced rats treated by risedronate and ALA. Serum osteocalcin (bone formation marker), calcium, malondialdehyde (MDA) and blood reduced glutathione (GSH) were measured. Bone osteopontin (bone destruction marker) was detected by immunohistochemistry and histopathological bone examination was done.

Conclusions: Treatment of MP-induced osteoporosis by addition of either carvedilol or ALA to risedronate was compared to untreated osteoporosis-induced group or to monotherapy by either risedronate or carvedilol or ALA, showed significant improvement of parameters indicating increased bone formation and decreased bone destruction, better antioxidant effect, amelioration of oxidative stress represented by significant increase in levels of serum osteocalcin, calcium, level of blood GSH, decrease in serum MDA, bone osteopontin and better improvement in histopathological examination of bone. In conclusion, Addition of carvedilol or ALA to risedronate is superior to monotherapy by either risedronate or carvedilol or ALA in prevention of glucocorticoid induced osteoporosis.

Keywords: Alpha Lipoic Acid; Carvedilol; Methylprednisolone; Osteoporosis; Risedronate

Abbreviations

MP: Methylprednisolone; ALA: Alpha Lipoic Acid; MDA: Malondialdehyde; GSH: Blood Reduced Glutathione; GIO: Glucocorticoid Induced Osteoporosis; CMC: Carboxy Methyl Cellulose; TBA: Thiobarbituric Acid

Introduction

This experiment was designed to study possible protective effects of carvedilol, ALA and risedronate on glucocorticoid - induced osteoporosis in rat model either monotherapy or in combination. Osteoporosis has significant consequences on public health and economic growth of a nation [1]. It is a chronic metabolic disease characterized by bone loss, microstructure damage and fracture tendency [2]. Osteoporosis can happen idiopathic or secondary to other disease such as rheumatoid arthritis, malabsorption and medications as long-

term administration of glucocorticoids [3]. Glucocorticoid induced osteoporosis (GIO) is the third most common type of osteoporosis, preceded by postmenopausal and senile osteoporosis [4].

Normal bone remodeling is organized through bone formation by osteoblasts that produce organic bone matrix, and bone resorption by osteoclasts that dissolve bone mineral and extracellular matrix [5]. Synthesis of bone matrix by osteoblasts occurs in two main steps: First, osteoblasts secrete collagen proteins, mainly type I collagen and non-collagen proteins as osteocalcin followed by mineralization of bone matrix by calcium, phosphorus and magnesium [6]. This process requires adequate vitamin D [7]. Osteocalcin is the most abundant non-collagenous matrix protein in bone which is produced by osteoblasts during bone formation [8]. The predominant effect of glucocorticoids on bone is impairment in bone formation by direct effect through decreasing bone osteocalcin [9]. Osteopontin (OPN) is one of the major non-collagen proteins which is present in extracellular bone matrix, it plays a role in bone resorption [10]. Osteoporosis occurs when there is imbalance between bone formation and resorption [11].

Risedronate is used as an effective medical treatment for osteoporosis. It is a nitrogen containing bisphosphonate which is deposited on the surface of bone inhibiting bone resorption [12].

Carvedilol is a non-selective β -blocker that block β_1 , β_2 receptors with α_1 blocking and vasodilator activity. It has antioxidant effects due to inhibition of free-radical formation [13]. Bones are innervated by sympathetic neurons, noradrenaline promotes bone resorption via β_2 -adrenergic receptors, it also affects bone formation by inhibiting osteoblast proliferation [14]. β -blockers use is associated with decrease fracture risk and suppression of bone resorption [15].

Alpha Lipoic Acid (ALA) is an antioxidant in both its oxidized and reduced forms [16]. The efficiency of ALA has been shown in diabetic neuropathy, atherosclerosis, hypertension and multiple sclerosis [17].

Materials and Methods

Drugs and chemicals

Methylprednisolone (Solu-Medrol) white powder vial (500 mg) from Pharmacia: dissolved in saline to a final concentration of 4.2 mg/ml. Risedronate (Actonel) tablets (35 mg/tablet) from Aventi dissolved in saline to a final concentration of 7.5 μ g/ml. Carvedilol (Carvid) tablets (6.25 mg/tablet) from Kahira multi ph., prepared as a suspension in aqueous 1% Carboxy methyl cellulose (CMC) vehicle to a final concentration of 0.9 mg/ml. Alpha lipoic acid (Thiotacid) ampule (30 mg/ml) from EVA pharma used as a concentration of 30 mg/ml. Carboxy methyl cellulose (CMC) (1%) powder product of Eastern fine chemicals company, India used as suspension for carvedilol. Normal saline from national pharmaceutical solution laboratories, used as solvent for methylprednisolone, risedronate and alpha lipoic acid. Other chemicals used in this experiment were of analytical grade.

Animals groups, treatment protocol and samples collection

This study was carried out on 56 male Wistar rats (6 - 8 weeks old) weighing 150 - 200g. Animals were housed in wire mesh cages and were fed standard rat chew *ad libitum* and allowed free access to water and allowed 2 weeks for acclimatization and then divided randomly into 7 equal groups: Group I: received 1% CMC as a vehicle daily po for 4 weeks. Group II: received methylprednisolone (MP) 7 mg/kg sc three times a week and matched volume of 1% CMC po daily, served as untreated osteoporosis -induced group. Group III: Osteoporosis - induced rats treated by risedronate 5 μ g/Kg sc three times a week. Group IV: Osteoporosis - induced rats treated by carvedilol 3 mg/Kg po daily. Group V: Osteoporosis - induced rats treated by alpha lipoic acid (ALA) 100 mg/kg daily ip. Group VI: Osteoporosis - induced rats treated by risedronate and carvedilol in the same dosage regimen. Group VII: Osteoporosis - induced rats treated by risedronate and alpha lipoic acid (ALA) in the same dosage regimen. The treatment with risedronate, carvedilol and ALA was started concomitantly with administration of methylprednisolone and continued for 4 weeks.

At the end of the experiment (after 4 weeks) rats were sacrificed, they were anaesthetized by diethyl ether and blood was collected immediately by cardiac puncture, a volume was processed with heparin to obtain whole blood where erythrocytes were lysed in 4 times its volume of ice cold distilled water, centrifuged at 5,000 rpm for 10 minutes at 4°C. The supernatant, erythrocyte lysate was collected and used for assay of reduced glutathione (GSH) immediately. The remaining volume was processed to obtain serum samples where blood was allowed to clot for 30 minutes and then, centrifuged at 5,000 rpm for 10 minutes at 4°C. Serum was freezed at -80°C and used later for assay of osteocalcin, calcium and malondialdehyde (MDA). Bone samples from rat femurs were collected and processed for preparation of decalcified specimens for staining by Hematoxylin and Eosin (H and E) stain for histopathological examination and for immunohistochemical detection of osteopontin.

This experiment was carried out according to guidelines of our institutional "Research Ethics Committee" (REC), with an approval code (30355/06/15).

Enzyme-linked immunosorbent assay (ELISA) of serum osteocalcin levels

Serum levels of osteocalcin were measured by sandwich ELISA kit, obtained from Bio-gene Company, Germany (Catalogue No. 201-11-0271) following the manufacturer protocol. Using a 96-well microtiter plate reader. The optical density (OD) was measured by detecting the color change at 450 nm wavelength. The concentration of osteocalcin in the sample is determined by comparing OD of the sample to the standard curve. The results were expressed as ng/ml.

Measurement of serum calcium levels

Serum calcium levels were measured spectrophotometrically according to method described by Connerty and Briggs [18], using kit supplied by Spinreact, Spain, based on formation of color complex between calcium and 0-cresolphatalein in alkaline medium. The intensity of the color formed in the sample is estimated at 570 nm wave length. The results were calculated according to the following equation,

$$\text{Serum calcium (mg/dl)} = \frac{(A)\text{sample}-(A)\text{blank}}{(A)\text{standard}-(A)\text{blank}} \times 10$$

Measurement of serum MDA levels

Serum MDA levels were measured spectrophotometrically according to method described by Ohkawa., *et al.* [19], using kits supplied by Biodiagnostic, Germany. based on the fact that thiobarbituric acid (TBA) reacts with MDA in acidic medium to form thiobarbituric acid reactive product. The absorbance of the resultant pink product is measured at 534 nm. The results were calculated according to the following equation,

$$\text{Serum MDA (n mol/ml)} = \frac{(A)\text{sample}}{(A)\text{standard}} \times 10$$

Measurement of GSH levels in blood

GSH levels in blood were measured spectrophotometrically according to method described by Beutler., *et al.* [20], using kits supplied by Biodiagnostic, Germany. Based on the reduction of 5,5' dithiobis (2 - nitrobenzoic acid) (DTNB) with glutathione (GSH) to produce a yellow compound. The reduced chromogen directly proportional to GSH concentration and its absorbance can be measured at 405 nm. The results were calculated according to the following equation, Blood GSH (mg/dl) (= A Sample X 66.66.

Immunohistochemical detection of bone osteopontin

Bone sections were deparafinized and rehydrated, Slides were incubated in hydrogen peroxidase for 10 - 15 minutes to reduce non-specific background staining due to endogenous peroxidase, Washed 2 times in buffer.Ultra V block was applied and incubated for 5 minutes at room temperature to block non-specific background staining. Primary antibody polyclonal IgG antibody (Thermo scientific lab vision,

Cat NO. RB-9097-R7) was applied and incubated according to manufacturer protocol. Biotinylated goat anti-polyvalent was applied and incubated 10 minutes at room temperature, then streptavidin peroxidase was applied and incubated for 10 minutes at room temperature. Staining was visualized by reaction with diaminobenzidine tetrahydrochloride (DAB) and counterstaining with haematoxylin. Sections were analysed under an optic microscope (DP73; Olympus).

Statistical analysis

Statistical analysis of the obtained values was performed using Statistical Program for Social Sciences (SPSS), version 14.0 for windows. After testing for normality of distribution, the parametric data were analyzed using One Way ANOVA test (F value) to detect difference among more than two arithmetic means, followed by post-Hoc Scheffe test to detect the difference between each two means. Values were expressed as mean \pm SD. The non-parametric data were analyzed using Kruskal-Wallis test followed by Mann-Whitney test to detect difference between each two groups in which values were expressed as median (IQR). Linear (Pearson) correlation coefficient was used for parametric data and Spearman correlation coefficient was used for non-parametric data. The difference was considered significant at values of $P < 0.05$.

Results and Discussion

Methylprednisolone (MP) administrated group was compared to group I (normal control group), showed significant decrease in levels of serum osteocalcin, calcium, level of blood reduced glutathione (GSH), in addition to significant increase of serum malondialdehyde (MDA) level as shown in table 1, figure 1 and figure 2 and significant increase of bone osteopontin as shown in figure 3 and figure 4. Histopathological examination of rat femur showed apparent thinning of outer cortical bones, erosion cavities were detected at endosteal surfaces of cortical bone and inner cancellous bone, trabeculae lost their normal architecture which appeared as discontinuous bony ossicles separated by wide bone marrow spaces as shown in figure 5.

When treated group of MP induced osteoporosis with risedronate was compared to group II (untreated osteoporosis -induced group), it showed non-significant difference in level of serum osteocalcin, MDA, level of blood reduced glutathione (GSH), significant increase in serum calcium level as shown in table 1, figure 1 and figure 2 and significant decrease of bone osteopontin as shown in figure 3 and figure 4. Histopathological examination of rat femur showed mild to moderate increase of outer cortical bone thickness, thickness of inner cancellous bone and decrease of erosion as shown in figure 5.

When treated group of MP-induced osteoporosis with carvedilol was compared to group II (untreated osteoporosis - induced group), it showed significant increase in levels of serum osteocalcin, calcium, level of blood reduced glutathione (GSH), significant decrease in serum MDA as shown in table 1, figure 1 and figure 2 and significant decrease of bone osteopontin as shown in figure 3 and figure 4. Histopathological examination of rat femur showed mild increase of the thickness of cortical and trabecular bone as shown in figure 5.

When treated group of MP-induced osteoporosis with ALA was compared to group II (untreated osteoporosis-induced group), it showed significant increase in levels of serum osteocalcin, calcium, level of blood reduced glutathione (GSH), significant decrease in serum MDA as shown in table 1, figure 1 and figure 2 and significant decrease of bone osteopontin as shown in figure 3 and figure 4. Histopathological examination of rat femur showed mild increase of the thickness of cortical and trabecular bone as shown in figure 5.

When treated groups of MP-induced osteoporosis by addition of either carvedilol or ALA to risedronate were compared to untreated osteoporosis - induced group or to group receiving monotherapy by either risedronate or carvedilol or ALA, they showed significant increase in levels of serum osteocalcin, calcium, level of blood GSH, decrease in serum MDA, bone osteopontin as shown in table 1 and figure 1-4. Histopathological examination of rat femur showed preserved cortical bone thickness and absence of erosion cavities, normal architecture of bone trabeculae and trabecular bone thickness were maintained as shown in figure 5.

Drugs for osteoporosis are mostly anticatabolic agents which decrease bone resorption. But they have minimal effect on bone mineralization, hence cannot reverse osteoporosis. Discovery of a drug that stimulates bone formation, when used alone or synergistically with drugs that inhibit resorption would represent a paradigm shift in managing osteoporosis [15].

Introducing new agents that could modify underlying pathologic pathways that play a role in the pathogenesis of osteoporosis is really critical.

GIO is one of the most common side effects of glucocorticoids, increasing risk of fractures and disability to many patients [21].

In the present work, subcutaneous administration of methylprednisolone (MP) in a dose of 7 mg/kg administered three times a week for 4 weeks induced osteoporosis manifested as significant decrease of serum osteocalcin level as a regeneration marker, serum calcium level and associated with an oxidative stress with significant decrease in level of blood GSH, significant increase of serum MDA level and immunohistochemical expression of bone osteopontin as a resorption marker compared to normal control group that was confirmed by osteoporotic changes found in histopathological examination. Such dose was used in many studies in animals as in the work of Valenti MT, *et al.* and Folwarczna J., *et al.* [22,23] who used MP at a dose of 7 mg/kg, subcutaneous daily for 4 weeks to induce osteoporosis in rats. Matched doses in human induce osteoporosis when used for long time as seen in the study of Kikuchi Y, *et al.* [24], who reported that high-dose prednisolone therapy (more than 30 mg/day) for more than 2 years caused osteoporosis in patients in their hospital. The dose used in the current study (7 mg/kg) is equivalent to human dose of 80 mg that is 1.5 times the maximum prescribed dose for humans (60 mg daily).

In accordance with that study the works of Toumi H, *et al.* [25], who reported that GCs decrease serum osteocalcin level, Zhang J., *et al.* and Chen Z., *et al.* [26,27] showed that glucocorticoid injection lead to bone deleterious effects by decreasing bone formation confirmed by decreased serum level of osteocalcin, histomorphological staining confirm that GCs lead to increased separation of trabecular bone network. Also, Banji D, *et al.* [28] who reported that GCs down regulated levels of serum calcium through decreasing intestinal absorption and renal reabsorption of calcium, leading to marked bone deteriorations of trabecular bone shown by H and E staining.

Moreover, the work of Zhang S., *et al.* [29] reported that GCs administration is associated with increased serum level of lipid peroxidation products, decreased antioxidant capacity which indicate the role of oxidative stress in osteoporosis.

Bisphosphonates as risedronate that are currently used in treatment of osteoporosis increase bone mineral density by decreasing bone resorption, but unfortunately, they have no evident effect on bone formation and restoration [25].

Treatment of MP-induced osteoporosis with risedronate showed non-significant difference of serum osteocalcin, serum MDA, level of blood GSH, significant increase in serum calcium level, significant decrease of immunohistochemical expression of bone osteopontin compared to untreated osteoporosis-induced group. Histopathological examination of rat femur showed mild to moderate increase in outer cortical bone thickness and thickness of inner cancellous bone and decreased erosion cavities. In accordance with the results of this study, the work of Kikuchi Y, *et al.* [24], who reported that risedronate inhibits bone loss in GIO, this also agrees with Elshal MF, *et al.* [30], who showed that bisphosphonates augmented serum calcium which was supported with enhanced histological structure of rat femur. Also, Banji D, *et al.* [28] reported that risedronate increased serum calcium level which was previously lowered after GCs administration. Moreover, Yao W, *et al.* [31] reported that risedronate reduced expression of mineralization inhibitor osteopontin and reduced surface remodeling.

Although risedronate provides anticatabolic effect on bone and decreases its resorption by decreasing osteopontin, but unfortunately it has no effect on oxidative stress and regenerative capacity of bone by osteocalcin, denoting that it has a replacement role rather than acting as a modulating agent.

Carvedilol increases bone growth by inactivation of osteoclasts [32]. Production of reactive oxygen species (ROS) has an important role in bone resorption that occur via destruction of matrix proteins [33]. β_2 adrenergic receptors are expressed in bone and mediate bone catabolism, GCs may increase the expression and signaling activity of β_2 adrenergic receptors in osteoblasts thus increasing the response of these cells to the bone catabolic effect of sympathetic neurons [34].

Treatment of MP-induced osteoporosis with carvedilol showed significant improvement in all pathophysiologic aspects of our model compared to untreated osteoporosis - induced group as shown in table 1 and figure 1-4. Histopathological examination of rat femur showed mild increase of thickness of cortical and trabecular bone as shown in figure 5. These results are in agreement with the works of Liu D., *et al.* and Araujo Junior R., *et al.* [32,35], who reported that carvedilol promotes bone growth by decreasing bone loss and decreasing elevated MDA and increased GSH as antioxidant parameter. In contrast, Sliwinski L., *et al.* [36] reported that β -2 agonist fenoterol administered to rats decreasing trabeculae width resulting from decreased cancellous bone formation.

In our research for osteoporosis modifying drugs, alpha lipoic acid (ALA) was a suitable candidate to be investigated. Recently, ALA has received substantial attention because it reduces oxidative stress by acting as a free radical scavenger preventing membrane lipid peroxidation [37].

Looking to the results of treatment of MP-induced osteoporosis with ALA showed significant improvement in all pathophysiologic aspects of our model compared to untreated osteoporosis -induced group as shown in table 1 and figure 1-4. Histopathological examination of rat femur showed mild increase of thickness of cortical and trabecular bone as shown in figure 5. In agreement with these results the work of Lu S., *et al.* [38], who reported that ALA decrease serum MDA and increase blood GSH which promotes bone formation in GIO proved by increasing serum osteocalcin.

To our knowledge, this work is the first to investigate protective effects of combined risedronate and ALA on GIO and to compare these effects with combination of risedronate and carvedilol.

Combination therapy of MP-induced osteoporosis by addition of either carvedilol or ALA to risedronate was compared to untreated osteoporosis-induced group as well as to monotherapy by either risedronate or carvedilol or ALA. This particular part of the study showed remarkably improved indices of increased bone formation and decreased bone destruction, better antioxidant effect, improvement of oxidative stress represented in table 1 and figure 1-4. Histopathological examination of rat femur showed preserved cortical bone thickness and absence of erosion cavities, normal architecture of bone trabeculae and trabecular bone thickness were maintained as shown in figure 5.

Parameters Normal control (n = 8)		Groups						
		MP (n = 8)	MP + Ris (n = 8)	MP + Carv (n = 8)	MP + ALA (n = 8)	MP + Ris + Carv (n = 8)	MP + Ris + ALA (n = 8)	MP + Ris + ALA (n = 8)
Serum osteocalcin (ng/ml)	Mean \pm SD	5.29 \pm 0.14	0.65 \pm 0.27	0.92 \pm 0.33	2.01 \pm 0.21	1.87 \pm 0.30	2.52 \pm 0.28	2.43 \pm 0.21
	F value (p value)	146.593 P < 0.001						
	Scheffe test		P1 < 0.001	P 2 NS	P2 < 0.001 P3 < 0.001	P2 < 0.001 P3 < 0.001 P4 NS	P2 < 0.001 P3 < 0.001 P4 NS P5 NS	P2 < 0.001 P3 < 0.001 P4 NS P5 NS P6 NS
Serum Ca (mg/dl)	Mean \pm SD	9.69 \pm 0.17	7.35 \pm 0.19	8.18 \pm 0.08	8.17 \pm 0.08	8.40 \pm 0.28	8.52 \pm 0.28	8.17 \pm 0.08
	F value (p value)	123.956 P < 0.001						
	Scheffe test		P1 < 0.001	P2 < 0.001	P2 < 0.001 P3 NS	P2 < 0.001 P3 > 0.05 P4 NS	P2 < 0.001 P3 NS P4 NS P5 NS	P2 < 0.001 P3 NS P4 NS P5 NS P6 NS

Table 1: Levels of serum osteocalcin, serum calcium.

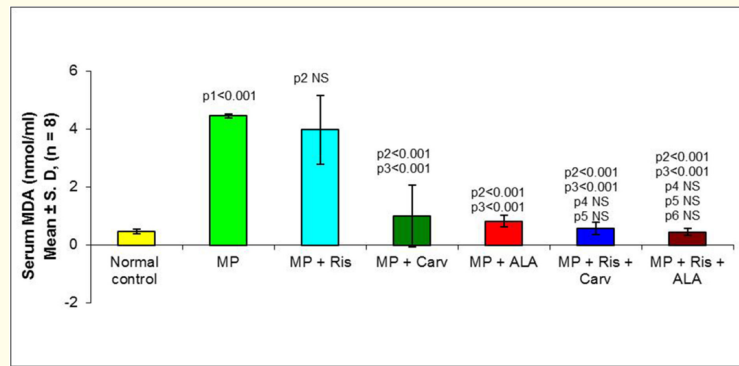


Figure 1: Serum MDA levels (nmol/ml) in different studied groups.

-Values are expressed as mean ± SD, n: Number, NS: Non-Significant

-Scheffe test

- P1: Comparison of group II (MP) Vs group I (normal control)
- P2: Comparison of group III (MP + Ris), IV (MP + Carv), V (MP + ALA), VI (MP + Ris + Carv), VII (MP + Ris + ALA) Vs group II (MP)
- P3: Comparison of group IV (MP + Carv), V (MP + ALA), VI (MP + Ris + Carv), VII (MP + Ris + ALA) Vs group III (MP + Ris)
- P4: Comparison of group V (MP + ALA), VI (MP + Ris + Carv), VII (MP + Ris + ALA) Vs group IV (MP + Carv)
- P5: Comparison of group VI (MP + Ris + Carv), VII (MP + Ris + ALA) Vs group V (MP + ALA)
- P6: Comparison of group VII (MP + Ris + ALA) Vs group VI (MP + Ris + Carv).

MP: Methyl Prednisolone; Ris: Risedronate; Carv: Carvedilol; ALA: Alpha Lipoic Acid.

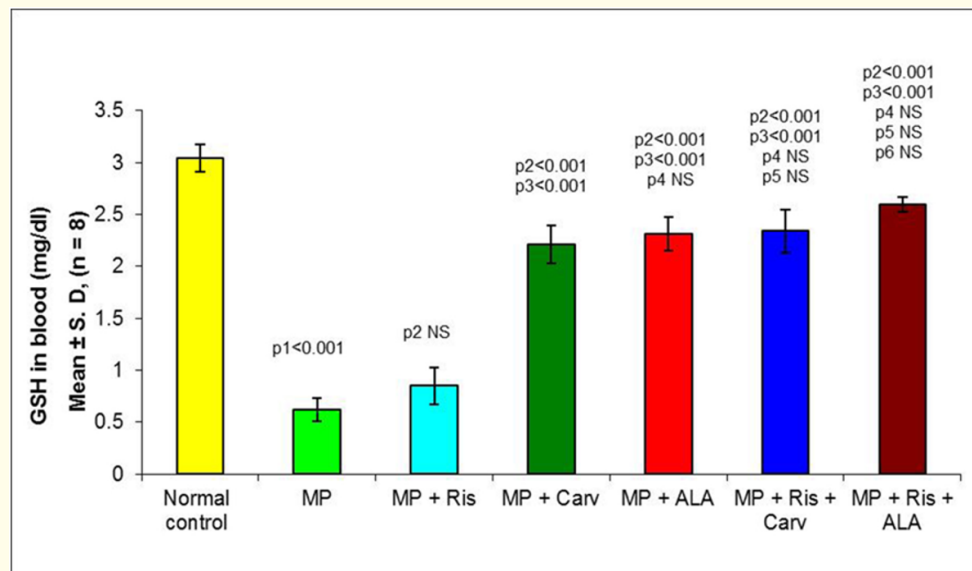


Figure 2: GSH in blood (mg/dl) in different studied groups.

-Values are expressed as mean ± SD, n: Number, NS: Non-Significant

-Scheffe test

- P1: Comparison of group II (MP) Vs group I (normal control)
- P2: Comparison of group III (MP + Ris), IV (MP + Carv), V (MP + ALA), VI (MP + Ris + Carv), VII (MP + Ris + ALA) Vs group II (MP)
- P3: Comparison of group IV (MP + Carv), V (MP + ALA), VI (MP + Ris + Carv), VII (MP + Ris + ALA) Vs group III (MP + Ris)
- P4: Comparison of group V (MP + ALA), VI (MP + Ris + Carv), VII (MP + Ris + ALA) Vs group IV (MP + Carv)
- P5: Comparison of group VI (MP + Ris + Carv), VII (MP + Ris + ALA) Vs group V (MP + ALA)
- P6: Comparison of group VII (MP + Ris + ALA) Vs group VI (MP + Ris + Carv).

MP: Methyl Prednisolone; Ris: Risedronate; Carv: Carvedilol; ALA: Alpha Lipoic Acid.

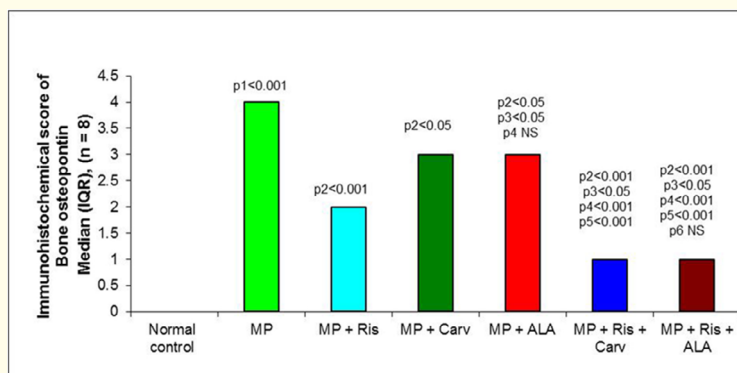


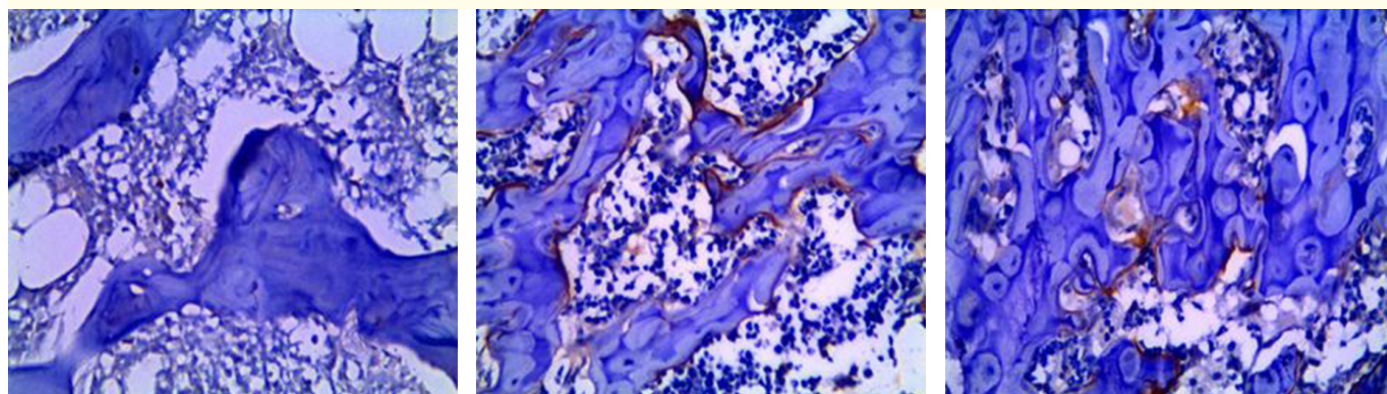
Figure 3: Values of immunohistochemical detection of bone osteopontin in different studied groups.

-Values are expressed as median (IQR), n: Number, NS: Non-Significant

- Mann-Whitney test: p value:

- P1: Comparison of group II (MP) Vs group I (normal control).
- P2: Comparison of group III (MP + Ris), IV (MP + Carv), V (MP + ALA), VI (MP + Ris+ Carv), VII (MP + Ris+ALA) Vs group II (MP)
- P3: Comparison of group IV (MP + Carv), V (MP + ALA), VI (MP + Ris+ Carv), VII (MP + Ris+ALA) Vs group III (MP + Ris).
- P4: Comparison of group V (MP + ALA), VI (MP + Ris + Carv), VII (MP + Ris+ALA) Vs group IV (MP + Carv).
- P5: Comparison of group VI (MP + Ris + Carv), VII (MP + Ris+ALA) Vs group V (MP + ALA).
- P6: Comparison of group VII (MP + Ris+ALA) Vs group VI (MP + Ris + Carv).

MP: Methyl Prednisolone; Ris: Risedronate; Carv: Carvedilol; ALA: Alpha Lipoic Acid.



a

b

c

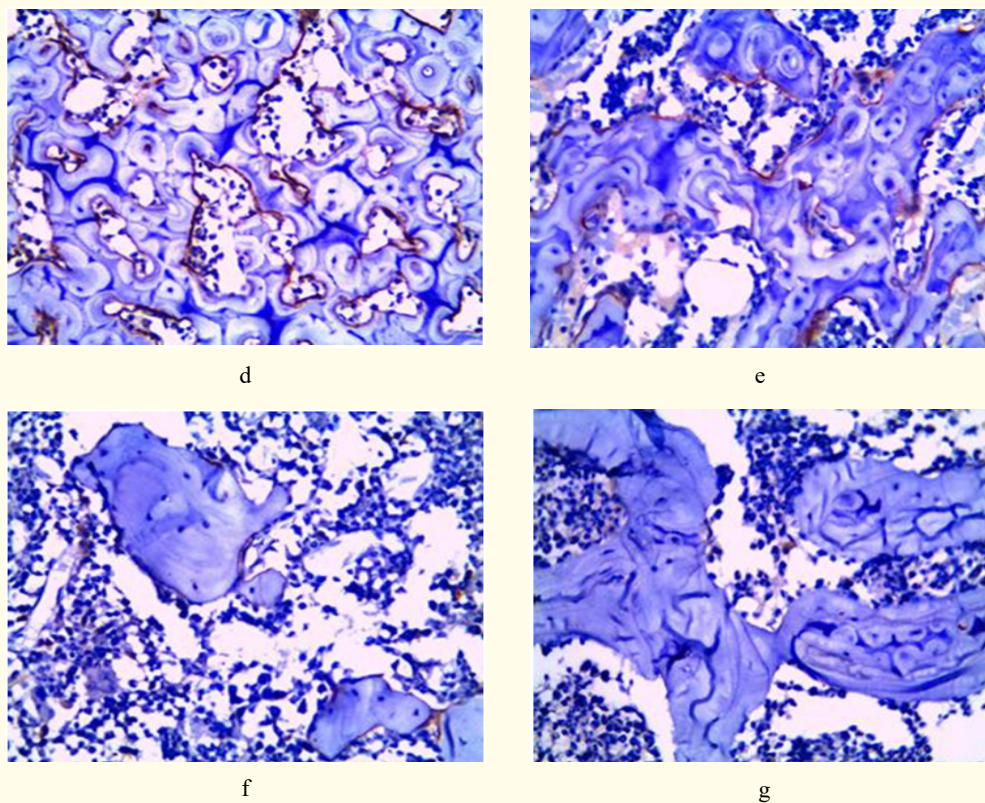
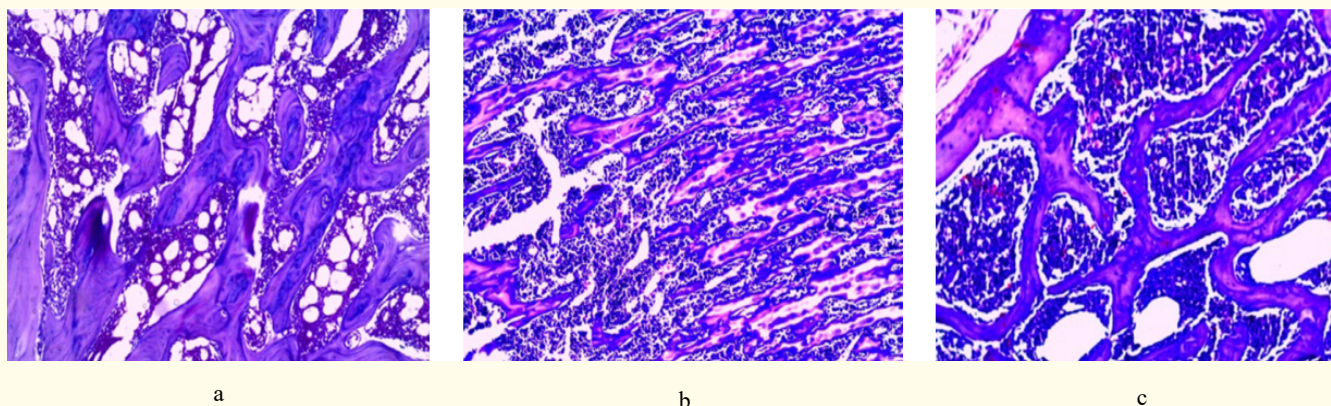


Figure 4: Immunohistochemical expression of bone osteopontin in different studied groups. (A) Section of rat femur of group I (Normal control group) showing negative expression for osteopontin. (B) Section of rat femur of group II (untreated osteoporosis -induced group) showing strong positive (++++) expression for osteopontin. (C) Section of rat femur of group III (MP and risedronate treated group) showing mild to moderate positive (++) expression for osteopontin. (D) Section of rat femur of group IV (MP and carvedilol treated group) showing moderate positive (+++) expression for osteopontin. (E) Section of rat femur of group V (MP and ALA treated group) showing moderate positive (+++) expression for osteopontin. (F) Section of rat femur of group VI (MP, risedronate and carvedilol treated group) showing mild positive (+) expression for osteopontin. (G) Section of rat femur of group VII (MP, risedronate and ALA treated group) showing mild positive (+) expression for osteopontin, (PAP×400).



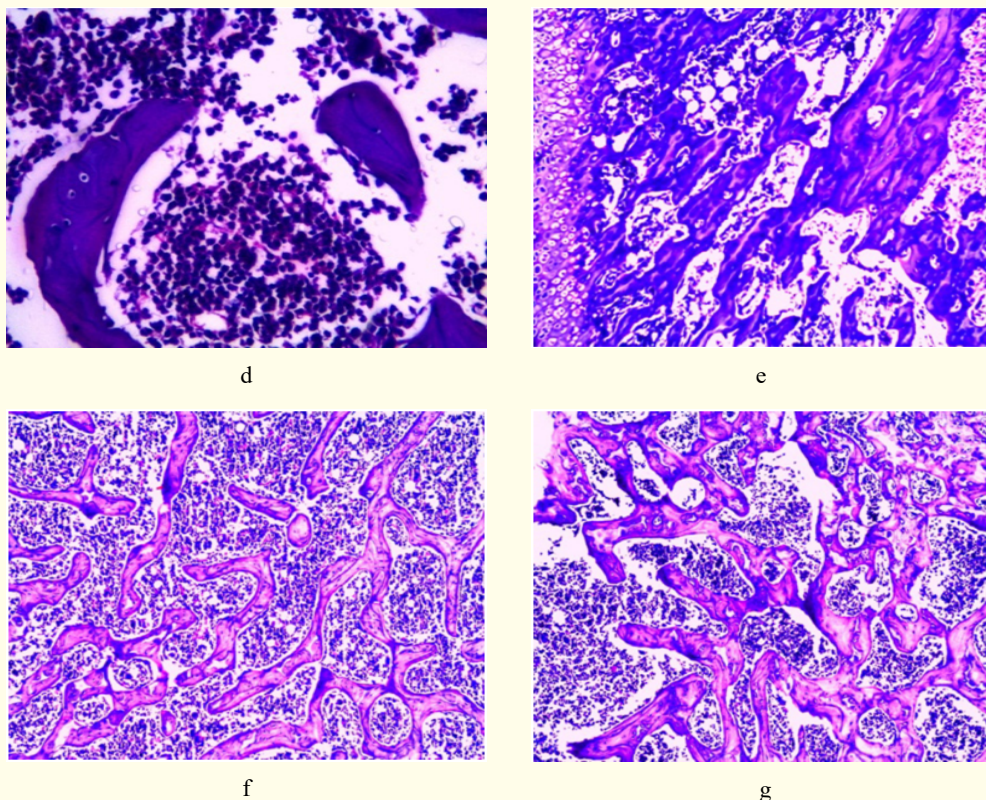


Figure 3: Light microscope histopathological results of (H and E) stained sections of bone in different studied groups. (A) Section of rat femur of group I (Normal control group) showing normal thickness of cancellous bone trabeculae, normal osteocytes in their lacunae (H and E x 400). (B) Section of rat femur of group II (untreated osteoporosis-induced group) showing apparent thinning of inner cancellous bone trabeculae which lost their architecture and appeared as discontinuous bony ossicles separated by widen bone marrow spaces (H and E x 100). (C) Section of rat femur of group III (MP and risedronate treated group) showing mild to moderate increase in thickness of both outer cortical bone, trabeculae of cancellous bone, small sized erosion cavities (H and E x 200). (D) Section of rat femur of group IV (MP and carvedilol treated group) showing mild increase in thickness of trabeculae of cancellous bone, small sized erosion cavities (H and E x 400). ((E) Section of rat femur of group V (MP and ALA treated group) showing mild increase in thickness of trabeculae of cancellous bone, small sized erosion cavities (H and E x 200). (F) Section of rat femur of group VI (MP, risedronate and carvedilol treated group) showing normal thickness and architecture of cancellous bone trabeculae (H and E x 100). (G) Section of rat femur of group VII (MP, risedronate and ALA treated group) showing normal thickness and architecture of cancellous bone trabeculae (H and E x 100).

Similar to our work, Khajuria DK., *et al.* [15] reported that bisphosphonate zoledronic acid and β blocker propranolol combination therapy was able to counteract bone loss in a rat model of postmenopausal osteoporosis indicating that addition of propranolol to anti-resorptive therapy with zoledronic acid is superior to either of them alone. Carvedilol used in this work is superior to propranolol due to its antioxidant effect.

All the above drugs, carvedilol, ALA, combinations improved all parameters compared to risedronate alone. However, Serum calcium and bone osteopontin were the only parameters that were improved in group treated by risedronate alone compared to untreated osteoporosis-induced group. The two combinations either risedronate with carvedilol or risedronate with ALA showed better outcomes than using single drug. But, there was no difference between these two combinations in all parameters.

In the current experiment, it was confirmed that the evident ameliorating effect on catabolic bone markers was established by risedronate and the evident ameliorating effect of carvedilol and ALA was in correction of the oxidative stress state and enhancement of the bone regenerative capacity concluding that, addition of carvedilol or ALA to risedronate is superior to monotherapy by either risedronate or carvedilol or ALA evidenced by better improvement of biochemical bone indices that indicate increased bone formation and decreased bone destruction, better improvement of histopathology and microarchitecture of femurs, also by improvement of oxidative stress and antioxidant status.

All the above drugs, carvedilol, ALA, combinations improved all parameters compared to risedronate alone. However, Serum calcium and bone osteopontin were the only parameters that were improved in group treated by risedronate alone compared to untreated osteoporosis-induced group. The two combinations either risedronate with carvedilol or risedronate with ALA showed better outcomes than using single drug. But, there was no difference between these two combinations in all parameters.

Conclusion

These findings suggest that carvedilol or ALA coadministration with risedronate could be a valuable combination and the two combinations are equally effective to prevent and treat GIO showing better outcomes than monotherapy. These finding should be progressed into further clinical studies to be verified in human.

Acknowledgments

Special thanks to Prof. Dr. Karima El-Desoky professor of Histopathology, Faculty of Medicine, Tanta University, for helping me in carrying out the histopathological, immunohistochemical examination and helping me in photo -imaging and in finishing this work.

Conflict of Interest

The authors declare no conflicts of interest.

Bibliography

1. Gopal Das B., *et al.* "Prevalence and risk factors of osteopenia and osteoporosis in Indian women". *IOSR-JDMS* 15.12 (2016): 15-18.
2. Guo T., *et al.* "Acupuncture for osteoporosis: a systematic review protocol". *Systematic Reviews* 5.1 (2016): 161.
3. Ulivieri FM., *et al.* "Utility of the trabecular bone score (TBS) in secondary Osteoporosis". *Endocrine* 47.2 (2014): 435-448.
4. Xu D., *et al.* "miR-365 Ameliorates Dexamethasone-Induced Suppression of Osteogenesis in MC3T3-E1 Cells by Targeting HDAC4". *International Journal of Molecular Sciences* 18.5 (2017): 977.
5. Shahi M., *et al.* "Regulation of Bone Metabolism". *Reports of Biochemistry and Molecular Biology* 5.2 (2017): 73-82.
6. Florencio-Silva R., *et al.* "Biology of bone tissue. structure, function, and factors that influence bone cells". *BioMed Research International* (2015): 421746.
7. Panday K., *et al.* "Medication-induced osteoporosis. screening and treatment strategies". *Therapeutic Advances in Musculoskeletal Disease* 6.5 (2014): 185-202.
8. Naeem ST., *et al.* "Bone Turnover Markers for Osteoporosis Status Assessment at Baseline in Postmenopausal Pakistani Females". *Journal of the College of Physicians and Surgeons Pakistan* 26.5 (2014): 408-412.
9. Briot K and Roux C. "Glucocorticoid-induced osteoporosis". *Rheumatic and Musculoskeletal Disease Open* 1.1 (2015): e000014.
10. Kopal M., *et al.* "Effects of melatonin on tibia bone defects in rats". *International Journal of Morphology* 34.2 (2016): 763-769.

11. Suen PK and Qin L. "Sclerostin, an emerging therapeutic target for treating osteoporosis and osteoporotic fracture. A general review". *Journal of Orthopaedic Translation* 4 (2016): 1-13.
12. Dokmeci MO., et al. "The effect of ibandronate on fracture healing in rat tibia model". *SM Journal of Orthopaedics* 2.4 (2016): 1041.
13. El-Shitany NA and El-Desoky K. "Protective effects of carvedilol and vitamin C against azithromycin-induced cardiotoxicity in Rats via decreasing ROS, IL1- β , and TNF- α Production and Inhibiting NF- κ B and Caspase-3 expression". *Oxidative Medicine and Cellular Longevity* (2016): 1874762.
14. Elefteriou F., et al. "Control of bone remodeling by the peripheral sympathetic nervous system". *Calcified Tissue International* 94.1 (2014): 140-151.
15. Khajuria DK., et al. "Additive effects of zoledronic acid and propranolol on bone density and biochemical markers of bone turnover in osteopenic ovariectomized rats". *Revista Brasileira de Reumatologia* 55.2 (2014): 103-112.
16. Ferreira Dias KC., et al. "Alpha-Lipoic Acid Effects on Reserpine-Induced Depression-Like Behavior in Mice". *JSM Anxiety and Depression* 1.2 (2016): 1010.
17. Tuncer AA., et al. "The Protective Effects of Alpha-Lipoic Acid and Coenzyme Q10 Combination on Ovarian Ischemia-Reperfusion Injury: An Experimental Study". *Advances in Medicine* (2016): 3415046.
18. Connerty HV and Briggs AR. "Determination of serum calcium by means of orthocresolphthale in complex one". *American Journal of Clinical Pathology* 45.3 (1966): 290-296.
19. Ohkawa H., et al. "Assay for lipid peroxides in animal tissues by thiobarbituric acid reaction". *Analytical Biochemistry* 95.2 (1979): 351-358.
20. Beutler E., et al. "Improved method for the determination of blood glutathione". *Journal of Laboratory and Clinical Medicine* 61 (1979): 882-888.
21. Li Y., et al. "A Young Adult Woman with Severe Osteoporosis due to Cushing's Disease: A Case Report and Literatures Review". *JIMT* 27.5 (2016): 267-273.
22. Valenti MT., et al. "The effect of risedronate on osteogenic lineage is mediated by cyclooxygenase-2 gene upregulation". *Arthritis Research and Therapy* 12.4 (2010): R163.
23. Folwarczna J., et al. "Effects of propranolol on the development of glucocorticoid-induced osteoporosis in male rats". *Pharmacological Reports* 63.4 (2011): 1040-1049.
24. Kikuchi Y., et al. "Effect of risedronate on high-dose corticosteroid-induced bone loss in patients with glomerular disease". *Nephrology Dialysis Transplantation* 22.6 (2007): 1593-1600.
25. Toumi H., et al. "Exercise and Anti-Osteoporotic Medication Combined Treatment for Osteoporosis". *Journal of Yoga and Physical Therapy* 6 (2016): 232.
26. Zhang J., et al. "Icariin attenuates glucocorticoid-induced bone deteriorations, hypocalcemia and hypercalciuria in mice". *International Journal of Clinical and Experimental Medicine* 8.5 (2015): 7306-7314.
27. Chen Z., et al. "Curcumin alleviates glucocorticoid-induced osteoporosis through the regulation of the Wnt signaling pathway". *International Journal of Molecular Medicine* 37.2 (2016): 329-338.
28. Banji D., et al. "Role of Triticum aestivum aqueous extract in glucocorticoid induced osteoporosis in rat". *Indian Journal of Experimental Biology* 52.2 (2014): 153-158.

29. Zhang S., *et al.* "Plumbagin protects against glucocorticoid-induced osteoporosis through Nrf-2 pathway". *Cell Stress and Chaperones* 20.4 (2015): 621-629.
30. Elshal MF, *et al.* "Synergistic antiosteoporotic effect of lepidium sativum and alendronate in glucocorticoid-induced osteoporosis in wistar rats". *African Journal of Traditional, Complementary and Alternative Medicines* 10.5 (2013): 267-273.
31. Yao W., *et al.* "Glucocorticoid-induced bone loss in mice can be reversed by the actions of parathyroid hormone and risedronate on different pathways for bone formation and mineralization". *Arthritis and Rheumatology* 58.11 (2008): 3485-3497.
32. Liu D., *et al.* "Carvedilol promotes neurological function, reduces bone loss and attenuates cell damage after acute spinal cord injury in rats". *Clinical and Experimental Pharmacology and Physiology* 42.2 (2015): 202-212.
33. Cavalier E., *et al.* "The role of biochemical of bone turnover markers in osteoporosis and metabolic bone disease: a consensus paper of the Belgian Bone Club". *Osteoporosis International* 27.7 (2016): 2181-2195.
34. Ma Y., *et al.* " β 2-Adrenergicreceptor signaling in osteoblasts contributes to the catabolic effect of glucocorticoids on bone". *Endocrinology* 152.4 (2011): 1412-1422.
35. Araujo Junior R., *et al.* "Carvedilol Decrease IL-1b and TNF- α ,Inhibits MMP-2, MMP-9, COX-2, and RANKL Expression, and Up-Regulates OPG in a Rat Model of Periodontitis". *Plos One* 8.7 (2013): e66391.
36. Sliwinski L., *et al.* "Effects of fenoterol on the skeletal system depend on the androgens level". *Pharmacological Reports* 69.2 (2016): 260-267.
37. Jung JH., *et al.* "Alpha Lipoic Acid Attenuates Radiation-Induced Thyroid Injury in Rats". *PLoS ONE* 9.11 (2014): e112253.
38. Lu S., *et al.* "The osteogenesis-promoting effects of alpha-lipoic acid against glucocorticoid-induced osteoporosis through the NOX4, NF-kappa B, JNK and PI3K/AKT pathways". *Scientific Reports* 7.1 (2017): 3331.

Volume 6 Issue 9 September 2018

©All rights reserved by Monira A Selim., *et al.*