

The Effectiveness of CT-Guided Perineural Injection of Triamcinolone and Lidocaine 2% on the Pain of Patients with Lumbar Disc Herniation

Mohammad Davoodi¹, Mohammad Momen Gharibvand^{2*}, Neda Nikpour², Alireza Teimouri³, Azim Motamedfar² and Fakher Rahim³

¹Department of Radiology, Shariati Hospital, Tehran University of Medical Sciences, Tehran, Iran

²Department of Radiology, Golestan Hospital, Ahvaz Jundishapur University of Medical Sciences, Ahvaz, Iran ²Department of Neurosurgery, Golestan Hospital, Ahvaz Jundishapur University of Medical Sciences, Ahvaz, Iran

³Health Research Institute, Thalassemia and Hemoglobinopathies Research Center, Ahvaz Jundishapur University of Medical Science, Ahvaz, Iran

***Corresponding Author:** Mohammad Momen Gharibvand, Department of Radiology, Golestan Hospital, Ahvaz Jundishapur University of Medical Sciences, Ahvaz, Iran.

Received: July 10, 2018; **Published:** August 08, 2018

Abstract

The aim of this study is to investigate the effectiveness of CT-guided perineural injection of corticosteroid (triamcinolone) and local anesthetic (lidocaine 2%) on the amount of pain of the patients with lumbar disc herniation in Imam Khomeini and Golestan hospitals during 2013 - 2014. In this study, 54 outpatients introduced to the radiology section (CT scan) by neurologist and neurosurgeons for perineural injection were studied. Friedman test was used to compare the overall recovery process (amount of pain and disability) during the treatment course. The results showed a significant decrease in the amount of pain and disability among patients ($P < 0.05$). Analgesic treatment was improved significantly on the seventh day after the injection. Pain relief lasted up to 6 months after injection, but its difference decreased during 3-6 months after injection. It is known that most complications from surgery in the last 40 years have the desired effect in the treatment of back pain. Generally, our findings indicate that this treatment is effective in reducing the amount of pain. According to these findings, and considering the very low side effects of perineural injection and its significant effect on recovery process of the patients, this method does not have the limitations and side effects of other treatment procedures. Thus, this method and its short recovery period may consider as a valuable alternative for complicated surgeries and their long recovery period. Moreover, this method can reduce the high costs of unnecessary surgeries.

Keywords: CT Scan; Disc Herniation; Perineural Injection

Introduction

Low back pain is one of the most common causes of disability in adults of working age. Sixty to 80 percent of adults have suffered from back pain at some point in their life. The medical costs of back pain exceed \$ 50 million per year and may even reach to \$ 100 million [1]. The prevalence of chronic back pain in adults is estimated to 15%, but may reach to 44% by aging up to 70 years old [2-4]. Medical treatment with steroids, anti-inflammatory drugs, and diets from physical treatment can revive the inflammatory component and remove the complications. Surgery might be necessary in case the pain persists as a result of mechanical stress [1]. One of the treatments that can be utilized for such patients is nerve block, which includes anesthesia or anti-inflammatory injection to a nerve or group of nerves in order to remove pain. The purpose of injection is to shut down the pain signal emerging from a particular part of the body, or to reduce inflammation in that part [5].

Based on new beliefs, it seems that sciatica pain is not only due to mechanical stress but is also associated with the chemical inflammation of nerve due to disc stimulation, which is a certain factor in progression to severe sciatica [4-6]. Therefore, the use of topical corticosteroids in the area of inflammation and nerve pressure seems to be a suitable treatment [6]. Nerve block in patients with radicular pain who do not respond to medical therapy and have no indications for surgical treatment could be a low risk and less invasive method compared to surgery [7-9].

Purpose of the Study

The purpose of this study is to investigate the effectiveness of CT-guided perineural injection of corticosteroid (triamcinolone) and local anesthetic (lidocaine 2%) on the amount of pain of the patients with lumbar disc herniation in Imam Khomeini and Golestan hospitals during 2013 - 2014.

Material and Methods

Statistical population of the research: In this study, 54 outpatients introduced to the radiology section (CT scan) of Imam Khomeini and Golestan hospitals by neurologist and neurosurgeon for perineural injection were studied.

Inclusion criteria: All patients who certainly have lateral herniation based on their MRI and did not respond well to standard oral treatment after 6 weeks, as well as patients over 18 years old, were included in this study.

Exclusion criteria: Patients in need of surgery (whose need to surgery is diagnosed by the neurologist), contraindication to the use of the study medication (triamcinolone and lidocaine), previous surgery on the lumbar spine, and deformity of lumbar spine were excluded from the study.

Methods: The outpatients chosen by the neurologist and neurosurgeon for perineural injection were introduced to the radiology section of Imam Khomeini hospital. First, their detailed biography and physical and neurologic examination is recorded in information form of the patients, as well as their imaging findings. Then, if they do not suffer from coagulopathy, they will be chosen by the doctor based on their imaging findings of the root or nerve roots. The patients lay on CT scan bed in prone mode, and the linear radiodense marker will be placed on the desired location of the patient's back. All steps were done by the CT scan device High-Q, Siemens, Somerton, Germany, with no angle and slicing thickness of 8 mm. All scans were planned based on abdomen axis of 120 KW and the minimum available dosage of 240 mAs for reducing the amount being exposed to the ray [11]. Based on the image of that point or point, the entrance of the needle is marked on the patient's back, and the image will be taken from the desired location. An expert radiologist enters the desired point(s) of the patient's back after sterilizing (lubricating the back with Betadine and covering other areas in the back by their perforated spinal needle No. 20 - 22 with length of 9 - 12 cm), and then the needle goes forward just near the inter vertebral foramen, while being guided by the CT scan (Figure 1), then less than 0.5 cc Omnipaque 240mmol/ml will be injected to the desired area in order to make sure where is the exact location of the needle tip, then 1.5 cc of the mixture of triamcinolone 40 mg and lidocaine 2% will be injected adjacent to the nerve root (Figure 2), and then the needle will be gently removed. Afterwards, the patient will be under surveillance for 30 minutes, will be released after ensuring the appropriateness of their overall health. Then their clinical signs will be checked after 1 week, 1 month, 3 months, and 6 months, by visual analog scale (which is a psychology test and a device for measuring subjective cases which cannot be measured directly). The patients will rate their pain in the range of 0 (no pain) to 10 (severe pain) before/after treatment. This question will be asked by the doctor (as the questioner) from the patient. In this study: 0 is considered as no pain, 1 - 3 is considered as mild pain, 4 - 6 is considered as moderate pain, and 7 - 10 is considered as severe pain. Pain reduction and improving the functionality and activity of the patient compared to the state before treatment is considered as the answers of good to excellent. The answers of patients to the treatment were compared to the state before treatment.

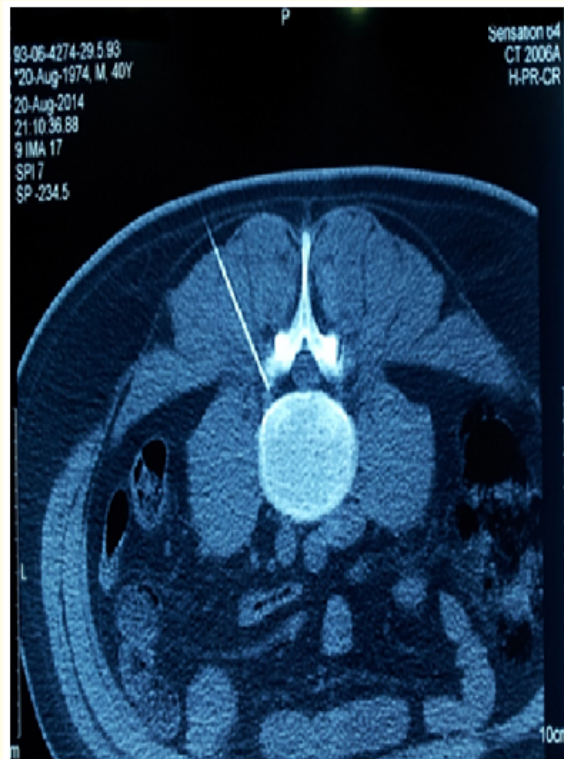

Figure 1: Lateral perineural injection. Correct needle positioning at the intervertebral foramen. Less than 0.5 cc Omniopaque 240 mmol/ml will be injected to the desired area.

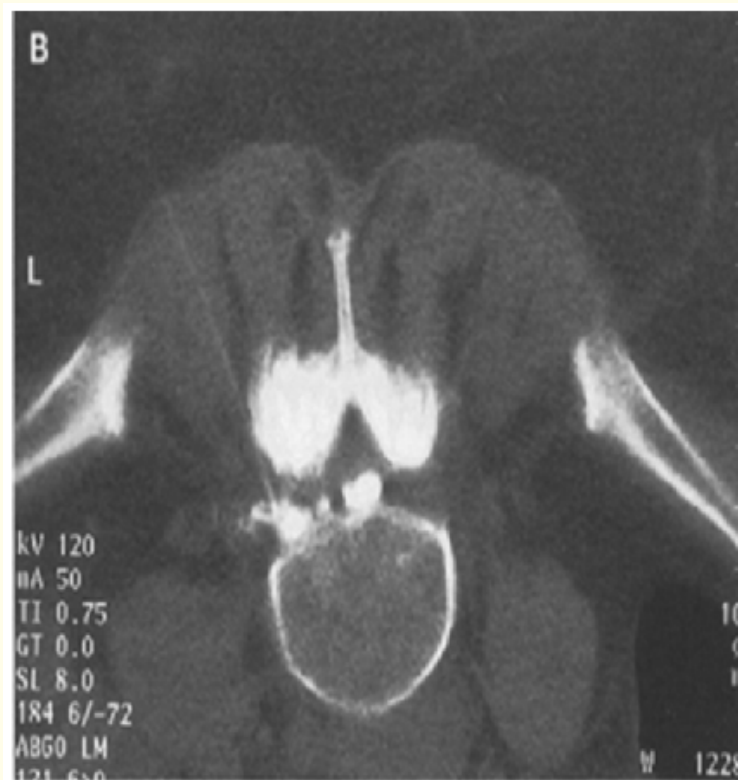

Figure 2: 1.5 cc of the mixture of triamcinolone 40 mg and lidocaine 2% will be injected adjacent to the nerve root at the intervertebral foramen.

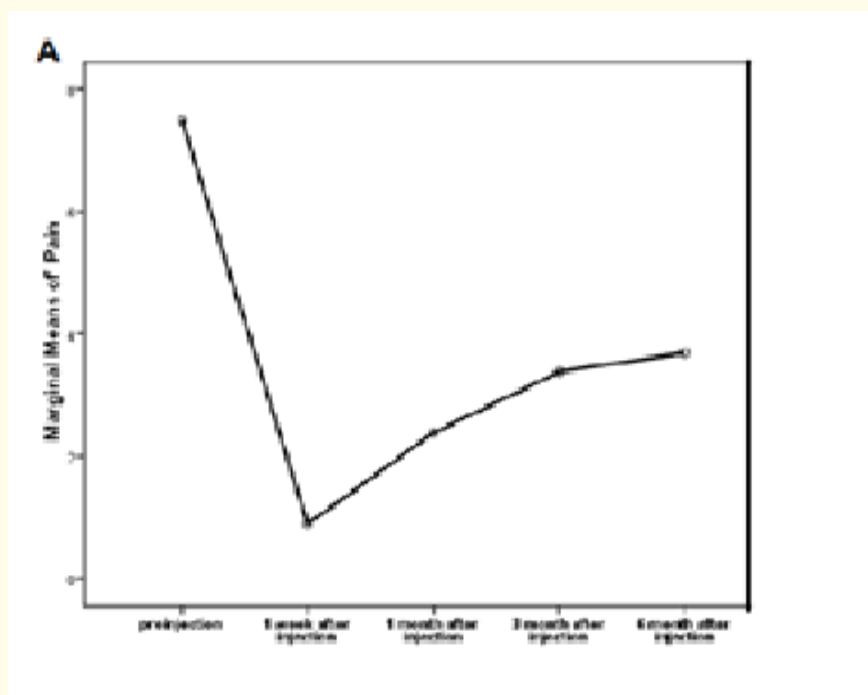
Statistical analysis: After gathering data by SPSS 17 statistical software, the descriptive statistics (mean, standard deviation) was used. The Wilcoxon and Friedman test was used for analyzing data before/after treatment which uses a visual analog scale.



Results

The obtained results indicate a significant decrease in the amount of pain and disability in the patients during the study ($P < 0.05$) (Table 1). In order to compare the general trend of recovery (amount of pain and disability), the Friedman test was used during the treatment course. The obtained results indicate a significant decrease in the amount of pain and disability in the patients during the study ($P < 0.05$). Analgesic treatment was improved significantly on the seventh day after the injection. Pain relief lasted up to 6 months after injection, but its difference decreased during 3 - 6 months after injection. It is known that most complications from surgery in the last 40 years have the desired effect in the treatment of back pain.

		Pre-injection	1 week after injection	1 month after injection	3 month after injection	6 month after injection	P-value
Pain	None	0 (0%)	27 (49.1%)	3 (5.5%)	2 (3.6%)	0 (0%)	< 0.001
	Mild	0 (0%)	25 (45.5%)	40 (72.7%)	26 (47.3%)	22 (40%)	
	Moderate	7 (12.7%)	3 (5.5%)	12 (21.8%)	27 (49.1%)	33 (50%)	
	Severe	48 (87.3%)	0 (0%)	0 (0.0%)	0 (0%)	0 (0%)	

Table 1: Trend of reduction of the amount of pain and disability (no, mild, moderate, severe pain).








Figure 3: Shows the change in the amount of pain in the patients versus time, and the effect of variables such as gender, the location of a disc, and injection area on it. Pain reduction in patients indicates the significant difference ($P < 0.001$).

Pain trend versus time: Significant recovery was observed in the seventh day after injection (Figure 3). The recovery process lasts up to 6 months, but its difference decreases during 3 - 6 months after injection. The amount of pain reduction in the first week after injection was the same in all 3 panniers, then, after one month, panniers 3 - 4 showed an increasing trend for pain compared to the other panniers, in which the increase was significant (Figure 3A). The effect of gender is not significant on pain reduction (Figure 3B) ($P = 0.29$). The injection area was investigated in from the aspect of one-way and two-way injection, which was significant ($P < 0.05$). This issue was more significant in pain reduction in patients with two-way injection ($P = 0.001$) (Figure 3C). The pain reduction trend was significant regarding the surface area and location of the injection ($P = 0.002$) (Figure 3D).

Discussion

In the area of pain treatment, the methods based on different drugs and housing has been widely used to control and treat the pain. In this study, the effectiveness of a CT-guided perineural injection of corticosteroid (triamcinolone) and local anesthetic (lidocaine 2%) on the amount of paint of the patients with lumbar disc herniation were investigated.

Generally, the findings indicate that this treatment method is effective in pain reduction. Significant recovery was observed in the seventh day after injection. The recovery process lasts up to 6 months, but its difference decreases during 3 - 6 months after injection. These findings are in agreement with the findings of Schmid, *et al* [5]. Who treated thirty-two patients suffering from chronic low back pain for 6 weeks by injection of CT-guided triamcinolone. The treatment success evaluated by visual analog scale and physical examination showed that the good to excellent recovery was obtained in 91% of the patients at the end of the treatment course. Such a recovery was obtained in 56% of the patients after long treatment course (6 - 9 months). Furthermore, Uhlenbrock, *et al*. [10] Showed in their study of 56 people suffering from low back pain being treated by CT-guided triamcinolone injection that the full recovery was obtained in 55% of

the patients, temporary recovery was obtained in 30% of the patients, and no recovery was obtained in 15% of the patients compared to the state before treatment. In another study, Lutze, *et al* [11]. Investigated 120 patients treated by CT-guided triamcinolone injection for 1 - 6 months. They showed that this treatment process results in a better recovery after long treatment courses. In another study, Wald, *et al* [12]. Treated 59 patients by CT-guided triamcinolone injection and showed that 37.9% of patients responded to the treatment after 2 months and 20.7% had complete pain relief. For functional recovery, 34.5% of respondents showed improvement in 2 months.

It is known that most complications from surgery in the last 40 years have the desired effect in the treatment of back pain. Regarding this issue, and considering the very low side effects of perineural injection and its significant effect on the recovery process of the patients, this method does not have the limitations and side effects of other treatment procedures. Thus, this method and its short recovery period may consider as a valuable alternative for complicated surgeries and their long recovery period. Moreover, this method can reduce the high costs of unnecessary surgeries.

Conclusion

The important point of using CT-guided anesthetic treatment is that performing the precise and correct block diagnosis requires particular skills, and if the user has the sufficient skills in performing it, it is a safe, quick, and repeatable process. Regarding the benefits of this treatment method, it is suggested to the experts and researchers in the field of pain to conduct more researches in this area.

Bibliography

1. Chou R, *et al*. "Diagnosis and treatment of low back pain: a joint clinical practice guideline from the American College of Physicians and the American Pain Society". *Annals of Internal Medicine* 147.7 (2007): 478-491.
2. Puntumetakul R, *et al*. "Prevalence and individual risk factors associated with clinical lumbar instability in rice farmers with low back pain". *Patient Preference and Adherence* 9 (2015): 1-7.
3. Garcia JB, *et al*. "Prevalence of low back pain in Latin America: a systematic literature review". *Pain Physician* 17.5 (2014): 379-391.
4. Durlov S, *et al*. "Prevalence of low back pain among handloom weavers in West Bengal, India". *International Journal of Occupational and Environmental Health* 20.4 (2014): 333-339.
5. Schmid G, *et al*. "CT-guided epidural/perineural injections in painful disorders of the lumbar spine: short- and extended-term results". *Cardiovascular and Interventional Radiology* 22.6 (1999): 493-498.
6. Gautier PE, *et al*. "Impairment of sciatic nerve function during adductor canal block". *Regional Anesthesia and Pain Medicine* 40.1 (2015): 85-89.
7. Wellington J. "Noninvasive and alternative management of chronic low back pain (efficacy and outcomes)". *Neuromodulation: Journal of the International Neuromodulation Society* 17.2 (2014): 24-30.
8. Ivanova JL, *et al*. "Duloxetine use in employees with low back pain: treatment patterns and direct and indirect costs". *Pain Medicine* 15.6 (2014): 1015-1026.
9. Schmitt H, *et al*. "[Acupuncture treatment of low back pain]". *Schmerz* 15.1 (2001): 33-37.
10. Uhlenbrock D and Arlinghaus J. "[Results of CT-guided periradicular pain therapy]". *RoFo: Fortschritte auf dem Gebiete der Rontgenstrahlen und der Nuklearmedizin* 166.6 (1997): 528-534.

11. Lutze M., *et al.* "Periradicular therapy in lumbar radicular syndromes: methodology and results". *Acta Neurochirurgica* 139.8 (1997): 719-724.
12. Wald JT., *et al.* "A practice audit of CT-guided injections of pars interarticularis defects in patients with axial low back pain: a primer for further investigation". *Pain Medicine* 15.5 (2014): 745-750.

Volume 6 Issue 9 September 2018

©All rights reserved by Neda Nikpour., *et al.*