

Hyper IgM Syndrome: A Rare Cause of Recurrent Pneumonia

Atef Elrifai¹ and Ahmed Fayed^{2*}

¹Lecturer of Pulmonary and Critical Care Medicine, Al-Azhar University, Damietta Governorate, Egypt

²Interventional Pulmonologist, Mansoura Chest Hospital, Dakahlia Governorate, Egypt

*Corresponding Author: Ahmed Fayed, Interventional Pulmonologist, Mansoura Chest Hospital, Dakahlia Governorate, Egypt.

Received: November 04, 2019; Published: December 09, 2019

Abstract

Hyper IgM is rare condition usually missed in our practice with variable presentation and may present by recurrent pneumonia due to defective immune system. There is deficiency in Ig G, A, E but may be normal or increased Ig M. The CD40L deficiency is the most common form of this rare disease and definitive diagnosis is by mutation analysis. Curative diagnosis is only by allogeneic hematopoietic cell transplantation (HCT). We illustrate her one of this rare cases presented by recurrent pneumonia that diagnosed by laboratory deficiency of Ig A, G with increased Ig M that received medical treatment and progressed smoothly.

Keywords: Hyper Ig M; Immunodeficiency; Recurrent Pneumonia; Hematopoietic Cell Transplantation

Abbreviations

Ig M: Immunoglobulin M; Ig G: Immunoglobulin G; Ig A: Immunoglobulin A; Ig E: Immunoglobulin E; HCT: Hematopoietic Cell Transplantation; IVIG: Intravenous Immune Globulin; CBC: Complete Blood Count; CT: Computerized Tomography; TB: Tuberculous Bacilli; AFB: Acid Test Bacilli; CXR: Chest X Ray; CSR: Class-Switch Recombination; G-CSF: Granulocyte Colony-Stimulating Factor; ECHO: Electrocardiography; CD: Cluster of Differentiation; ESR: Erythrocyte Sedimentation Rate; RF: Rheumatoid Factor; ANA: Antinuclear Antibody; DNA: Deoxyribonucleic Acid; PE: Pulmonary Embolism

Introduction

Hyper IgM is one of the primary immunodeficiency disorders that is characterized by deficiency of immunoglobulin G (IgG), immunoglobulin A (IgA), and immunoglobulin E (IgE) and normal or increased levels of serum IgM (despite the name hyper Ig M syndrome) and usually missed in diagnosis due to variable presentations. It is a group of heterogeneous characters including many types of which the x linked form is the commonest [1-4]. Diagnosis and management is a challenge and the definitive treatment is allogeneic hematopoietic cell transplantation (HCT) although other supportive measures was implemented as intravenous immune globulin (IVIG) [5,6].

Case Report

26y old Egyptian female married and house wife without special habits of medical important complain of shortness of breath for previous month with productive cough and continuous fever associated with upper abdominal discomfort received many courses of antibiotics as outpatient. Patient gave history of recurrent tonsillitis and many episodes of respiratory tract infection with cough, expectoration of moderate amount of mucopurulent sputum and fever associated with vague chest pain.

On presentation patient showed fever 38.5C, fine left basal crepitation with bronchial breath sound, heart rate of 115 beat per minute respiratory rate 26 cycle per minute and blood saturation of 93% by pulse odometer on room air. Liver function tests, renal function tests and CBC all within normal limit but ESR above 100 with hypernatremia (166) and hypokalemia (3.2).

Chest x ray (Figure 1) showed left sided moderate pleural effusion and d-dimer 1544 ng/ml So suspicion of pulmonary embolism going on for which CT pulmonary angiography done (Figure 2) but reported as negative for PE but left pleural effusion with consolidation collapse and also Trans-thoracic ECHO reported as normal study. Diagnostic thoracocentesis was done and sent for analysis with results microbiological results negative for AFB (and later on culture for TB also negative), biochemistic results protein 3.7 g/dl, glucose 87, LDH 3008 u/L and histopathological analysis reported as no evidence of malignancy.

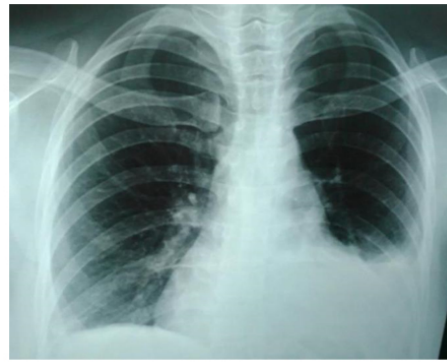


Figure 1: CXR at presentation with left pleural effusion.

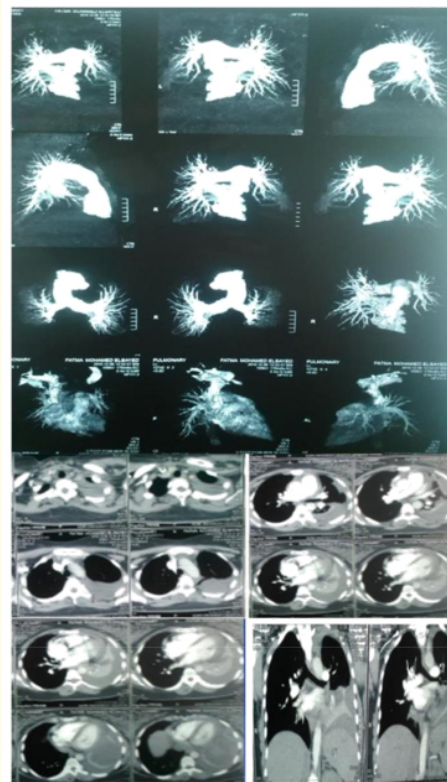


Figure 2: Representative slides from chest with contrast negative for PE with right pleural effusion and consolidation collapse.

Pneumonia with parapneumonic empyema was the diagnosis and patient received antibiotics and progress smoothly with improvement of CXR (Figure 3) together with the clinical status and was discharged home.

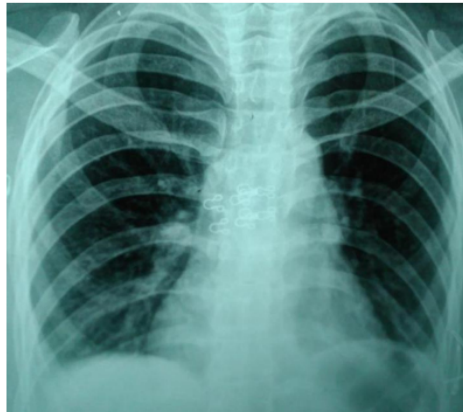

Figure 3: CXR at discharge with resolved left pleural effusion.

Unfortunately, patient returned again after one month by the same symptoms and chest examination revealed right fine basal crepitations with CXR showed rt middle and lower lung zone paracardiac heterogeneous opacity (Figure 4) for which antibiotics was prescribed with one week follow up. One week later CT chest was done as patient still complain that showed right pleural effusion with consolidation collapse (Figure 5). At this point patient was investigated for possible specific diagnosis behind his condition with negative RF, ANA, Anti DNA and HCV with ESR 86 mm, Ig G 299 u/ml (normal above 700), Ig A 60 (normal above 70 u/ml), Ig M 490 u/ml (normal up to 230) but we repeat again the immunological profile with Ig M 470 u/ml, Ig A 68 u/ml Ig G 315 u/ml So the final diagnosis was hyper Ig M syndrome patient received aggressive antibiotics and advised for IVIG and vaccination (specially pneumococcal vaccine and annual influenza vaccine).

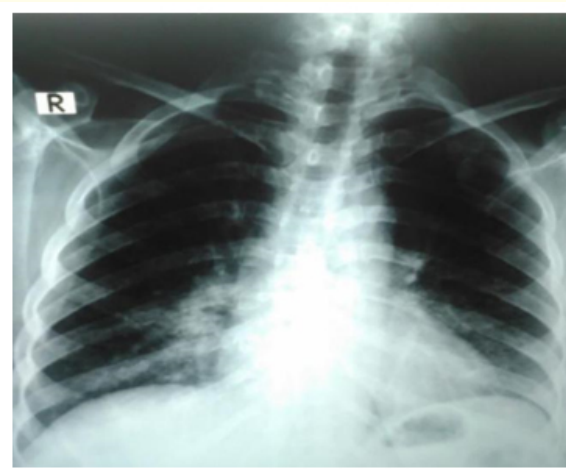


Figure 4: CXR with right lower and middle lung zone consolidation.

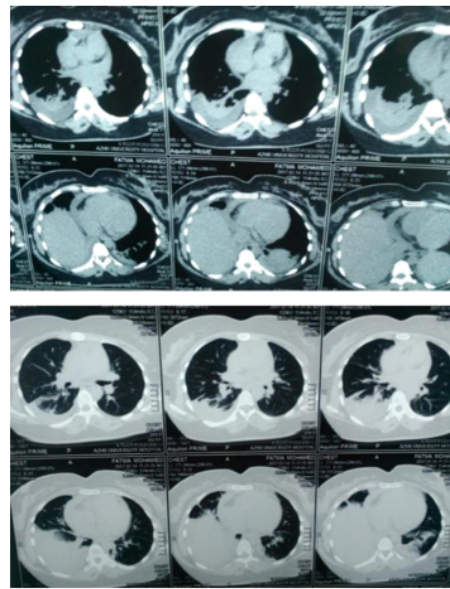


Figure 5: Representative slides from CT chest showed rt pleural effusion with consolidative collapse.

Discussion

Hyper IgM is a rare form of primary immunodeficiency characterized by normal or increased levels of serum IgM but deficiency of immunoglobulin G (IgG), immunoglobulin A (IgA), and immunoglobulin E (IgE) with poor antibody function due to defective class-switch recombination (CSR) [1-3]. This defective CSR that occurs in all types of hyper-IgM syndrome is due to intrinsic abnormalities in B cell or defects involving many of the immune cells [4,7].

It is a heterogeneous group of which the inherited X-linked trait, CD40L deficiency, is the most common form [8,9].

Clinical picture and severity of hyper IgM syndrome vary from case to case and become apparent mostly in the 1st or second year of life [10] and include chronic or protracted diarrhoea with failure to thrive and increased liability to recurrent sinopulmonary infections either caused by encapsulated bacteria or opportunistic infections like *Pneumocystis*, *Cryptosporidium*, and *Histoplasma* organisms, that may occur in the first few months of life [11-13].

Laboratory abnormalities typically seen in hyper-IgM syndrome include Markedly reduced serum levels of immunoglobulin G (IgG), immunoglobulin A (IgA), and immunoglobulin E (IgE) with normal or elevated levels of serum IgM (although the name hyper IgM however in newborns and young infants (< 4 months of age) their may be residual levels of serum IgG of maternal origin. Other findings may include lack of antibody response to protein and polysaccharide antigens, normal number of total B cells but markedly reduced number of memory (CD27+) B cells and absence of switched memory (IgD-CD27+) B cells. Also neutropenia, thrombocytopenia, and anemia are common. Lastly still the final sure confirmation of CD40L deficiency need mutation analysis [14-16].

The only available curative treatment for this syndrome is the allogeneic hematopoietic cell transplantation (HCT). Chronic neutropenia can be managed by recombinant granulocyte colony-stimulating factor (G-CSF).

Suitable antimicrobial therapy for infections and immunosuppressants for autoimmune disorders should be used. Prophylaxis for pneumonia secondary to *Pneumocystis jiroveci* and intravenous immune globulin (IVIG) by age six months to prevent overwhelming infection from encapsulated bacteria also implemented [5,6,16]. Our patient received one dose of IVIG monthly for 5 months although and patient progress smoothly.

Conclusion

Although it is a rare condition of primary immunodeficiency that can be easily missed in our daily practice, hyper IgM syndrome should be suspected in patients with recurrent infections or chronic infections specially with poor response to antibiotics as early diagnosis and treatment is crucial.

Bibliography

1. Notarangelo LD., *et al.* "Immunodeficiency with hyper-IgM (HIM)". *Immunodeficiency Review* 3 (1992): 101.
2. Winkelstein JA., *et al.* "The X-linked hyper-IgM syndrome: clinical and immunologic features of 79 patients". *Medicine (Baltimore)* 82 (2003): 373.
3. Primary Immunodeficiency. "National Institute of Child Health and Human Development (NICHD)" (2008).
4. Kracker S., *et al.* "Immunoglobulin class switch recombination deficiencies". *Clinical Immunology* 135 (2010): 193.
5. Levy J., *et al.* "Clinical spectrum of X-linked hyper IgM syndrome". *The Journal of Pediatrics* 131 (1997): 47-54.
6. Lee WI., *et al.* "Molecular analysis of a large cohort of patients with the hyper immunoglobulin M (IgM) syndrome". *Blood* 105 (2005): 1881.
7. Davies EG and Thrasher AJ. "Update on the hyper immunoglobulin M syndromes". *British Journal of Haematology* 149 (2010): 167.
8. Kutukculer N., *et al.* "Disseminated cryptosporidium infection in an infant with hyper-IgM syndrome caused by CD40 deficiency". *The Journal of Pediatrics* 142 (2003): 194.
9. Al-Saud BK., *et al.* "Clinical, immunological, and molecular characterization of hyper-IgM syndrome due to CD40 deficiency in eleven patients". *Journal of Clinical Immunology* 33 (2013): 1325.
10. Hyper IgM Immunodeficiency. Primary Immunodeficiency Resource Center (2008).
11. Winkelstein JA., *et al.* "The X-linked hyper-IgM syndrome: clinical and immunologic features of 79 patients". *Medicine (Baltimore)* 82 (2003): 373.
12. Aghamohammadi A., *et al.* "Clinical and laboratory findings in hyper-IgM syndrome with novel CD40L and AICDA mutations". *Journal of Clinical Immunology* 29 (2009): 769.
13. Agematsu K., *et al.* "Absence of IgD-CD27(+) memory B cell population in X-linked hyper-IgM syndrome". *Journal of Clinical Investigation* 102 (1998): 853.
14. Gilmour KC., *et al.* "Immunological and genetic analysis of 65 patients with a clinical suspicion of X linked hyper-IgM". *Molecular Pathology* 56 (2003): 256.
15. Seyama K., *et al.* "Mutations of the CD40 ligand gene and its effect on CD40 ligand expression in patients with X-linked hyper IgM syndrome". *Blood* 92 (1998): 2421.
16. Dogu F., *et al.* "CD40 ligand deficiency with grade III liver fibrosis, transplanted by a treosulphan-based conditioning regimen". *Experimental and Clinical Transplantation* 9 (2011): 349-352.

Volume 9 Issue 1 January 2020

© All rights reserved by Atef Elrifai and Ahmed Fayed.