

Hoover's Sign as a Useful Indicator to Locate the Lower Limit of the Pleural Effusion

René Agustín Flores-Franco* and Julio Cesar Corral-González

Department of Internal Medicine, Regional General Hospital "Dr. Salvador Zubirán Anchondo", Colón and Teófilo Borunda Av., Chihuahua, Chih., México

***Corresponding Author:** René Agustín Flores-Franco, Department of Internal Medicine, Regional General Hospital "Dr. Salvador Zubirán Anchondo", Colón and Teófilo Borunda Av., Chihuahua, Chih., México.

Received: June 29, 2021; **Published:** July 28, 2021

Abstract

Clinical skills tend to disappear as technological advances emerge. Although the Hoover sign has been widely studied in patients with COPD, in pleural effusion it has not been found to be of greater importance. Physiologically there may be similarities, seeing that the diaphragm suffers from the same anatomical and functional changes. Here we describe a possible clinical application as an aid to locate the lower limit of the pleural effusion and avoid injuring other organs during a thoracentesis.

Keywords: *Pleural Effusion; Physical Exam; Respiratory Diaphragm*

Introduction

Ultrasonography has indisputably become a useful resource in the evaluation and management of patients with pleural effusion. However, ultrasonography should also be considered as a resource that allows the clinician feedback on the effectiveness of their clinical skills. The advent of new technologies has allowed us to significantly increase not only the diagnostic precision, but also the safety of some procedures such as thoracentesis, seeing that the precise identification of the puncture site on the thoracic surface is essential to minimize the probability of an iatrogenic injury.

Physical examination is useful as a screening method for detecting the presence of pleural effusion, but already detected it, those signs obtained by physical examination to assess their anatomical limits, it seems that eventually could be forgotten or only to have a historical interest. Investigations focused on the accuracy of physical signs for the detection of a pleural effusion are almost completely limited to auscultatory percussion [1]. Within the physical examination, in the inspecting of a pleural effusion, an asymmetry in the chest expansion is described with a sensitivity of 74% and a specificity of 91% [1]. If pleural pressure increases on the effusion side, that hemithorax may be larger and the concavity of the intercostal spaces will decrease [2].

In this sense, our daily practice in various pleural pathologies has allowed us to rescue a physical sign that has been very useful, despite having an ultrasonography evaluation. Locating the lower limit of a pleural effusion is not easy using only our senses, however, considering that the diaphragm is the limiting anatomical structure, the modifications in its position and function caused by a large pleural effusion could make a Hoover sign evident similar to that described in patients with chronic obstructive pulmonary disease (COPD) [3]. Hoover's sign is an easily recognizable physical finding with high inter-observer agreement which consists of a paradoxical inspiratory movement of the lateral costal margin and traditionally has been attributed to direct traction of the flattened diaphragm on the lateral costal margins. The diaphragmatic projections on the lateral and posterior thoracic-abdominal wall in addition to the paradoxical lower costal displacement also may be apparent inspiratory "sags" of the soft tissues of the subcostal area. In presence of pleural effusion, this

observation was also described by Bray and Wilson [4] almost 100 years ago and more recently we have confirmed and documented it in a patient with a certain degree of obesity [5]. If pleural pressure exerts some influence on the sign of Hoover, as it has been described in COPD, in the presence of pleural effusion the situation might be similar. Troyer and Wilson [6] proposed the three-compartment model to explain the mechanics of the chest wall. Under normal conditions during diaphragmatic contraction, as pleural pressure falls, a caudal and inward force is exerted on the entire rib cage. Lower ribs, through the diaphragmatic insertions and apposition zone between the diaphragm and ribs, the diaphragm exerts a force cranially and outward. In the presence of hyperinflation, the area of apposition decreases and pleural pressure becomes the dominant force on the lower ribs, thus reversing their movement in a caudal and inward direction. In animal models, it has been shown that the main adverse effect of a pleural effusion on the diaphragm, similar to what happens with pulmonary hyperinflation, is to decrease the length of its muscle surface and thus its contraction force [7]. As being reduced apposition zone, the lower ribs would also not be influenced by the intra-abdominal "expander" pressure as would normally be the case. Recently Aguilera-Garcia, *et al.* in 28 patients with large pleural effusions of various etiologies, documented by manometry inspiratory pleural pressures of -3 to -13 cm H₂O [8]. Unfortunately, one of the limitations of the study was that the configuration of the chest wall was not explored, so we do not know at which inspiratory pleural pressure the Hoover sign could become evident. On the other hand, the Hoover sign could be related more to the pleural pressure swing and respiratory drive than to the inspiratory pleural pressure.

Although Hoover's sign could be considered a curiosity rather than a significant diagnostic marker [9], its presence has been associated with a greater number of hospitalizations in COPD patients and its frequency increases with the severity of the airflow obstruction [10]. Regarding pleural effusion, the Hoover sign has not been given any importance. During the assessment of the appropriate site for a closed pleural biopsy in an old woman with a narrow chest, we were surprised by the usefulness of the Hoover sign as it coincided with the lower limit of a large pleural effusion localized by ultrasonography (Figure 1). Properly identifying the lower limit of a pleural effusion is important since when performing a thoracentesis we must be careful to move away from its upper limit and thus reduce the risk of pneumothorax. Some recommend insert the needle one or two intercostal spaces below the upper limit of the pleural effusion, and to avoid injury to intra-abdominal organs, such puncture should not be performed below the ninth costal arch [11]. In our experience, in combination with the findings provided in the chest radiograph, the unilateral Hoover sign associated with other signs such as skodism, dullness to percussion and a decrease in underlying tactile fremitus, allows us to increase our confidence to perform a thoracentesis in safely even without the help of ultrasonography.

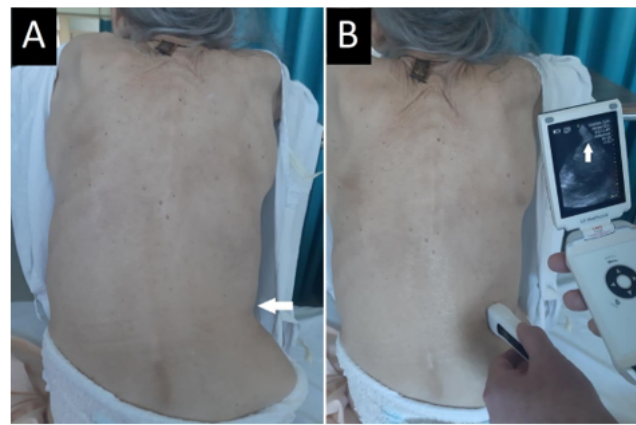


Figure 1: Hoover's sign in a patient with a right malignant pleural effusion. A: Paradoxical retraction of the lower costal and right subcostal area is observed during inspiration (white arrow). B: A portable ultrasonography confirms the presence of the lower limit of the pleural effusion and the hemidiaphragm at this level (white arrow).

Conclusion

Although there is a powerful tendency to substitute some clinical skills, we must strengthen those that could allow us to dispense with expensive technology, and perform invasive procedures with acceptable safety, especially in an emergency or scarce-resource situation. The physical properties of a pleural effusion and of the retroperitoneum are very similar; here the presence of the Hoover sign would allow them to be delimited.

Conflict of Interest

The authors declare that there have not any financial interest or any conflict of interest exists.

Bibliography

1. Kalantri S., *et al.* "Accuracy and reliability of physical signs in the diagnosis of pleural effusion". *Respiratory Medicine* 101.3 (2007): 431-438.
2. Wong CL., *et al.* "Does this patient have a pleural effusion?" *The Journal of the American Medical Association* 301.3 (2009): 309-317.
3. Mulvey RB. "The effects of pleural fluid on the diaphragm". *Radiology* 84.6 (1965):1080-1086.
4. Bray HA and Wilson JL. "The excursion of the costal margins in health and in disease". *Archives of Internal Medicine* 43.2 (1929): 187-195.
5. Flores-Franco RA and Onofre-Fernández M. "Hoover's sign in non-obstructive respiratory disease" (2010).
6. Troyer AD and Wilson TA. "Action of the diaphragm on the rib cage". *Journal of Applied Physiology* 121.2 (1985): 391-400.
7. Troyer AD., *et al.* "Mechanics of the canine diaphragm in pleural effusion". *Journal of Applied Physiology* 113.5 (2012): 785-790.
8. Aguilera-Garcia Y., *et al.* "Assessment of diaphragm function and pleural pressures during thoracentesis". *Chest* 157.1 (2020): 205-211.
9. Wilson TA. "Compartmental models of the chest wall and the origin of Hoover's sign". *Respiratory Physiology and Neurobiology* 210 (2015): 23-29.
10. Garcia-Pachon E and Padilla-Navas I. "Clinical implications of Hoover's sig in chronic obstructive pulmonary disease". *European Journal of Internal Medicine* 15.1 (2004): 50-53.
11. Thomsen TW., *et al.* "Thoracentesis". *The New England Journal of Medicine* 355 (2006): e16.

Volume 10 Issue 8 August 2021

©All rights reserved by René Agustín Flores-Franco and Julio Cesar Corral-González.