

COVID19: Temporal CXR Changes and VATS Scoring of COVID Chest X Rays-An Easy Tool to Understand the Duration of Disease, Progress and Prognosis and Intensifying Anti-COVID Management

Mayank Vats^{1*} and Spraha Vats²

¹Senior Specialist, Pulmonologist, Interventional Pulmonologist, Intensivist and Sleep Physician, Rashid Hospital, Dubai, UAE

²DPS, Dubai, UAE

***Corresponding Author:** Mayank Vats, Senior Specialist, Pulmonologist, Interventional Pulmonologist, Intensivist and Sleep Physician, Rashid Hospital, Dubai, UAE.

Received: May 24, 2020; **Published:** June 11, 2020

COVID 19 pandemic which started in china has involved more than 5.3 Million cases globally with death toll reaching to 342,242 worldwide till 24 May 2020 and globally the cost of health care including the prevention and treatment of COVID has gone beyond control and majority of countries are facing economic problems and shortage of funds in health care delivery.

We are well aware with our experience with COVID that infection goes through different phases and behaves totally unpredictably hence in order to anticipate the clinical and radiological course of disease and to optimize treatment regime as per the clinical radiological severity, we reviewed thousands of COVID suspicious or COVID confirmed cases to come out with an easy scoring system to categorize patients and to decide resource efficient lines of management as well because it is not possible to carry on CT SCAN in all patients considering multiple issues involved in the regular CT scan including cost, transport of patient, spread of infection in the hospital and CT department hence we developed a very cost effective and practical scoring system based on the preliminary investigation chest x-ray to assess many factors through this simple radiological investigation as would be described in the text below.

Four stages on CXR can be considered based on the clinical condition, time of onset and severity of COVID 19 disease and they usually correlate very well with the time duration and hence good temporal relation between CXR and COVID 19. For the easy understanding, we have considered the conventional standard definition for defining the upper, mid and lower zones in CXR as below:

1. Upper zone: Area of lung occupying up to anterior end of first 2 ribs.
2. Mid zone: Area of lung occupying up to anterior end of 2 ribs to 4 ribs.
3. Lower zone: Area of lung occupying from anterior end of 4th ribs till diaphragm.

Initial stage (0- 4 days): Normal CXR (40-50% of patients) or very minimal basal patchy infiltrates involving less than single lung zone or GGO only, these patients have tendency to either way, worsening or improvement depending upon the immunity and the comorbid conditions and early start of treatment.

Progressive stage (5 - 7 days): Increases in the basal patchy infiltrates involving the lower and middle zone of the lungs (\leq 50% of lung zone) and development of VATS reverse pulmonary edema/increased GGO or development of ARDS.

Advanced stage (1 - 2 weeks): Worsening of inflammatory/hypercoagulability/macrothrombusi’s and macro thrombosis leading to dense consolidation or extensive patch consolidation involving more than $\geq 50\%$ of lung zone, more confluence of the previously ill-defined patchy infiltrates and worsening of VATS’S reverse pulmonary edema also called physiologically as cytokine storm.

Resolution stage (> 2 weeks): Once the disease is controlled by the innate immunity of host or the medicines then there are gradual improvement in the clinical condition and radiological picture of patient, although radiological clearance always lags behind because it takes time for the inflammation and thrombosis to resolve. Simultaneously pts may develop fibrotic process which is usually minimal and improves with the improvement and clearance of eth macro thrombosis and macrothrombusi’s and with an improvement in the disease course, and these fibrous abnormalities also gets resolve in less than 2 months or earlier.

Based on the presenting radiological finding and after having extensive research on the radiological findings and the corresponding clinical profile of patient and their follow up in to worsening or improvement we planned to divide the level of lung involvement base on the area of both lungs zones involved and to develop a easy to remember grading system which would help in categorizing the severity of illness and possibly prognosis as well as mentioned below with the corresponding radiological findings as well.

Grade 0: CXR showing lobar consolidation and 2 consecutive nasopharyngeal RT PCR but symptoms s/o of community acquired pneumonia and no history of contact with COVID or Corona positive patient present (Figure 1).

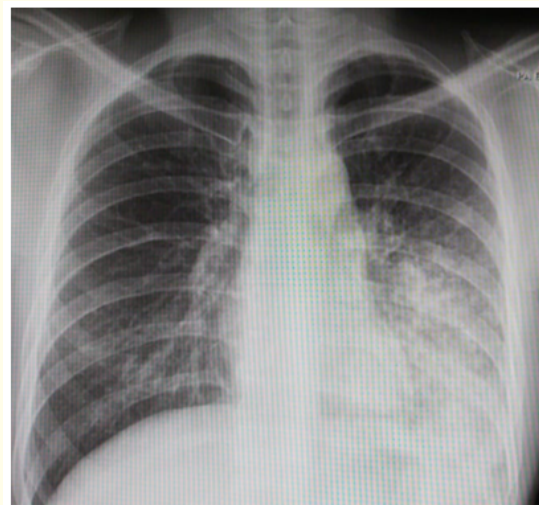


Figure 1: Left Lower lobar consolidation, COVID negative.

Grade 1: Normal CXR with COVID negative on 2 consecutive nasopharyngeal RT PCR but no symptoms s/o of COVID and history of contact with COVID or Corona positive patient present NB: Negative for pneumonia implies that there are no parenchymal abnormalities that could be attributable to infection. Specifically, GGO and consolidation are absent. Importantly, there may be no findings on CT early in COVID-19 (Figure 2).

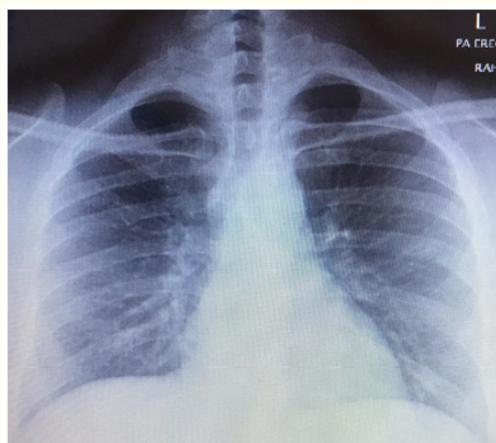


Figure 2: Normal CXR with COVID negative with contact history.

Grade 2: Normal CXR with COVID positive on either of 2 or 3 consecutive nasopharyngeal RT PCR but symptoms s/o of COVID and history of contact with COVID or Corona positive patient present (Grade 2) (Figure 3).

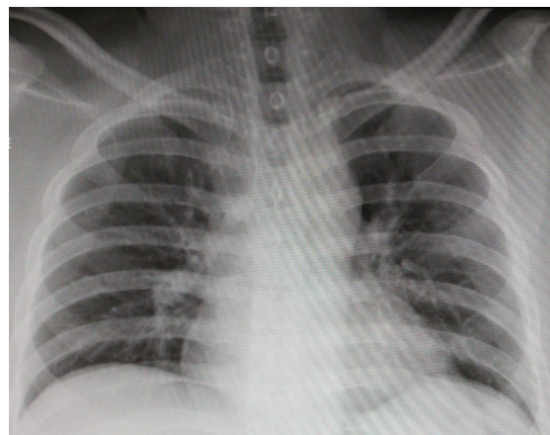


Figure 3: Normal CXR with COVID positive.

Grade 3: Few ill-defined infiltrates, primary located in the basal region and in lower zone, no major confluence of infiltrates on CXR with COVID positive on 2 consecutive nasopharyngeal RT PCR but symptoms s/o of COVID and history of contact with COVID or Corona positive patient present (Grade 3) (Figure 4).

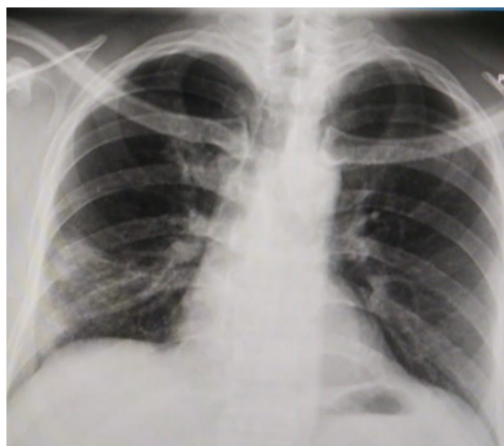

Figure 4: CXR suggestive of COVID, RT PCR negative.

Grade 4: Bilateral ill-defined infiltrates, primary located in the mid and in lower zone, no major confluence of infiltrates on CXR with COVID positive on 2 consecutive nasopharyngeal RT PCR but symptoms s/o of COVID and history of contact with COVID or Corona positive patient present (Grade 4) (Figure 5).

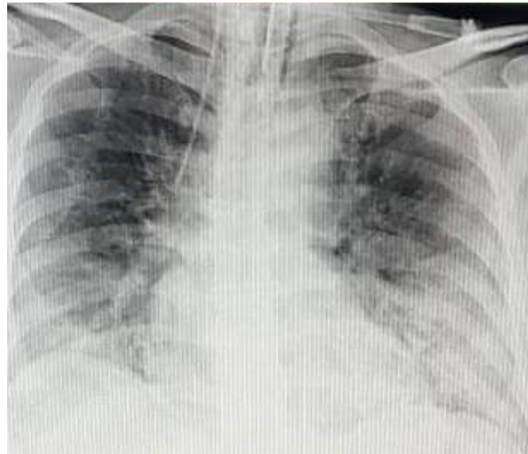

Figure 5: Bilateral ill-defined infiltrates, primary located in the mid and in lower zone.

Grade 5: Well defined infiltrates, primary located in the mid/lower zone, major confluence of infiltrates primarily in peripheral region with sparing of, perihilar area, bases and apex, VATS reverse pulmonary edema on CXR with COVID positive on 2 consecutive nasopharyngeal RT PCR but symptoms s/o of COVID and history of contact with COVID or Corona positive patient present (Grade 5) (Figure 6).

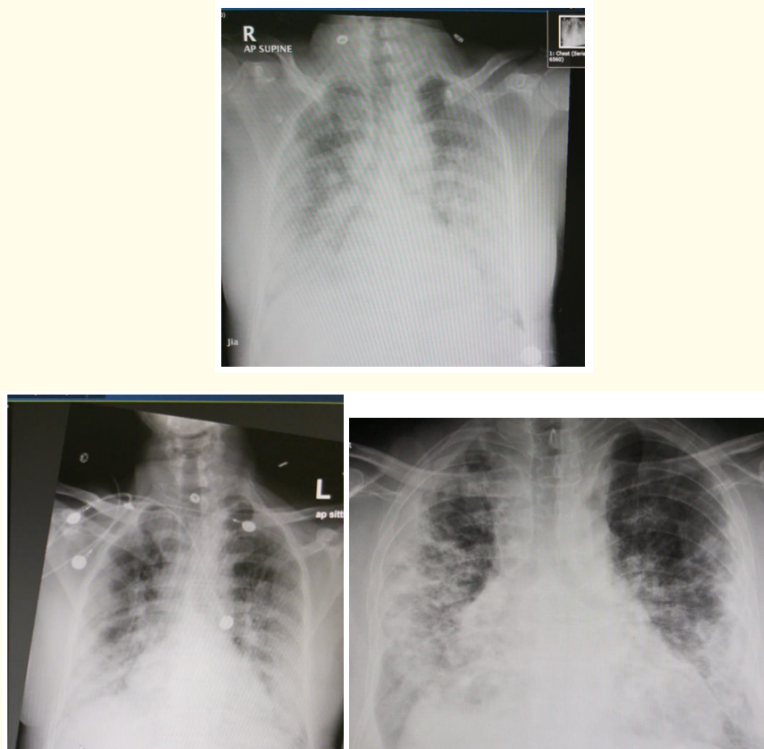


Figure 6A-6C: Mid/lower zone, major confluence of infiltrates primarily in peripheral region with sparing of, perihilar area, bases and apex, VATS reverse pulmonary edema sign.

Grade 6: Well defined infiltrates, primary located in the mid and in lower zone, major confluence of infiltrates primarily in the peripheral region with spreading toward hila, near complete obscuration of cardia margins and involving the bases and apex on CXR with COVID positive on 2 consecutive nasopharyngeal RT PCR but symptoms s/o of COVID and history of contact with COVID or Corona positive patient present (Grade 6) (Figure 7).

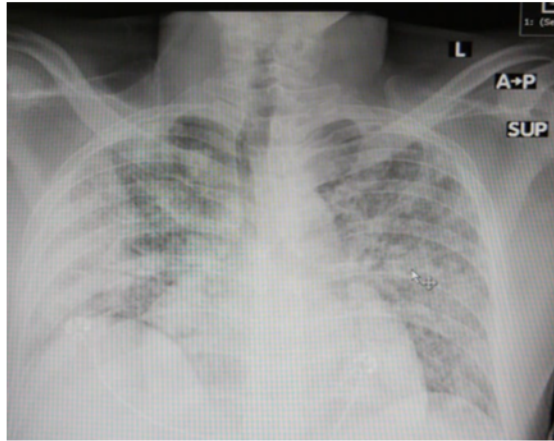


Figure 7: Well defined infiltrates, primary located in the mid and in lower zone, major confluence of infiltrates primarily in the peripheral region with spreading toward hila.

Grade 7: Well defined/ill-defined infiltrates, extensively involving entire lung zones, major confluence of infiltrates primarily in the peripheral region, near complete obscuration of cardia margins and involving the bases and apex on CXR suggestive of ARDS with COVID positive on 2 consecutive nasopharyngeal RT PCR but symptoms s/o of COVID and history of contact with COVID or Corona positive patient present (Grade 7) (Figure 8).

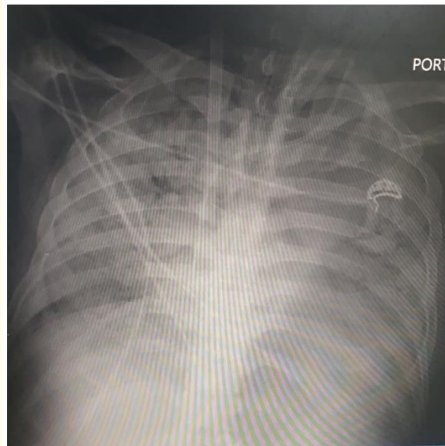


Figure 8: Acute respiratory distress syndrome, diffuse heterogenous involvement of both lungs and sever hypoxia with cytokine storm.

Conversely, CT has been reported to be more sensitive than RT-PCR earlier in the course of the disease, although this result may change with local RT-PCR test characteristics.

Pros, Cons and Limitations

This simple CXR scoring system is planned for the easy and cost effective measure to detect the possibility of COVID 19 infection with due consideration of the clinical history, symptoms and history of contact with COVID or Corona positive patient. There are compelling arguments both for and against the use of standardized reporting language in describing CT findings potentially attributable to COVID-19. Most current guidelines does not recommend routine use of screening CT for COVID-19 just for the diagnostic purpose considering the cost, manpower and the risk of spreading the infection in whole hospital and overwhelmed CT scan facilities in most of countries globally Hence VATS scoring system could be easily used as reasonably reliable tool for diagnosing and starting empiric treatment of highly suspected corona/covid patient and to intensify their management based on clinical condition and radiological worsening, however CT may be requested for assistance in alternative diagnosis or diagnosing correctable complication of disease viz pneumothorax, pleural effusion or empyema, to name a few particularly if RT-PCR is not readily available.

Pros: Without the direct communication with the clinician or expert, radiologists may be left with uncertainty to define the presence, absence, or likelihood of COVID-19 when confronted with this as a specific indication or as an incidental finding. Most of the radiologist overread the CXR considering the COVID pandemic because of limited information given to them while ordering the CXR or CT scan hence its imperative that clinician should give them adequate information about the patients and his possible differential diagnosis in order to avoid over reading or radiological bias. This one to one communication between clinical and radiologist would result in standardized reporting provide guidance and confidence to radiologists as well as reduced reporting variability and could be helpful for utilizing data for future educational, research, and quality improvement purposes especially in resources limited countries. In addition, standardized radiology reports combined with clinical assessment may enable future care pathways to determine which patients may preferentially undergo RT-PCR should testing capacity be exceeded. Initial RT-PCR testing may also be negative, and typical imaging findings may encourage repeat testing.

Cons

The true sensitivity and specificity of CT for COVID-19 remains relatively unknown varying between 60-83% of the time based on typical CT imaging features. However, the results of this study must be evaluated cautiously as all of the COVID-19 cases ct scan findings were from China and most of the control cases from USA. Additionally, the sensitivity and specificity will become further down as the control cases included a low proportion of influenza-A, which is the major viral pneumonia that must be differentiated from COVID-19 during the winter and spring months across the northern hemisphere. Reporting “atypical features” may result in false negative cases, and the risk of missing COVID-19 can have broad implications. Ordering providers may also feel that having “COVID-19” or “coronavirus” documented in a radiology report constrains their clinical decision making and treatment options. This concern is less relevant in PUIs, as clinical suspicion already exists. However, difficulties may arise in patients with findings suggestive of COVID-19 that are incidentally detected. Direct communication with the referring provider about the likelihood of COVID-19 is recommended to avoid surprising providers and patients. We again emphasize that as an incidental finding, particularly with indeterminate or atypical features, “viral pneumonia” may be preferable to “COVID-19” or “coronavirus”.

Limitations

We anticipate cases with mixed imaging findings, that is, those that have both typical and atypical imaging features for COVID-19. Recent analysis suggests that over 20% of patients with COVID-19 may have coexistent infections complicating the categorization of

imaging observations. The radiologist will have to determine whether or not these findings are part of the same process or are unrelated. For example, a hospitalized patient undergoing chest CT for fever could have lower lobe tree-in-bud opacities as well as peripheral GGO, which could reflect aspiration superimposed on viral pneumonia. It is also possible that atypical features such as lobar consolidation may reflect a secondary bacterial pneumonia even in patients who test positive for COVID-19. Available evidence is still limited concerning the appearance of COVID-19 in the presence of secondary disease processes such as coexistent infections and aspiration. In scenarios such as these, discussion with the treating team would be prudent.

Imaging appearances in the standardized reporting language are based upon available literature at the time of writing in March 2020, noting the retrospective nature of many reports, including biases related to patient selection in cohort studies, examination timing, and other potential confounders. As radiologists' experience with COVID-19 increases, our categorization of these findings as typical, indeterminate, or atypical may evolve.

We are continuing our this follow up and hence it's a preliminary date which we are presenting and soon we will come up with a review of records of large numbers of patients validating Vats scoring system of CXR. In general More extensive disease, more severe would be hypoxia, and more dismal prognosis, but only after review of large numbers of patients we would be able to conclude finally.

Conclusion

We propose CXR categories (VATS scoring system of COVID CXR) in an effort for the standardized CXR reporting of COVID-19 based on current literature and our vast experience We acknowledge that for patients with cxr findings that could be attributed "viral pneumonia" but considering this global pandemic all CXR findings with clinical history should be considered as COVID until proved otherwise. Consensus between local imaging and clinical providers is essential to establish an agreed-upon approach.

CXR is the first and easily available and cost effective tool for the assessment of the radiological infiltrates in majority of patients although, in initial cases with grade 0 or grade 1 it may be missed due to interobserver intra-observer variability and or technical quality of CXR film.

At present time, CT screening for the detection of COVID-19 is not recommended by most radiological societies although it has been extensively studied in most of the affected countries (China) and guidelines has been issued as well, but for the resource limited countries and for huge numbers of patients with overwhelmed health care system, VATS grading of radiological severity could be an easily used tool to predict the probability and severity and the intensity of management plans and the prognosis as well. Although this scoring system need to be validated in long term and large number of patients to have more accuracy, predictability, sensitivity, and specificity but till then we can definitely employ in our daily clinical practise to assess the COVID pts severity assessment. However, we anticipate that the use of CT in clinical management as well as incidental findings potentially attributable to COVID-19 would be more accurately detected by CT scan. We believe that Clear and frequent communication among clinicians and radiologists, is imperative to improving patient care during this pandemic. We believe it important to provide radiologists and referring providers guidance and confidence in reporting these findings and a more consistent framework to improve clarity.

This easy, fast and cost effective grading system which would help in estimating the approximate duration of illness, categorizing the severity of illness and hence safe disposal of pt/appropriate level of care in isolation (in regular ward, low dependency or high dependency or ICU) and define the appropriate treatment and possibly prognosis as well as mentioned with the corresponding radiological findings as well.

Acknowledgement

I convey my heartfelt thanks to Spraha Vats, who is a brilliant and extraordinary student of DPS school Dubai help me to prepare the manuscripts including drafting, grammatical assistance and picture work of CXR and search of literature as well.

Volume 9 Issue 7 July 2020

©All rights reserved by Mayank Vats and Spraha Vats.