

## **Technology in Medicine: The First Report of a Printed Three-Dimensional Model of a Lung with Cystic Adenomatoid Malformation**

**Altair da Silva Costa Jr\***

*Doctor of Thoracic Surgery, Department of Surgery, Federal University of São Paulo (UNIFESP), Paulista School of Medicine, Hospital São Paulo - University Hospital, São Paulo, Brazil*

**\*Corresponding Author:** Altair da Silva Costa Jr, Doctor of Thoracic Surgery, Department of Surgery, Federal University of São Paulo (UNIFESP), Paulista School of Medicine, Hospital São Paulo - University Hospital, São Paulo, Brazil.

**Received:** January 31, 2020; **Published:** October 31, 2020

### **Abstract**

Three-dimensional printing is recognized as a technique that can transform teaching into surgery and surgical practice. The techniques of processing and segmentation of medical images allow the creation of real anatomical models based on patient data. With rapid prototyping and additive manufacturing it is possible to produce a real object from any organ of the patient, an authentic model of the disease being treated. The DICOM files are transformed into STL, a set of stereolithographic data, ready for processing, prototyping, extrusion, cutting, smoothing and finishing. The entire physical printing process takes about 12 hours, depending on the size and detail of the object.

The reconstructed three-dimensional models, virtual or printed, allow the reproduction of sophisticated anatomical structures that can be used to facilitate the anatomical study and the teaching, based on real examples. It also could be used for surgical planning and the development of new techniques or devices. We are facing a revolution.

The aim of this article is to show the first three-dimensional printed model of a lung with cystic adenomatoid malformation.

Ultramini: Three-dimensional printing is recognized as a technique that can transform surgical practice and teaching into surgery. The techniques of processing and segmentation of medical images allow the creation of real anatomical models based on patient data. With rapid prototyping and additive manufacturing it is possible to produce a real object from any organ of the patient, an authentic model of the disease being treated. The reconstructed three-dimensional models, virtual or printed, allow the reproduction

**Keywords:** *Three-Dimensional Printing; Lung; Cystic Adenomatoid Malformation*

### **Introduction**

Three-dimensional printing is recognized as a technique that can transform teaching in surgery and operative practice [1]. Through the technologies in three dimensions, it is possible the rapid conversion of tomographic images into reliable anatomical reconstructions or even physical objects [1,2].

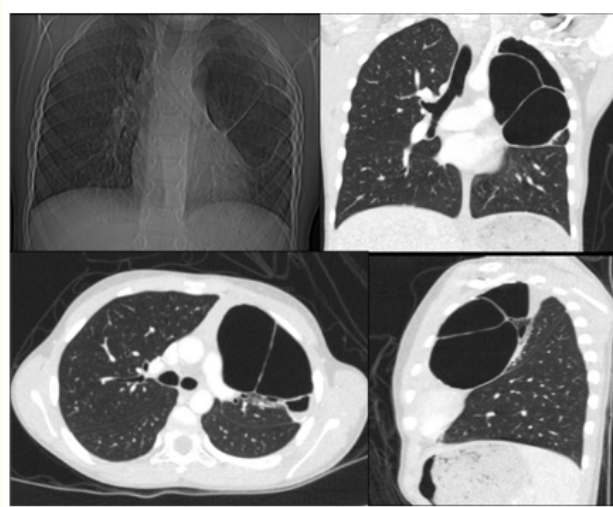
The techniques of processing and segmentation of medical images allow the creation of real anatomical models based on patient data. With rapid prototyping and additive manufacturing it is possible to produce a real object from any organ of the patient, an authentic model of the disease to be treated [1-4]. For this, a computerized tomography with thin sections, below 3 mm, is necessary to generate adequate images. Computer-aided drawing programs require many images, over 200 slices in DICOM files, for segmentation and

production of a three-dimensional polygon mesh with quality [1,4,5]. Tests with less than 100 images or with slices around 10 mm, generate a lot of interference and the reconstruction becomes coarse, with a poor quality [1,5]. DICOM files are transformed into STL, a set of stereolithographic data, ready for processing, prototyping, extrusion, cutting, smoothing and finishing. The entire physical printing process takes about 12 hours, depending on the size and detail of the object [1,2,5].

The reconstructed three-dimensional models, virtual or printed, allow the reproduction of sophisticated anatomical structures that can be used to facilitate the anatomical study and the teaching, based on real examples. It also could be used for surgical planning and the development of new techniques or devices. We are facing a revolution [1,5,6].


The aim of this article is to show the process for the manufacture of the first three-dimensional printed model of a lung with cystic adenomatoid malformation.

We report an 8-year-old patient with a cystic adenomatoid malformation in the left upper lobe. Through the images of the conventional tomography, it was possible to visualize the anatomical alterations in other planes: axial, coronal and sagittal (Figure 1).



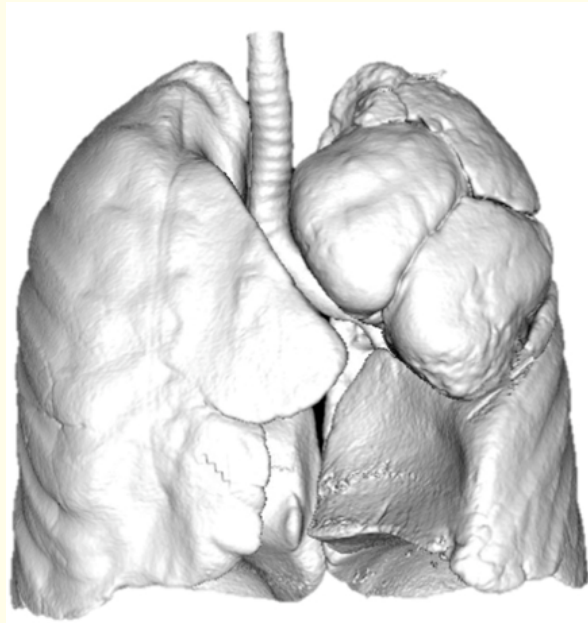
**Figure 1:** Chest x-ray and tomography with cystic adenomatoid malformation in the left upper lobe.

As the aid of an image-processing program, we perform the 3D reconstruction (Figure 2).



**Figure 2:** 3D reconstruction cystic adenomatoid malformation in the left upper lobe.

These images were also segmented and an STL stereolithographic data file was generated for 3D physical printing with different resin colors, Vero clear, Vero pure white and Tango (Figure 3 and 4). The printout of the piece took about 12 hours with an Objet260 Connex3 (Stratasys). It cost US\$1,300.00.



**Figure 3:** Segmentation and model in STL.



**Figure 4:** Cystic adenomatoid malformation in the left upper lobe printed in 3D.

### Potential opportunities

The three main fields for the application of 3D technology in medicine are: medical education, for both undergraduate and graduate; education for the patient; planning and simulation in surgery [1,7].

### Medical education

Basic human anatomy, a central aspect of medical education, has traditionally been taught through cadaver dissection and study of textbooks. Medical imaging, however, has become an increasingly important tool in teaching anatomy. 3D technology has the potential to further enhance the virtual anatomy and adds value with the inclusion of more realistic images as they are based on patient real exams [1,2,5,7]. It is possible to reconstruct and print not only the normal anatomy but also the most diverse diseases. Although cadaver dissection is likely to remain an integral part of the medical education experience, students will be able to interact with the anatomy of several patients and countless disease at any time and place at a 3D technology workstation [7]. It is easier to explain about lung malformation with a 3D printed model.

### Patient education

The 3D technology can improve communication and doctor-patient relationships, with clarity by the quality of the images. "A picture is worth a thousand words". The 3D technology enables physicians and surgeons to illustrate to patients the underlying pathological features of their disease and to demonstrate possible treatments. However, the interpretation of traditional plane and transverse images in gray scale is rarely intuitive for patients [1,5,7]. The images generated by 3D technology are similar to and reliable to the real organ. Compared with traditional medical imaging, 3D technology can improve patient understanding, the involvement in their disease and treatment plan [3,7].

### Surgical planning

Another obvious benefit is preoperative planning and pre-intervention simulations. The treatment planning based on images and models produced by 3D technology is a revolution in the operative field [1,2,8,9]. Increasingly, specialties adopt and implement this feature as part of their routine [3,6-8]. As we know, surgical planning is performed by the mental integration of multiple images and depends on the experience of the surgeon. Newly trained physicians present difficulties in understanding anatomical changes in three dimensions only by the evaluation of a common tomography [1,7]. The 3D technology, however, generates a highly realistic representation of the structures of interest with a single modality. The manipulation of images allows the visualization of anatomical details through different perspectives. The more realistic representation of images than those traditionally obtained, transverse or plane, should be closer to what doctors see in the live operation. Through the 3D technology is possibly to occur less impact from unexpected accidental findings and anatomical variants [7].

### Limitations and alternative strategies

The current challenges of 3D technology include source image quality, cost, time and materials [1,2,5,7]. Investment in a 3D anatomical lab requires equipment, segmentation software and trained support personnel. Depending on the complexity of the case, segmentation and processing may take a few hours to complete. In addition, it has the possibility to produce real objects with 3D printing technology, adding at cost the 3D printer, with options of materials and colors [1,2,7].

Three-dimensional reconstruction techniques play an important role in different medical areas. As an alternative, the cinematic rendering mode, a new 3D reconstruction technique, provides a more realistic representation of the image data and may have the potential

to further improve diagnostic utility as compared to 3D images [7]. This model produces a more natural, accurate and better perception of shape and depth. This new technique has the potential to create a new paradigm in the interpretation of imaging exams [7]. New studies are needed, however, to determine the possible diagnostic utility of cinematic rendering compared to 3D and cross-sectional images. In this field, we could measure how it help surgical planning by randomizing a group of patients who had a 3D model done and compare it to a group of patients who did not. Then show how the operation went faster or safer, or how the student or resident understood of that needed to be done.

### **Conclusion**

It is possible to facilitate learning and teaching through 3D technology, as well as print the diseased organ with a real physical object. For the future, this is an interesting technology with the ability to radically change teaching in medicine and revolutionize modern surgery.

### **Bibliography**

1. Malik HH, *et al.* "Three-dimensional printing in surgery: a review of current surgical applications". *Journal of Surgical Research* 199.2 (2015): 512-522.
2. Kurenov SN, *et al.* "Three-dimensional printing to facilitate anatomic study, device development, simulation, and planning in thoracic surgery". *The Journal of Thoracic and Cardiovascular Surgery* 149.4 (2015): 973-979.e1.
3. Matsumoto JS, *et al.* "3-Dimensional Printed Anatomic Models as Planning Aids in Complex Oncology Surgery". *JAMA Oncology* 2.9 (2016): 1121-1122.
4. Rybicki FJ. "The art of medicine Medical 3D printing and the physician artist". *The Lancet* 391.10121 (2018): 651-652.
5. Takagishi K and Umezaki S. "Development of the Improving Process for the 3D Printed Structure". *Nature* 7 (2016): 39852.
6. Colaco M, *et al.* "The potential of 3D printing in urological research and patient care". *Nature* 15.4 (2018): 213-221.
7. Eid M, *et al.* "Cinematic Rendering in CT: A Novel, Lifelike 3D Visualization Technique". *American Journal of Roentgenology* 209.2 (2017): 370-379.
8. Li L, *et al.* "In situ repair of bone and cartilage defects using 3D scanning and 3D printing". *Nature* 7.1 (2017): 9416.
9. Lee N. "The Lancet Technology: 3D printing for instruments, models, and organs?" *The Lancet* 388.10052 (2016): 1368.

**Volume 9 Issue 11 November 2020**

**© All rights reserved by Altair da Silva Costa Jr.**