

## Pleuritic Chest Pain: Heart-Related or Lung-Related Cause in Patient with Congestive Heart Failure Detected by B-Mode Abdominal Ultrasonography

Petar Avramovski<sup>1,2\*</sup>, Domnika Rajchanovska<sup>2</sup>, Tanja Jovanovska<sup>2</sup>, Veselin Talevski<sup>2</sup>, Maja Avramovska<sup>3</sup>, Elizabeta Ivanovska<sup>4</sup>, Slavica Nastevska<sup>4</sup>, Mira Mladenovska<sup>5</sup>, Vesna Shiklovska<sup>6</sup>, Nikola Siljanovski<sup>7</sup> and Emilija Sikole<sup>8</sup>

<sup>1</sup>Primarius, Department of Internal Medicine, Clinical Hospital - Bitola, North Macedonia

<sup>2</sup>Professor, Higher Medical School - Bitola, St. Clement of Ohrid University of Bitola, North Macedonia

<sup>3</sup>PhD Candidate, Department of Gynecology and Obstetrics, Clinical Hospital - Bitola, North Macedonia

<sup>4</sup>MD, Department of Pulmonology, Clinical Hospital - Bitola, North Macedonia

<sup>5</sup>MD, Department of Diabetology, Clinical Hospital - Bitola, North Macedonia

<sup>6</sup>MD, Department of Radiology, Clinical Hospital - Bitola, North Macedonia

<sup>7</sup>MD, University Clinic of Radiology, Faculty of Medicine - Skopje, University SS, Cyril and Methodius, Skopje, North Macedonia

<sup>8</sup>MD, Institute of Preclinical and Clinical Pharmacology with Toxicology, Faculty of Medicine - Skopje, University SS, Cyril and Methodius, Skopje, North Macedonia

**\*Corresponding Author:** Petar Avramovski, Primarius, Department of Internal Medicine, Clinical Hospital - Bitola, North Macedonia.

**Received:** February 19, 2020; **Published:** April 17, 2020

### Abstract

Chest pain represents a diagnostic challenge, as it is a common symptom of pleuritis and a broad spectrum of diseases. Chest X-rays is the first imaging approach regarding a pleural effusion, but the computed tomography (CT) is with greater accuracy. The combined use of CT and B-mode ultrasonography increases diagnostic accuracy significantly. Male 76 age patient with burning chest pain, diabetic, formerly treated for decompensated heart failure and right-sided bronchopneumonia, was admitted to ultrasonography ambulance. We found massive anechoic fluid in triangle form below the diaphragm and signs of parenchymal consolidation, by B-mode ultrasonography. Chest X-ray showed an excessive accumulation of fluid in the pleural space (pleural effusion). CT scan shows massive pleural effusion, too. We found elevated liver enzymes, hyperbilirubinemia, elevated inflammation markers (C-reactive protein and granulocytes) and elevated brain natriuretic peptide (BNP). Abdominal B-mode ultrasonography is a powerful diagnostic tool for detecting heart-related or lung-related pleuritic chest pain and also liver congestion.

**Keywords:** Pleuritic Chest Pain; Congestive Heart Failure; B-Mode Abdominal Ultrasonography

### Introduction

Pleuritic chest pain is characterized by sudden and intense sharp, stabbing, or burning pain in the chest when inhaling and exhaling [1]. Non-cardiac chest pain represents a diagnostic challenge, as it is a common symptom of a broad spectrum of diseases [2]. Using appropriate clinical approach is helpful to make a differential diagnosis of pleuritic chest pain, according different many etiologies: congestive heart failure, pericarditis, pleuritis, chronic obstructive pulmonary disease, hemothorax, pneumothorax, pleuropneumonia, myocardial infarction and others life-threatening disease. Lethal causes of pleuritic chest pain (e.g. infection, malignancy, inflammatory processes) progress over hours to days or weeks [1,3].

Chest X-ray is usually the first imaging approach regarding a pleural effusion with detection threshold of 200 - 300 mL of fluid in anterior - posterior projection [4,5]. The most accurate and most used imaging techniques for diagnosing pleuritis are computed tomography

**Citation:** Petar Avramovski., et al. "Pleuritic Chest Pain: Heart-Related or Lung-Related Cause in Patient with Congestive Heart Failure Detected by B-Mode Abdominal Ultrasonography". *EC Pulmonology and Respiratory Medicine* 9.5 (2020): 46-51.

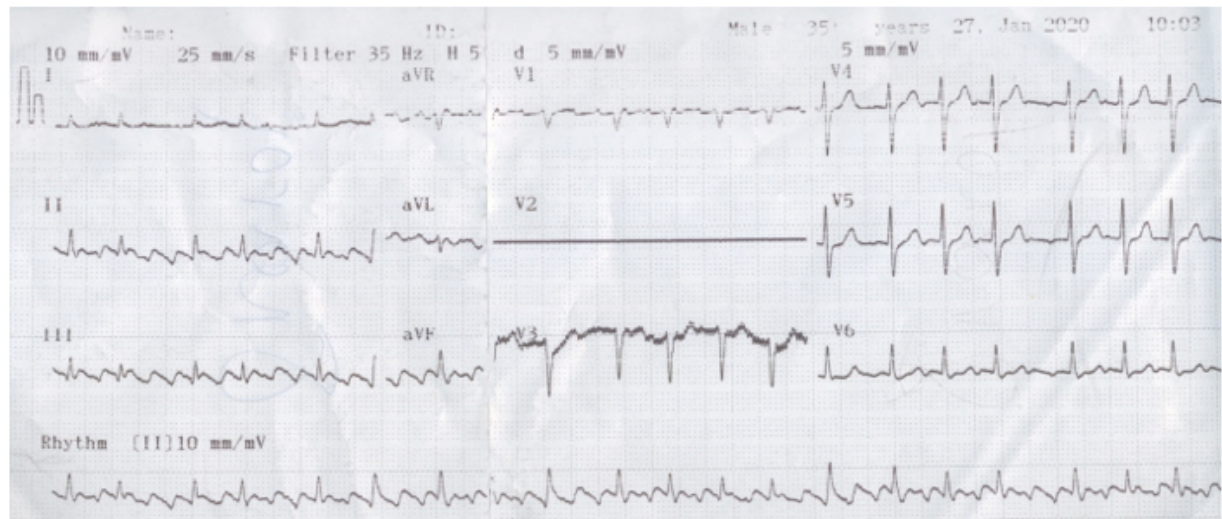
(CT) and abdominal B-mode ultrasonography with accuracy rate of more than 70% and 60%, respectively. The combined use of these two methods increases accuracy rate significantly to 86% [5,6].

An additional diagnostic value may be given by the examination of serum and pleural fluid biochemical analyses such as tumor markers, procalcitonin, C-reactive protein (CRP), brain natriuretic peptide (BNP), interferon - gamma, adenosine deaminase (ADA) etc.

### Case Report and Discussion

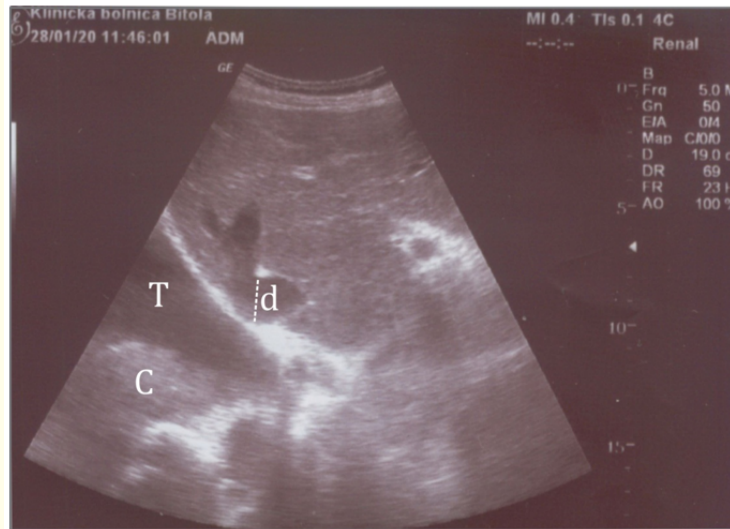
Male patient of 76 ages with difficult breathing and shortness of breath, severe burning pain in the chest when inhaling and exhaling, tachycardia, subfebrile temperature and pain spreading in the right shoulder, was examined in the ultrasonography ambulance of internal medicine. We conducted a detailed conversation with the patient in order to take his medical history (27.01.2020, 15h). The patient is diabetic more than 23 years [on Insuman comb 25 (20 I.E. + 8 I.E.)], light alcohol consumer over past 25 years, heavy smoker (pack year: 91) and he was formerly treated by symptoms of decompensate heart failure 2 times. We found just some of the pre-established diagnoses from his medical chart: Dg. Diabetes mellitus type 1. Bronchitis chr. obstructiva. Cardiomyopathia atherosclerotica congestiva. Broncho-pneumonia l dex. One month ago, in our hospital, the patient was treated for right - sided bronchopneumonia, but he left the treatment voluntarily after 3 days.

On physical examination I hear a scratching sound, and decreased breath sounds in lower 2/3 part of right pulmonary lobe with rales and egophony (suspected auscultatory signs for pleurisy and pneumonia with consolidation). Heart auscultation provided normal first and second heart sounds. Electrocardiography (ECG) was presented with sinus arrhythmia (Figure 1).



**Figure 1:** Electrocardiography findings in atypical chest pain (sinus arrhythmia, 150 bpm).

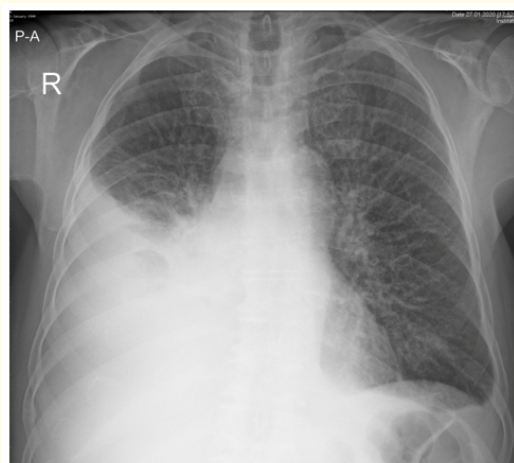
After lung and heart auscultation and ECG we made abdominal ultrasonography (Figure 2). Anechoic fluid triangle (T) below the diaphragm was detected near adjacent hepatic contours. Note the consolidation (C) of the lung, visualized as a hyperechoic mass superior to the diaphragm.



**Figure 2:** Abdominal ultrasonography showing large right-sided pleural effusions and passive hepatic congestion (transcostal ultrasound, one day after hospitalization: 28.01.2020).

The inferior vena cava (IVC) diameter (d) exceeds 2.4 cm in inspiration. The IVC diameter is altered with volume status and respiration, with higher IVC diameter during expiration than inspiration. The increase of IVC indicates increased right atrial pressure in patients with cardiac or renal disease [7,8]. Based on previous physical and diagnostic patient's examination we diagnosed right - sided pleural effusion with congestive heart failure and pulmonary consolidation (pneumonia).

Immediately we started with cardiotonics, bronchodilators, corticosteroids, antibiotics and diuretics administrations. While waiting for the results of the first biochemical blood tests we made a chest X-ray radiography (Figure 3).

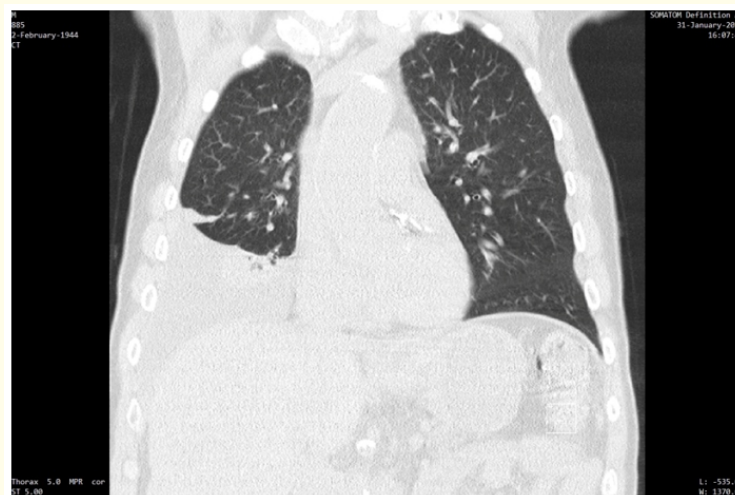


**Figure 3:** Chest X - ray showing right lower consolidation with pleural effusion (AP projection, one hour after hospitalization: 27.01.2020).

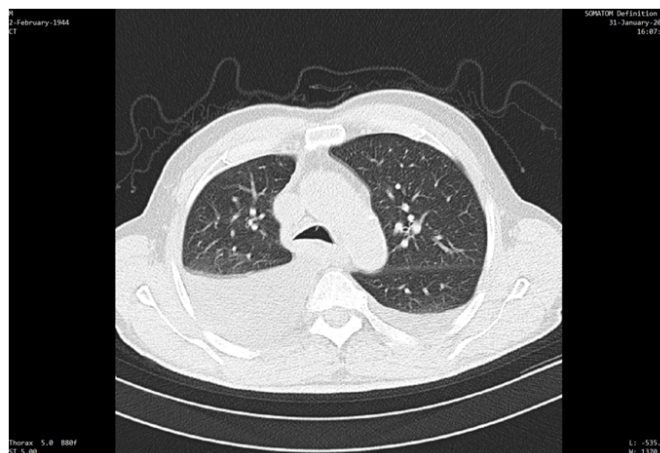
Chest X-ray showed an excessive accumulation of fluid in the pleural space (pleural effusion). More than two-thirds of the lung parenchyma was not presented on the radiography image. Elevated C-reactive protein (CRP = 188.7 mg/mL), granulocytosis = 85.4%, elevated leukocytes ( $18.4 \times 10^9/L$ ), elevated serum ferritin = 257 ng/ml and elevated brain natriuretic peptide (BNP = 274.2 pg/mL) were additional clinical biomarkers that confirmed the inflammatory nature of the pulmonary disease associated with congestive heart failure. Elevated liver enzymes alanine aminotransferase (ALT = 112 U/L), aspartate aminotransferase (AST = 238 U/L), alkaline phosphatase (ALP = 97 U/L) and associated hyperbilirubinemia (Total bilirubin = 47.2  $\mu\text{mol/L}$ , Conjugated bilirubin = 21.3  $\mu\text{mol/L}$ ) and gamma-glutamyl transferase (GGT = 113 U/L) indicate passive hepatic congestion due to increased central venous pressure, impaired liver perfusion according decreased cardiac output and liver reduced capacity of glucuronyl transferase.

One week intravenous administration of L-ornithine L-aspartate and hepatoprotective drugs in combination with previously prescribed therapy [(cardiotonics, bronchodilators, corticosteroids, antibiotics, diuretics, potassium-sparing diuretic, beta blockers and Insuman comb 25 (20 + 8 I.E.)) results in a significant improvement of laboratory findings (CRP = 12.3 mg/mL, granulocytes = 78.3%, serum ferritin = 213 ng/mL, BNP = 104.40 pg/mL, ALT = 83 U/L, AST = 145 U/L, total bilirubin = 27.2  $\mu\text{mol/L}$ , Conjugated bilirubin = 13.6  $\mu\text{mol/L}$ , GGT = 94 U/L) and clinical condition.

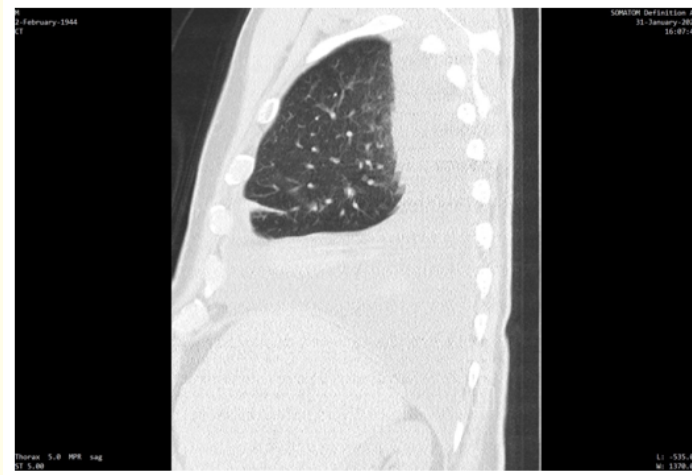
In the intermediate phase of pharmacotherapy, the fourth day of hospitalization, we did computed tomography (CT) imaging to assess the quantity of previously massive pleural effusion. CT scan coronal, axial and lateral projections are showed on figure 4-6 respectively.



**Figure 4:** Computed tomography (CT) scan of the chest showing right-sided massive pleural effusion (coronal projection, 31.01.2020).

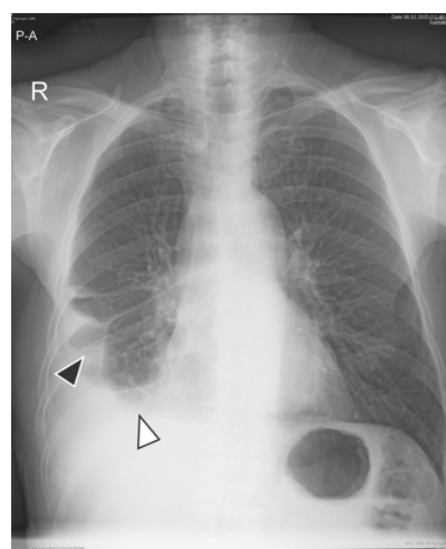


**Figure 5:** Computed tomography (CT) scan of the chest showing right-sided massive pleural effusion (axial projection, 31.01.2020).



**Figure 6:** Lateral computed tomography (CT) chest scan demonstrate right-sided massive pleural effusion (31.01.2020).

In order to compare the abundance of pleural effusion we made control chest X-radiography ten days after hospitalization. Figure 3 and 7 shows the difference in the amount of pleural effusion, before and after medication therapy.



**Figure 7:** Chest X-ray showing evident regression of the pleural effusion and pulmonary collapse (AP projection, ten days after hospitalization: 06.02.2020).

There is an evident regression of pleural effusion compared with chest x-ray in figure 3. Pleural-based, cushion-like consolidation to the right costophrenic angle (black arrowhead) and slight elevation of the right hemidiaphragm is also evident (white arrowhead).



## **Conclusion**

We conclude that B-mode abdominal ultrasonography can be a powerful diagnostic tool for detecting of the etiology in pleuritic chest pain, whatever the cause of genesis, heart-related, lung-related, or double causal as our case report of pleural effusion with pneumonia. B-mode ultrasonography detected both pleural effusion and passive hepatic congestion.

## **Bibliography**

1. Reamy BV, *et al.* "Pleuritic Chest Pain: Sorting through the Differential Diagnosis". *American Family Physician* 96.5 (2017): 306-312.
2. Campbell KA, *et al.* "Non-cardiac Chest Pain: A Review for the Consultation-Liaison Psychiatrist". *Psychosomatics* 58.3 (2017): 252-265.
3. Pollack Jr CV, *et al.* "Pleurisy". In: Pollack Jr. C. (eds) *Differential Diagnosis of Cardiopulmonary Disease*. Springer, Cham (2019).
4. Yan C, *et al.* "Lung ultrasound vs. chest X-ray in children with suspected pneumonia confirmed by chest computed tomography: A retrospective cohort study". *Experimental and Therapeutic Medicine* 19.2 (2020): 1363-1369.
5. Radzina M and Biederer J. "Ultrasonography of the Lung". *Rofo* 191.10 (2019): 909-923.
6. Zhou S, *et al.* "Imaging manifestations of B-mode ultrasound combined with CT in tuberculous pleuritis patients and the diagnostic value". *Experimental and Therapeutic Medicine* 16.3 (2018): 2343-2348.
7. Brennan JM, *et al.* "Reappraisal of the use of inferior vena cava for estimating right atrial pressure". *Journal of the American Society of Echocardiography* 20.7 (2007): 857-861.
8. Mathis G. "Use of lung and pleural ultrasonography in emergency and intensive care medicine". *Medizinische Klinik-Intensivmedizin und Notfallmedizin* 114.6 (2019): 504-508.

**Volume 9 Issue 5 May 2020**

**© All rights reserved by Petar Avramovski, *et al.***