

Detection of NSCLC in a Young Non-Smoker Patient: A Case Report

Mostafa Negmeldin*

Consultant of Respiratory Medicine, Bedford Hospital, UK

***Corresponding Author:** Mostafa Negmeldin, Consultant of Respiratory Medicine, Bedford Hospital, UK.

Received: October 24, 2019; **Published:** November 08, 2019

Abstract

Introduction: Non-small cell lung cancers account for 80 percent of lung malignancies [1] and of these, roughly 50 percent are adenocarcinomas. Therefore, it is the most common type of lung cancer [2].

Case Presentation: A 29-year old non-smoker presented with dyspnea, blood-tinged and significant loss of weight over the preceding 3 months. His examination detected right supraclavicular lymph node enlargement and bilateral inspiratory rhonchi. CXR and CT scan revealed encroachment of the trachea by a right-sided soft tissue mediastinal mass with right upper lobe nodule. Sonar guided biopsy from the supraclavicular node confirmed invasive adenocarcinoma with PD-L1 expression of more than 50%. Therefore, he was treated with pembrolizumab.

Discussion: This patient diagnosis was mistaken for bronchial asthma because of the wheeze and his young age. However, about 15% of lung cancer cases occur among nonsmokers, and each year about 20,000 people who never smoked die of lung cancer [3].

Keywords: *Non-Small Cell Lung Cancers; Pembrolizumab*

Introduction

It is thought that lung cancer is not only the most common form of cancer worldwide but also responsible for most deaths due to cancer [4,5]. Around 1.5 million died of lung cancer in 2012 [4]. Adenocarcinoma represents the most common subtype of NSCLC. Although its incidence has been decreasing, it is still a significant cause of cancer death in the USA. Moreover, it is the most common type of lung cancer that is diagnosed in non-smoker [6]. The last WHO classification of adenocarcinoma provides an important advance in morphological, clinical and biological aspects of the disease [7]. There are several variants of adenocarcinoma like mucinous adenocarcinoma (formerly mucinous BAC), colloid adenocarcinoma, fetal adenocarcinoma, and enteric adenocarcinoma [8]. According to the WHO, it is not enough to obtain a pathological diagnosis from the tissue specimen, but this should extend to molecular testing because of its important implications on management plan [9]. While TTF-1 may be the most widely used marker for adenocarcinoma, Napsin A, probably, is the most specific for lung adenocarcinoma [10].

Case Presentation

A 29-year old carpenter presented to our outpatient clinic complaining of chest tightness and wheezy dyspnea, especially at night. His complaint had been associated with blood-tinged sputum in addition to profuse sweating, poor appetite and loss of about 5 kilograms of weight over the preceding 3 months. Other systems review was unremarkable. Initially, he was diagnosed with bronchial asthma; therefore, he was treated with inhaled bronchodilators and corticosteroid with mild improvement. In terms of social history, he had never smoked nor had drunk alcohol while he lives alone. On examination, right supraclavicular lymph node enlargements combined with bilateral apical inspiratory wheezes were noted. This presentation raised concerns over the possibility of an underlying illness other than bronchial asthma. For this reason, he was admitted to the hospital for further assessment. CXR and CT chest revealed a 1 cm right upper lobe nodule with partially speculated margins. Additionally, there are bilateral ground-glass patches mainly in both upper lobes. The trachea has been encroached by a right-sided soft tissue mediastinal mass coinciding with enlarged thyroid gland versus amalgamated lymph nodes. A mild pericardial effusion is also noted. This picture is highly suggestive of a primary malignant pathology either in the lung or thyroid gland. This was followed by a neck ultrasound scan that reported a normal-sized thyroid gland besides bilateral cervical lymph

nodes enlargement; the largest one is the supraclavicular lymph node. While it is measured about 1.5 X 2 cm, its consistency appears heterogeneous. A sonar-guided biopsy from the supraclavicular lymph node confirmed invasive adenocarcinoma with tumor PD-L1 expression of more than 50 percent. Lastly, a brain CT scan showed no evidence of brain metastasis. This patient was referred to a tertiary oncology institute where he was intensively investigated then treated as a case of lung adenocarcinoma with pembrolizumab.

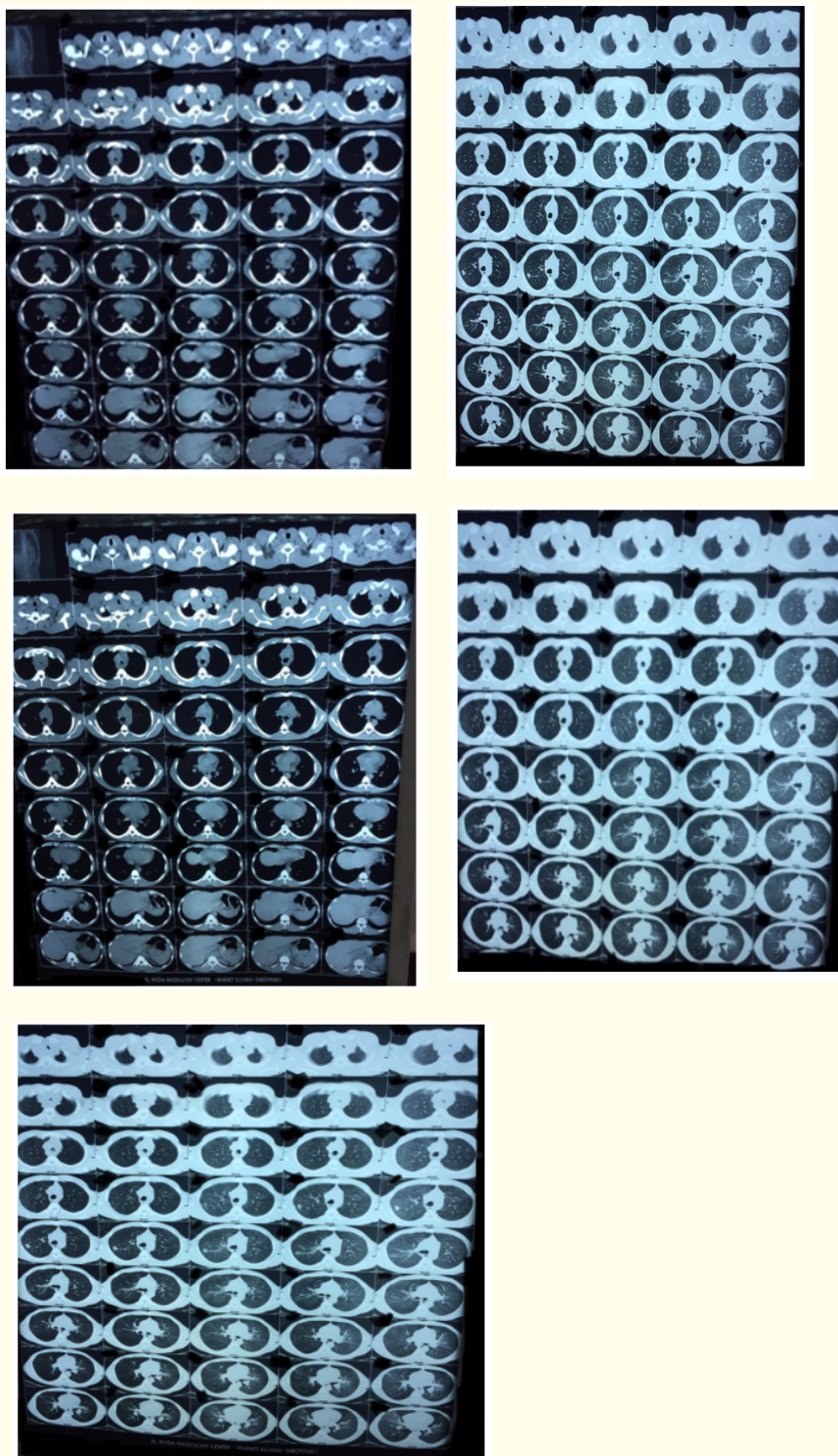


Figure : Patient CT showing the lung and mediastinal lesions after initial assessment.

Discussion

This patient diagnosis was mistaken for bronchial asthma because of the nocturnal dyspnea, and wheezes. Nevertheless, his rhonchi were originally inspiratory and maximally heard over both lung apices. Additionally, his young age and being a non-smoker made lung cancer unlikely. On the one hand, smoking plays an important role in the initiation and progression of lung adenocarcinoma; however, 10 - 40% of cases are non-smokers. Therefore, other contributing factors are incorporated as potential elements that may trigger its pathogenesis like environmental and genetic factors [11]. On the other hand, it is reported that about 5% of lung cancer patients present at the age of 45 years or younger. It is thought that this trend has been increasing [12]. Many recent studies have suggested that NSCLC occurring in young patients constitutes a disease entity with distinct clinicopathologic characteristics. Early-onset NSCLC occurring more often in women and never-smokers presents a predominance of lung adenocarcinoma. However, only a few studies have investigated the genomic alterations of NSCLC occurring in young patients, and all of them focused on the mutational frequency of several certain driver events involved in lung cancer. Compared with older patients with NSCLC, higher incidence of *ALK*, *ROS1* and *RET* fusions exist among the younger patients [13].

Conclusion

Over the last 20 years, the incidence of lung cancer has been rising. While small cell and squamous cell lung cancer are strongly associated with smoking, adenocarcinoma can affect young aged non-smokers [14].

It is important to respect patients' complaint particularly if it is indicating for another diagnosis. Part of this patient complaint was hemoptysis and loss of weight which are not common with bronchial asthma.

Bibliography

1. Karl W and Michael K. "Overview of the initial evaluation, diagnosis, and staging of patients with suspected lung cancer". Uptodate (2019).
2. Janssen-Heijnen ML, *et al.* "Is there a common etiology for the rising incidence of and decreasing survival with adenocarcinoma of the lung?" *Epidemiology* 12.2 (2001): 256-258.
3. Thun MJ, *et al.* "Lung cancer occurrence in never-smokers". *PLoS Medicine* 5.9 (2008): e185.
4. Brambilla E and Travis WD. "Lung cancer". In: World Cancer Report, Stewart BW, Wild CP (Eds), World Health Organization, Lyon (2014).
5. World Health Organization. "Fact sheets: Cancer" (2018).
6. Li C and Lu H. "Adenosquamous carcinoma of the lung". *OncoTargets and Therapy* 11 (2018): 4829-4835.
7. Travis WD, *et al.* "New pathologic classification of lung cancer: relevance for clinical practice and clinical trials". *Journal of Clinical Oncology* 31.8 (2013): 992-1001.
8. Murray and Nadel's Textbook of Respiratory Medicine (Sixth Edition) Volume 1 (2016): 225-250.
9. Travis WD, *et al.* "WHO Classification of Tumours of the Lung, Pleura, Thymus, and Heart". IARC Press, Lyon (2015).
10. Conde E, *et al.* "Lung adenocarcinoma in the era of targeted therapies: histological classification, sample prioritization, and predictive biomarkers". *Clinical and Translational Oncology* 15.7 (2013): 503-508.
11. Hecht SS. "Tobacco smoke carcinogens and lung cancer". *Journal of the National Cancer Institute* 91.14 (1999): 1194-1210.
12. The National Institutes of Health National Cancer Institute. SEER Cancer Statistics Review, 1975-2014 (2017).
13. Tanaka K, *et al.* "Unique prevalence of oncogenic genetic alterations in young patients with lung adenocarcinoma". *Cancer* 123.10 (2017): 1731- 1740.
14. Quoix E. "Novel epidemiology in lung cancer-non-smokers, females and cannabis". *Revue des Maladies Respiratoires* 24.8 (2007): S10-S15.

Volume 8 Issue 12 December 2019

© All rights reserved by Mostafa Negmeldin.