

Granulomatous Reaction to Silkospray® Used during an Endobronchial Ultrasound-Guided (EBUS) Transbronchial Needle Aspiration. An Undescribed Complication of EBUS

Javier Herranz Pérez^{1,2}, Miriam Gené Hijos^{2,3}, Matthew Corbett², Almudena Boix Lago², Sara Simonetti^{2,3} and Pablo Rubinstein-Aguñín^{4*}

¹Department of Internal Medicine, University General Hospital of Catalonia, Sant Cugat del Vallès, Barcelona, Spain

²International University of Catalonia, Sant Cugat del Vallès, Barcelona, Spain

³Department of Pathology, University General Hospital of Catalonia, Sant Cugat del Vallès, Barcelona, Spain

⁴Department of Pneumology, Hospital Universitari General de Catalunya, Sant Cugat del Vallès, Barcelona, Spain

***Corresponding Author:** Pablo Rubinstein-Aguñín, Department of Pneumology, Hospital Universitari General de Catalunya, Sant Cugat del Vallès, Barcelona, Spain.

Received: June 26, 2019; **Published:** August 30, 2019

Abstract

Several cases of granulomatous reactions to foreign bodies have been described in the literature, but only very few cases have been reported in relation to the lubricant gel used during EBUS-TBNA.

We present the case of a 37 year-old patient with a pulmonary sarcoidosis, diagnosed by EBUS-TBNA, who presented to the Emergency Room with fever, cough and severe chest pain, after ten days of the first endoscopy. After excluding mediastinitis, pericarditis, lung, mediastinum and esophageal perforation, a bronchoscopy was performed, showing a small polypoid tumoration, not present in the first EBUS. The biopsy showed bronchial mucosa with a non-necrotizing granulomatous reaction, associated to multinucleated giant cells surrounding fragments of foreign material, imputable to the lubricant gel (Silkospray®, Rüschi) used during endobronchial endoscopies.

Different complications have been described in consequence to EBUS-TBNA, including hemorrhage, infections, pneumothorax, endobronchial inflammatory polyp formation or presence of tuberculosis granulomas. We described, for the first time, a case of non-necrotizing granulomatous giant-cell reaction in bronchial mucosa, in relation to the lubricant gel, Silkospray®, used during EBUS-TBNA. Foreign body granuloma should be listed as an EBUS complication.

Keywords: Endobronchial Ultrasound-Guided Transbronchial Needle Aspiration; Foreign Bodies Granulomatous Reactions; Lubricant Gel; Silkospray®

Introduction

EBUS-TBNA is a minimally invasive diagnostic method that enables the collection of samples of peritracheal and peribronchial lesions under a real time ultrasound vision. This technique allows cytological and histological analysis of mediastinal lymph nodes and lung or bronchial tissue, with high sensitivity and specificity [1].

Despite being a minimally invasive method, EBUS-TBNA is not without complications. Hemorrhage, infections and pneumothorax have been described as the most common consequences. Less frequently, patients develop endobronchial inflammatory polyps, endobronchial mass or inflammation with granulation tissue [2-5]. Very rarely, inflammatory granulomas have been reported as nodular reaction following EBUS-TBNA [2].

Citation: Pablo Rubinstein-Aguñín, *et al.* "Granulomatous Reaction to Silkospray® Used during an Endobronchial Ultrasound-Guided (EBUS) Transbronchial Needle Aspiration. An Undescribed Complication of EBUS". *EC Pulmonology and Respiratory Medicine* 8.9 (2019): 699-702.

We present the case of a patient with probable sarcoidosis, who developed a foreign body reaction against a lubricating gel (Silkospray®) used during a previous EBUS-TBNA for the control of the disease.

Case Description

A 37-year-old woman with no medical history of interest, followed up for suspicion of sarcoidosis since 2015, due to the chance finding of bilateral mediastinal adenopathies on a preoperative chest RX for knee surgery. To complete the study, a chest CT was performed showing multiple mediastinal, paratracheal, subcarinal and bilateral hilar adenopathies (Figure 1A and 1B). An echocardiogram and a spirometry were performed, showing normal parameters. In February 2018, an EBUS-TBNA was performed for the study of lymph nodes (Figure 1C). Cytology samples showed mature lymphocytes and abundant bronchial cells without atypia, associated to histocytes and multinucleated giant cells. Absence of granulomas and of necrosis was observed. Histochemical staining for *Mycobacterium tuberculosis* resulted negative. Together with the clinical features of the patient, the diagnosis was suggestive of sarcoidosis, without ruling out other possibilities (Figure 2). There was no complication, nor fever, nor pain after the EBUS. Prednisone 50 mg/day was began.

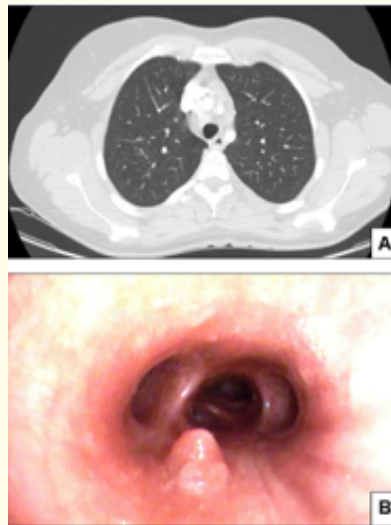

Figure 1: Radiological features of mediastinal mass.

Thoracoabdominal CT scan: A: Multiple lymphadenopathies with a size between 10 and 20 mm at the intrathoracic level. B: Ecography image of EBUS-TBNA.

After ten days from the EBUS, the patient presented to our hospital, at Emergency Room, with fever, cough and intense chest pain, increased with breathing. Therefore, the patient was hospitalized with the suspicion of mediastinitis, and treated with antibiotics (piperacillin-tazobactam 4 g/three times per day). A contrast-enhanced CT was performed, showing, in addition to the adenopathies, a bilateral pulmonary nodular pattern, similar than previously. An 2nd echocardiogram show no abnormalities. To evaluate possible activity of the disease, a lung PET-scan with Gallium 67 was performed where there is no uptake. The blood test for autoimmune markers was negative. Because of the persistence of pain, a bronchoscopy was performed. A polypoid lesion was observed on the intermediate bronchus, not observed in the previous endoscopy. Cytology samples (Figure 3B) and biopsies of the lesion were performed. The histology showed bronchial mucosa lined by not atypical respiratory epithelium. One of the fragments presented, in the stroma, granulation tissue, moderate

chronic and acute inflammatory infiltrate and multinucleated giant cells reaction to amorphous fragments of an acellular material, that were birefringent under polarized light, compatible with the lubricating gel (Silkospray®), used in previous EBUS-TBNA. Histochemical staining for *Mycobacterium tuberculosis* resulted negative. No neoplastic invasion was observed (Figure 3C and 3D). The patient received corticosteroid treatment and 6 months of follow-up.

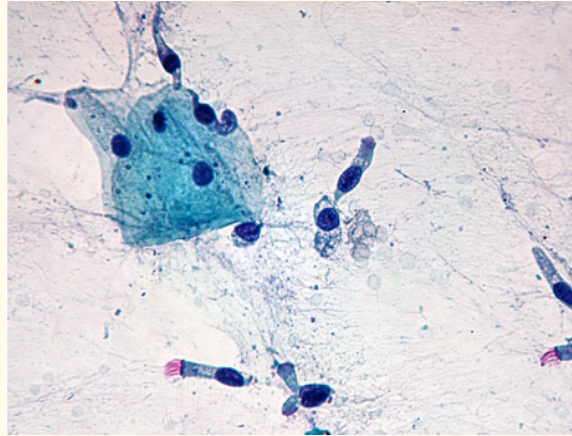


Figure 2: Cytology sample of mediastinal adenopathies of EBUS-TBNA performed in February 2018.

Liquid cytology showed mature lymphocytes and abundant bronchial cells without atypia, associated to histiocytes and multinucleated giant cells. Absence of granulomas and of necrosis was observed.

Discussion

EBUS-TBNA is a very safety and minimally invasive technique, whose clinical use has increased exponentially in recent years. Although rates of morbimortality are very low (1.23%), different complications have been described [1]. Post-EBUS infections such as mediastinitis, pneumonia, lung abscess, pleural empyema or bacterial pericarditis have been reported, probably due to a microbiological contamination of the puncture needle during the passage in the airways [5,6]. Pneumothorax and mediastinal or pulmonary bleeding have been described as severe and the most frequent complications [2-4]. One of the uncommonly observed events following EBUS-TBNA is the formation of nodular endobronchial masses, inflammatory polyps or granulation tissue reactions at the tracheobronchial puncture sites [2]. Very few patients have been described showing granulomas. In an English review of the literature we found only four cases of necrotizing granulomatous inflammation in trachea or bronchus post-EBUS-TBNA, in patients previously diagnosed of tuberculosis [2,7].

Reviewing the literature, we also found one case, diagnosed by EBUS-TBNA, of a non-necrotizing, foreign body granulomatous reaction in a right paratracheal lymph node. In this case it was not secondary to the endoscopy, but to the hemostatic agent Surgicel® (Ethicon, North Ryde, NSW, Australia), used during the previous surgery for lung adenocarcinoma. It was detected one year after the operation and the cytology showed a giant cell reaction to amorphous material compatible with Surgicel®, similarly to the morphological features of our patient [8].

Silkospray® is a silicone spray used as a lubricant for synthetic materials (latex, PVC, rubber) to prevent adherences to the mucous membranes in endotracheal procedures. It has been observed that synthetic silicone can promote multinucleated giant cells reaction in different organs (siliconoma), especially in axillary lymph nodes after breast prosthesis rupture [9]. According to our knowledge, granulomatous reactions to Silkospray® have not yet been described. However, because of the chemical similarity to other silicone lubricants used in the clinical context, we supposed that this compound might provoke the formation of a "siliconoma".

In this report, we describe, for the first time, the case of a multinucleated giant cells granuloma against Silkospray®, used during an EBUS-TBNA for the diagnosis of sarcoidosis. The aim of our report is to consider, as possible complication after endobronchial endoscopies, the foreign body reactions to lubricants used during EBUS-TBNA. Moreover, it would be of great interest to check whether patients with sarcoidosis are more predisposed to the formation of granulomas by foreign bodies because of the pro-inflammatory context of the disease [10].

Conclusion

"Siliconoma" should be considered as a possible EBUS complication.

Conflict of Interest

The authors declare no conflict of interest.

Bibliography

1. Dhoria S, *et al.* "Utility and Safety of Endoscopic Ultrasound With Bronchoscope-Guided Fine-Needle Aspiration in Mediastinal Lymph Node Sampling: Systematic Review and Meta-Analysis". *Respiratory Care* 60.7 (2015): 1040-1050.
2. Madan K, *et al.* "Tracheobronchial puncture-site nodular reaction (TPNR) following endobronchial ultrasound-guided transbronchial needle aspiration (EBUS-TBNA): Systematic review of case reports". *Lung India* 34.6 (2017): 532-537.
3. Asano F, *et al.* "Complications associated with endobronchial ultrasound-guided transbronchial needle aspiration: a nationwide survey by the Japan Society for Respiratory Endoscopy". *Respiratory Research* 14 (2013): 50.
4. Giesa C, *et al.* "Severe Complications of Ultrasound Guided Transbronchial Needle Aspiration. A Case Series and Review of the Literature". *Pneumologie* 70.1 (2016): 23-27.
5. Gochi F, *et al.* "Mediastinal infectious complication after endobronchial ultrasound-guided transbronchial needle aspiration". *Interactive CardioVascular and Thoracic Surgery* 17.4 (2013): 751-752.
6. Jahoor A, *et al.* "Mediastinitis Following Endobronchial Ultrasound-guided Transbronchial Needle Aspiration". *Journal of Bronchology and Interventional Pulmonology* 24.4 (2017): 323-329.
7. Lee JW, *et al.* "Endotracheal tuberculous granuloma formation following endobronchial ultrasound transbronchial needle aspiration". *Internal Medicine* 52.11 (2013): 1207-1210.
8. Badenes D, *et al.* "A foreign body reaction to Surgicel® in a lymph node diagnosed by endobronchial ultrasound-guided transbronchial needle aspiration". *Annals of Thoracic Medicine* 12.1 (2017): 55-56.
9. Kaufman GJ, *et al.* "Silicone migration to the contralateral axillary lymph nodes and breast after highly cohesive silicone gel implant failure: a case report". *Cases Journal* 2 (2009): 6420.
10. Marcoval J, *et al.* "Foreign bodies in granulomatous cutaneous lesions of patients with systemic sarcoidosis". *Archives of Dermatology* 137.4 (2001): 427-430.

Volume 8 Issue 9 September 2019

©All rights reserved by Pablo Rubinstein-Aguñin, *et al.*