

A Perplexing Case of Recurrent Chest Pain

Maryum H Merchant*, Iain M Smith and Joanne Bando

Department of Pulmonary/Critical Care, University of California, Los Angeles, CA, USA

*Corresponding Author: Maryum H Merchant, Department of Pulmonary/Critical Care, University of California, Los Angeles, CA, USA.

Received: February 16, 2019; Published: February 22, 2019

Abstract

Granulomatous with Polyangiitis is a rare disorder characterized by granulomatous inflammation and necrotizing vasculitis involving many organs, mainly affecting sinuses, lung and kidneys.

We present a rare case of 54 year old Middle Eastern woman with p-ANCA positive Granulomatous with Polyangiitis with involvement limited to her lungs. She initially presented with an exudative loculated left pleural effusion requiring open thoracotomy with decortication. The culture on the pleural fluid and surgical specimen were negative and cytology was consistent with an acute inflammatory process. A few months later, she presented with multiple enlarging pulmonary nodules and elevated p ANCA levels. Subsequent CT guided biopsy of one of the pulmonary nodule showed medium sized vessel vasculitis with eosinophils, rare giant cells (suggesting granulomas), and surrounding mixed inflammatory infiltrates. Trichrome and PAS + D stains were consistent with vasculitis. Repeated urinalysis were bland and her serum creatinine remained within normal limits. She was treated with tapering doses of glucocorticoids with complete resolution of pulmonary nodules on follow up CT chest.

This case alerts the physicians of the rare and atypical presentation of vasculitis, in which pleural effusion was the first clinical manifestation.

Keywords: Arthritis; Vasculitis; Multiple Pulmonary Nodules

Introduction and Methodology

Granulomatous with Polyangiitis is a rare disorder characterized by granulomatous inflammation and necrotizing vasculitis involving many organs, mainly affecting sinuses, lung and kidneys.

Case History

54 y/o female, non-smoker, with medical history significant for recurrent sinusitis and multinodular goiter, presented to our clinic for evaluation of recurrent bilateral pleuritic chest pain, persistent malaise, fatigue, and low grade fevers.

Five months ago, she was hospitalized with a loculated left exudative, neutrophilic predominant pleural effusion, that required open thoracotomy with decortication (Figure 1). Pleural fluid and surgical specimen cultures were negative and pathologic analysis revealed an acute fibrinopurulent exudative material without evidence of malignancy. She was treated with systemic antibiotic with symptomatic improvement.

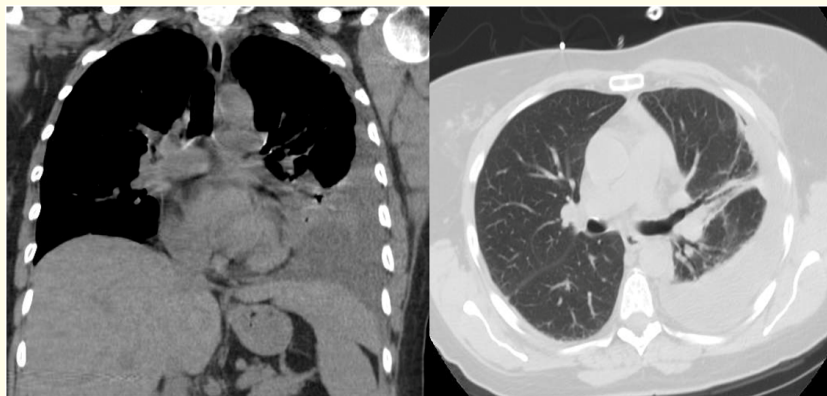

Figure 1

One month ago, a chest CT scan was done for right sided pleuritic chest pain, malaise, and dry cough. It revealed new bilateral lower lobe pulmonary nodules, the largest measuring 2.0 x 1.2 cm, as well as small bilateral pleural effusions (Figure 2). Laboratory tests included normal white blood count, urea nitrogen and creatinine levels, bland urinary sediments, elevated CRP of 48 mg/L and ESR of 59 mm/hr. Serologic tests for coccidioidomycosis, histoplasma and quantiferon TB were within normal limits. A moderate elevation of p-ANCA was observed (1:160 titers) with negative tests for c-ANCA, ds DNA antibodies, ANA, RA factor, proteinase 3 and myeloperoxidase. A CT guided transthoracic biopsy of the right lower lobe pulmonary nodule revealed patchy fibrous tissue with scant admixed eosinophils, a single multinucleated giant cell without necrosis, and no definitive evidence of capillaritis, vasculitis or malignancy. Stains and cultures for bacterial, fungal and mycobacterial organisms were negative.

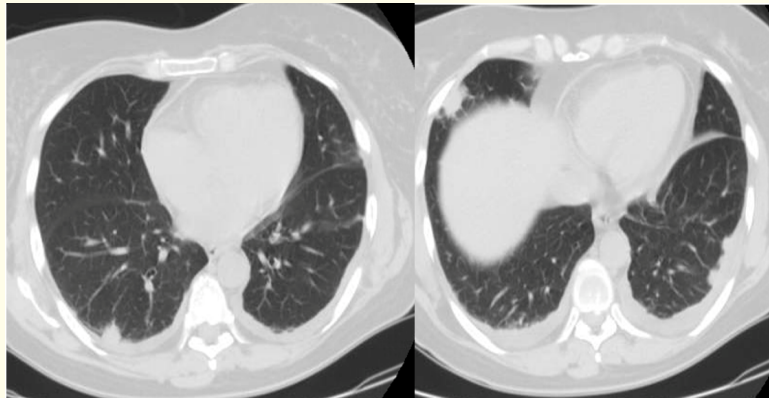


Figure 2

She continued to have persistent malaise, fatigue, and low grade fever. A repeat chest CT, in our clinic, revealed enlarging bilateral pulmonary nodules (Figure 3). She was hospitalized with repeated negative infectious work-up, including a transesophageal echocardiogram study which didn't identify any vegetations. Evaluation for rheumatological diseases revealed persistently elevated p-ANCA, ESR and CRP. After the patient refused a surgical lung biopsy, a repeat CT guided transthoracic biopsy of the right lower lobe lung nodule showed medium sized vessel vasculitis with eosinophils, rare giant cells (suggesting granulomas), and surrounding mixed inflammatory infiltrates. Trichrome and PAS + D stains were consistent with vasculitis. CT guided right thoracentesis revealed abundant eosinophils and neutrophils on cytology. GMS, AFB stains and cultures on pleural fluid and lung biopsy specimens were negative for organisms. Repeat urinalysis at this time, was bland and her serum creatinine levels remained within normal limits.

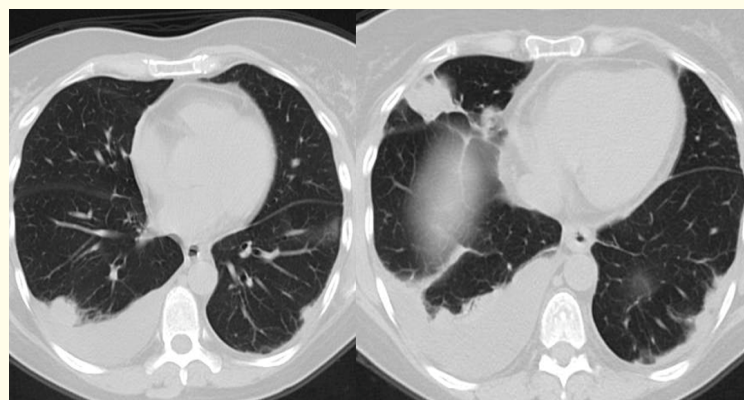


Figure 3

The patient was treated with 1 mg/kg prednisone, which was continued for 4 weeks and subsequently tapered. A follow-up chest CT 4 months later was performed and revealed near complete resolution of the pulmonary nodular opacities (Figure 4). She is currently maintained on methotrexate and low dose prednisone.

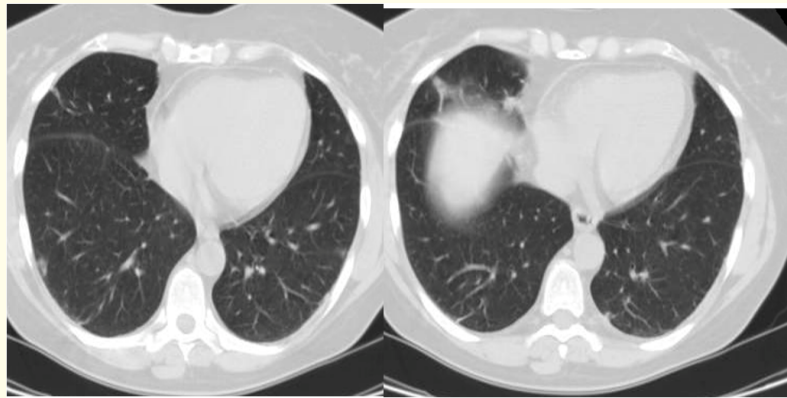


Figure 4

Based on the clinical, radiographic, and pathologic findings, we concluded that our patient had p-ANCA positive limited Granulomatous with Polyangiitis (GPA).

Discussion and Conclusion

We describe a patient with histologically confirmed pulmonary vasculitis and radiographic findings compatible with GPA, but with antibody profile that is not consistent with it. This case highlights the challenge a physician faces when encountered by a complex case that do not fit any current classification of vasculitis.

Granulomatous with polyangiitis was first described by Klinger in 1931 as a variant of polyarteritis nodosa, and then in greater detail as a separate syndrome by Wegener in two articles appearing in 1936 and 1939 [1,2]. In its systemic form, it can affect multiple organs typically beginning in the respiratory tract, spreading in varying degrees to other organs and culminating in a focal necrotizing glomerulitis. In 1966, Carrington and Leibow [3] described localized form of vasculitis and granulomatosis. They studied 16 patients who presented with symptoms of cough, chest pain, dyspnea, sore throat, pyrexia, and weight loss. The chest radiographs, in all cases, revealed multiple rounded nodular opacities, more commonly in the lower lung fields, with the absence of kidney involvement. These cases were classified on the basis of histology alone, since auto-antibodies such as ANCA were not available at that time [3-5].

The pattern of ANCA positivity has been used to help classify pulmonary vasculitis, although it is not 100% sensitive or specific. GPA is primarily associated with c-ANCA and PR-3 positivity, while Microscopic Polyangiitis with p-ANCA and MPO positivity. Although c-ANCA is found positive in more than 90% of patients with systemic disease, its sensitivity drops to 60 % in localized form of GPA. About 20% of patients with GPA may have an alternate ANCA type and at least 10% of patients with GPA are ANCA negative. False positive c-ANCA tests (in infection and collagen vascular disease) are occasionally encountered. It is perhaps, for this reason, the presence of ANCA is not required to make a diagnosis of GPA by either the American College of Rheumatology or the Chapel Hill Consensus Conference definitions.

Two other pulmonary vasculitis conditions can closely resemble limited GPA: Microscopic Polyangiitis (MPA) and Churg Strauss Syndrome. Microscopic Polyangiitis (MPA) is more closely associated with p-ANCA positivity and can involve the lung alone. The pathology, however, should not show granulomatous inflammation. The presence of abundant eosinophils in the lung tissue and pleural effusion in our patient does raise the possibility of Churg Strauss Syndrome. However, Churg Strauss Syndrome is strictly characterized by a triad of asthma, eosinophilia and necrotizing granulomatous vasculitis. Our patient did not have asthma or peripheral eosinophilia. The authors propose that eosinophilic infiltration in the biopsy sample of the lung tissue and pleural effusion in our patient could be secondary to prior pleural membrane manipulation.

Although parenchymal pulmonary lesions are common in GPA, pleural involvement is rare, with an estimated incidence of 10%. Of the cases documented in the literature, the pleural effusion in vasculitis is always exudative, characterized by low glucose, predominantly neutrophilic and is sterile [6,7]. Our patient initially presented with a similar characteristic pleural effusion. Toffart described a case of GPA in which pleural effusion was the first clinical manifestation [8]. Another case of an isolated pleurisy described in GPA was characterized by an eosinophilic effusion without peripheral blood eosinophilia [9].

Our patient also carried a diagnosis of multinodular goiter. It has been reported that in patients with GPA, there is a significantly higher prevalence of thyroid dysfunction compared to general population [10]. Both Grave's and Hashimoto's thyroiditis are autoimmune disease and perhaps this could be the mechanism by which they are linked to GPA.

Prognosis and management

The current consensus among vasculitis experts is that limited disease, in contrast to systemic disease, carries a much better prognosis. Many of the patients with limited disease may ultimately evolve into the systemic variant and subsequently develop glomerulonephritis [11,12]. It is important to make a distinction between limited and systemic disease subsets, because it has practical implications for treatment. Systemic disease require prompt institution of an aggressive therapeutic regimen that include glucocorticoids combined with either cyclophosphamide or rituximab. When cyclophosphamide is used, it is given for 3 to 6 months, and then switched to methotrexate or azathioprine for remission maintenance. In randomized trials, rituximab was found to be as effective as cyclophosphamide to induce remission of severe active GPA. In contrast, limited disease usually respond well to a less toxic alternative regimen consisting of methotrexate and glucocorticoids [13-16].

This case alerts physicians to be mindful of rare and atypical presentation of vasculitis.

Source of Support

None.

Disclaimer

The views expressed in this article do not communicate an official position of the University of California, Los Angeles.

Bibliography

1. Wegener F. "Ueber generalisierte septische Gefäßerkrankungen". *Verhandlungen der Deutschen Gesellschaft für Pathologie* 29 (1936): 202-210.
2. Wegener F. "Ueber eine eigenartige rhinogene Granulomatose mit besonderer Beteiligung des Arteriensystems und der Nieren". *Beiträge zur Pathologischen Anatomie* 102 (1939): 30-68.
3. Carrington CB and Liebow AA. "Limited forms of angiitis and granulomatosis of Wegener's type". *American Journal of Medicine* 41.4 (1966): 497-527.
4. Cassan SM., et al. "The concept of limited forms of Wegener's granulomatosis". *American Journal of Medicine* 49.3 (1970): 366-379.
5. Dechambre S., et al. "Unilaterally multiplying and migrating pulmonary masses: first manifestation of limited Wegener's granulomatosis". *Journal Belge de Radiologie* 79 (1996): 162-164.
6. Blundell AG and Roe S. "Wegener's granulomatosis presenting as a pleural effusion". *British Medical Journal* 327.7406 (2003): 95-96.
7. Diot E., et al. "Wegener's disease mimicking acute infectious pleurisy". *Revue de Pneumologie Clinique* 56.4 (2000): 265-268.
8. Toffart AC., et al. "Wegener Granulomatosis Revealed by Pleural Effusion". *Case Reports in Medicine* (2009): 164395.
9. McCann JL and Morris ZQ. "Wegener granulomatosis presenting as an eosinophilic pleural effusion". *Chest* 130.4 (2006): 327S.
10. Lionaki S., et al. "Association between thyroid disease and its treatment with ANCA small-vessel vasculitis: a case-control study". *Nephrology Dialysis Transplantation* 22.12 (2007): 3508-3515.
11. Luqmani RA., et al. "Classical versus non-renal Wegener's granulomatosis". *QJM: An International Journal of Medicine* 87.3 (1994): 161-167.
12. Stone JH. "Limited versus severe Wegener's granulomatosis: Baseline data on patients in the Wegener's granulomatosis etanercept trial". *Arthritis and Rheumatism* 48.8 (2003): 2299-2309.
13. De Groot K., et al. "Induction of remission in Wegener's granulomatosis with low dose methotrexate". *Journal of Rheumatology* 25.3 (1998): 492-495.

14. Stone JH., *et al.* "Treatment of non-life threatening Wegener's granulomatosis with methotrexate and daily prednisone as the initial therapy of choice". *Journal of Rheumatology* 26.5 (1999): 1134-1139.
15. E Besada., *et al.* "Long-term efficacy and safety of pre-emptive maintenance therapy with rituximab in granulomatosis with polyangiitis: results from a single centre". *Rheumatology* 52.11 (2013): 2041-2047.
16. Stone JH., *et al.* "Rituximab versus cyclophosphamide for ANCA- associated vasculitis". *New England Journal of Medicine* 363.3 (2010): 221-232.

Volume 8 Issue 3 March 2019

©All rights reserved by Rafia Bano., *et al.*