

Chronic Pulmonary Granulomatous Schistosomiasis with an Atypical Presentation

Ayman F Yousef^{1*} and Mohammed S Ishaq²

¹Cardiothoracic Surgeon, Department of Thoracic Surgery, King Saud Medical City, Riyadh, Kingdom of Saudi Arabia

²Thoracic Surgeon, Department of Thoracic Surgery, King Saud Medical City, Riyadh, Kingdom of Saudi Arabia

***Corresponding Author:** Ayman Yousef, Consultant Cardiothoracic Surgery, Department of Thoracic Surgery, King Saud Medical City, Ministry of Health, Riyadh, Kingdom of Saudi Arabia.

Received: January 30, 2019; **Published:** February 21, 2019

Abstract

Patients with chronic Schistosomiasis may feature a range of pulmonary symptoms and radiological findings. The pulmonary lesions of schistosomiasis manifest frequently as granulomas or tubers diffusely scattered around the bronchioles and alveoli and rarely occur as mass lesions. The finding of bilateral mass lesions in the chest leads one to entertain differential diagnoses of carcinoma or pulmonary tuberculosis. A 52-years-old patient who lived in a schistosomiasis endemic area with chronic productive cough and a pulmonary mass lesion with multiple pulmonary nodules suggestive of malignancy underwent exploratory thoracotomy. The lung-biopsy specimen showed several granulomas with *Schistosoma* eggs, and hyperplastic connective tissue with no sign of malignancy. The patient presented no clinical signs of pulmonary or portal hypertension; nor was either identified through diagnostic tests.

Keywords: Chronic Pulmonary Schistosomiasis; Parasitic Infection

Introduction

Schistosomiasis (SSM) is a helminthic infection, endemic to tropical and subtropical regions. The infection is common in parts of Africa, South America, the Middle East, the Caribbean, and Asia and is a leading cause of morbidity and mortality in these areas [1].

In individuals within these regions, chronic complications most often develop from progressive and recurrent infection [2].

Pulmonary involvement in SSM is uncommon, but has been described in populations live in these endemic areas [3].

Given the above, we report a case of man with the finding of granulomatous pulmonary nodules (eggs of *Schistosoma*) after many years coming from an endemic region without any hepato-intestinal manifestation.

Case Report

A Sudanese male patient, 52-years-old shepherd, non- smoker was seen in the out-patient department complaining of chronic productive cough with no loss of weight or appetite with occasional shortness of breath. At no time during his illness had he any fever, nor was there foul sputum. No past history of pulmonary tuberculosis or other chronic illness. On clinical examination: the patient was conscious alert and oriented, his general condition being fair. His pulse was 70 beats per minute and regular. There was no pyrexia and the blood pressure was 100/61 mmHg. He was not dyspnoeic and there was no clubbing of the fingers. Examination of the abdomen was normal. On chest examination an impaired percussion note was detected over the right infra-scapular area, but the breath sounds were normal

with diminished intensity and there were bilateral scattered mid- crackles. Other systems were normal. Laboratory evaluation showing blood picture of hemoglobin of 11.6 g/d; red blood cells 4.47 million/l; white blood cells 8,600 (polymorphs 69.9%, lymphocytes 17.5%, eosinophil count 3.2%, basophils 3.2%, monocytes 8.75%) Erythrocyte sedimentation rate 55mm/hour and arterial blood gases on room air were within normal range.

Sputum microscopy for acid fast bacilli 3 samples and direct DNA technique were negative. Purified Protein Derivative test was less than 5 mm. Sputum Gram stain showed few pus cells, no organism seen and culture was negative. Urine analysis at this time showed no red blood cells, and no parasites were identified on urine or stool microscopy, urine cytology showed no evidence of malignancy. Biochemical indices of hepatic and renal function were normal.

Chest radiograph and high resolution computed tomography of the chest (HRCT) revealed bilateral old fibrotic changes, with non-homogeneous opacities occupying the upper lobes of both lung and showing internal calcification. In addition to multiple calcified mediastinal and hilar lymph nodes, wide spread, ill-defined nodules in a predominantly peri-bronchovascular and sub-pleural distribution and a minimal right pleural effusion (Figure 1). CT Abdomen with contrast was normal. By abdominal ultrasound liver was average in size with mild coarse echotexture and no focal lesions or intrahepatic biliary radicular dilatation. Common bile duct and portal vein were not dilated.

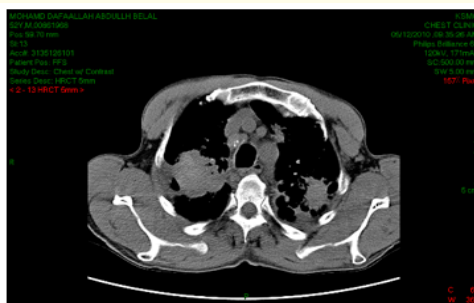

Figure 1: Bilateral mass lesions and fibrotic changes with calcified paratracheal lymph node (mediastinal window).

Clinical, laboratory, and radiological findings did not reveal the nature of the lesion, also fiber optic bronchoscopy revealed no changes in the bronchial tree. Search for the tuberculosis bacillus and fungi and other bacteria in bronchoalveolar lavage were negative. Cytology was negative for malignant cells. Eventually right mini thoracotomy was done and revealed multiple nodules and masses involving most of the right lung, with no involvement of parietal pleura, and a wedge biopsy of lung was taken from the right upper lobe.

Macroscopic analysis showed two brownish soft tissues lumps together measuring $2 \times 1 \times 1$ cm. Cut surface shows multiple whitish areas. Microscopically it showed large granulomata with central suppuration and fibrin deposition, surrounded by fibroblasts, lymphocytes and histocytes. Few eosinophils, plasma cells and foreign body giant cell reaction were also present. Initially we tried to rule out T.B and pulmonary mycosis. AFB and Grocott's stain revealed negative result. Deeper sections showed collection of multiple schistosomal ovi. Some of which were viable and others were calcified. The rest of the lung tissue showed atelectatic and emphysematous changes. Several sections revealed no significant arterial lesion caused by *Schistosoma* infection nor other non-schistosomal lesions. Again there was no evidence of malignancy (Figures 2 and 3).

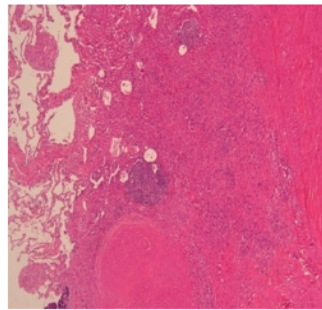


Figure 2: Lung tissue with large granulomata with surrounded by fibrosis and chronic inflammation (H and E stain 20× objective).

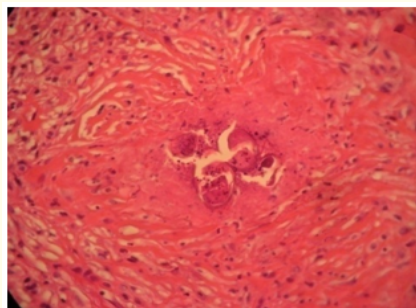


Figure 3: Schistosomal ova. The spines are not clear for central suppuration sub-classification (H and E stain 20× objective).

A diagnosis of schistosomiasis should prompt initiation of treatment, even if the patient is asymptomatic, since adult worms can live for years. The patient was treated with praziquantel (40 mg/kg, single oral dose) without complications. One month after treatment, a subjective improvement occurred as regard to his general condition, there was a decrease in the amount of sputum which became whitish, a chest CT scan showed a no changes on previous findings.

Discussion

Chronic schistosomiasis results from granuloma formation in response to the *Schistosoma* eggs; however, a complex relationship exists between the severity of clinical disease, the intensity of infection, and the infecting species [4].

Two types of chronic pulmonary schistosomiasis are now recognizable pathologically:

1. Cardiovascular type which is characterized by a necrotizing arteriolitis with endarteritis obliterans and perivascular tubercles. If these lesions are widespread, dilatation and thickening of arteries in the lungs and of the pulmonary artery and its primary branches may occur, the right ventricle hypertrophies, dilates and finally fails [5].
2. Parenchymatous or bronchopulmonary type. This is the one which occurred in our patient. Its pathologic incidence is more common than the former type and it is less serious clinically as in the present case. While the cardiovascular manifestations of schistosomiasis are well established, the parenchymatous types are still the subject of ongoing debate due to the fact that there is no definite correlation between the pathologic findings and the clinical features of bronchopulmonary schistosomiasis [5].

Patients with chronic schistosomiasis may have pulmonary involvement featuring a variable range of symptoms and radiological findings [6]. The most common clinical manifestation of chronic lung disease is dyspnea and reduced exercise tolerance, but severe hypox-

emia, chest pain and digital clubbing may also be found. Cor pulmonale develops in 5% of patients [7]. This case shows some features that fit into the established categories of chronic pulmonary schistosomiasis.

On clinical grounds, Mainzer, *et al.* [8] and Erfan, *et al.* [9] described a chronic type presenting as chronic bronchitis, bronchiectasis, emphysema and fibrosis or presenting as bronchial asthma.

Laboratory findings showed bilharzial ova are present in the urine or stools unless the bilharzial infection has died out as in this case or is the rare visceral form described by Mainzer, *et al.* [8]. The sputum may contain eosinophils, or rarely actual ova. Eosinophilia in the blood is present with active infection and may reach as high as 70 per cent. This rests on the presence of the above-mentioned clinical and radiological pictures, together with evidence of bilharzial infection. In endemic areas the presence of a cirrhotic liver may be taken as almost sure evidence of bilharziasis, even in the absence of ova from the urine and stools like our case [10].

Radiographic appearances including HRCT are of interstitial infiltrates, typically nodular or micronodular, and there may be frank fibrosis with calcification. This particular pattern of lung infiltration, however, is more usually described in longstanding interstitial pulmonary disease [11,12] and may simulate tuberculosis silicosis, sarcoidosis, atypical pneumonia or polyarteritis nodosa. These radiological appearances could be due to widespread granulomatous pulmonary schistosomiasis. In advanced cases marked affection of the heart and pulmonary artery occur [10].

Pulmonary nodes secondary to schistosomiasis as in our case are rare, and pose a differential diagnosis with lung neoplasia, are frequently defined only after exploratory thoracotomy [13]. The term 'pseudotumoral schistosomiasis presentation' was first used in 1975 describing a pulmonary nodule in a patient who died, who had autopsy findings of granulomatous reaction, *Schistosoma mansoni* eggs, and pulmonary arteriolitis obliteration [14,17]. The presence of a large mass associated to *Schistosoma* infection (bilharziasis) was described in 1953 in Cairo [10]. The authors pointed out that, as first hypothesis, the lung mass producing these pathology findings was secondary to schistosomiasis. In 2003 Marcelo, *et al.* reported a case of man with finding of granulomatous lung nodule (adult worm of *Schistosoma mansoni*) after 25 years of having been treated [15]. Another case report by Claudio, *et al.* 2009 was related to a 25-years-old patient who lived in a schistosomiasis endemic area with a pulmonary mass showed several granulomas with *Schistosoma mansoni* eggs [16].

The granulomas have no preferential location, and may be found in all lung segments and pleura. Inter-alveolar thickening and connective tissue fibrosis were also reported [18]. The tubercle is formed when the egg provokes a granuloma surrounded by histiocytes, few eosinophils and fibroblast within the lung parenchyma and the inflammatory reaction becomes chronic, with the granuloma resolving to a focus of fibrosis and scarring as in our case. These small granulomas are always related to the bronchioles or alveoli. In some patients the alveoli fill with a serofibrinous exudate which may progress to become patchy consolidation characteristic of bronchopneumonia [17].

Lesions from dead worms are rarer, and characterized by necrotic areas surrounded by intensive exudation, usually reabsorbed and involved by cicatricle tissue [19].

Conclusion

The interest elicited by this case is twofold. First, it is an example to stress the well-known fact of the necessity for having bacteriologic proof before accepting the clinical diagnosis of tuberculosis. Second, it is a rare clinical manifestation of a pulmonary pathologic process caused by schistosomal infestation. The difficulty is the absence of sure diagnostic criteria, apart from the histopathologic picture of the lesion. From the review of the observations of previous workers, as well as the present case, it is seen that pulmonary manifestations in cases of bilharzias are numerous and variable. It is proposed that, in schistosomiasis endemic areas, pulmonary schistosomiasis is considered a differential diagnosis for complex structures, as pulmonary masses. Pulmonary bilharziasis may be arrested at any stage, and the patient may live his normal span of life.

Bibliography

1. World Health Organization. "Prevention and control of schistosomiasis and soil-transmitted" 4 (1991): 1023-1026.
2. Lam-Quynh Nguyen., *et al.* "Acute Schistosomiasis in Nonimmune Travellers: Chest CT Findings in 10 Patients". *American Journal of Roentgenology* 186.5 (2006): 1300-1303.
3. Schaberg T., *et al.* "Pulmonary schistosomiasis resembling acute pulmonary tuberculosis". *European Respiratory Journal* 4.8 (1991): 1023-1026.
4. Morris W and Knauer CM. "Cardiopulmonary manifestations of schistosomiasis". *Seminars in Respiratory Infections* 12.2 (1997): 159-170.
5. Abdel-Hakim M and Anwar M Elwi. "Bronchopulmonary Schistosomiasis: Case Report". *Diseases of the Chest* 43 (1963): 317-319.
6. Schwartz E. "Pulmonary schistosomiasis". *Clinics in Chest Medicine* 23.2 (2002): 433-443.
7. Bethlem EP., *et al.* "Pulmonary schistosomiasis". *Current Opinion in Pulmonary Medicine* 3.5 (1997): 361-365.
8. Mainzer F. "On a Latent Pulmonary Disease Revealed by X-ray in Intestinal Bilharziasis (Schistosome Mansonii)". *Puerto Rico Journal of Public Health and Tropical Medicine* 1 (1939): 121.
9. Erfan M., *et al.* "Clinical Aspects of Pulmonary Bilharziasis". *Gaz. Kasr ci Amy Fac. Mcd* 13 (1957): 2.
10. Abdel-Aziz Sami. "Pulmonary Manifestations of Schistosomiasis". *Diseases of the Chest* 19.6 (1951): 698-705.
11. ADB Waldman., *et al.* "Sub acute pulmonary granulomatous schistosomiasis: high resolution CT appearances-another cause of the halo sign". *The British Journal of Radiology* 74.887 (2001): 1052-1055.
12. Rocha RL., *et al.* "Forma pulmonar crônica da esquistossomose mansoni: avaliação clínico-radiológica". *Revista da Sociedade Brasileira de Medicina Tropical* 23.2 (1990): 83-89.
13. Fatureto MC., *et al.* "Nódulo pulmonar esquistossomótico simulando neoplasia: relato de caso". *Revista da Sociedade Brasileira de Medicina Tropical* 36.6 (2003): 735-737.
14. Akoun G., *et al.* "Pseudotumoral pulmonary schistosomiasis due to *Schistosoma mansoni*". *La Nouvelle Presse Médicale* 4.33 (1975): 2408.
15. Santiago Martínez C., *et al.* "EDUCATION EXHIBIT 135 Thoracic Manifestations of Tropical Parasitic Infections: A Pictorial Review". *RadioGraphics* 25.1 (2005): 135-155.
16. Marcelo Cunha Fatureto., *et al.* "Pulmonary schistosomotic nodule simulating neoplasia: case report". *Revista da Sociedade Brasileira de Medicina Tropical* 36.6 (2003): 735-737.
17. Cláudio Dornas de Oliveira., *et al.* "Tumoral pulmonary mass secondary to *Schistosoma mansoni* infection resembling neoplasia: case report". *Revista Brasileira de Terapia Intensiva* 21.4 (2009): 461-464.
18. Bogliolo L. "Schistosomiasis mansoni. Pathology". *Revista Brasileira de Malariologia e Doenças Tropicais* 11 (1959): 359-424.
19. Barbato EC. "Schistosomal pneumopathy and chronic cor pulmonale". *Arquivos Brasileiros de Cardiologia* 6.3 (1953): 195-305.

Volume 8 Issue 3 March 2019**©All rights reserved by Ayman F Yousef and Mohammed S Ishaq.**