

A Rare Case of Foreign Body Aspiration (Needle)

Michail Galanis^{1*}, Saleem Elhabash¹, Ioannis Dimopoulos¹, Ryszard Turkiewicz² and Berthold Gerdes¹

¹Klinik für Allgemein Chirurgie, Viszeral-, Thorax- und Endokrine Chirurgie, Johannes Wesling University Hospital Minden, Germany

²Klinik für Pulmonologie, Johannes Wesling University Hospital Minden, Germany

*Corresponding Author: Michail Galanis, Funktionsoberarzt der Klinik für Allgemein Chirurgie, Viszeral, Thorax und Endokrine Chirurgie, Johannes Wesling University Hospital Minden, Germany.

Received: December 29, 2018; Published: February 22, 2019

Abstract

Aspiration of foreign bodies is common in the pediatric population as in adults. We describe a rare case of a 48-year-old male with a history of drug abuses who presented in the emergency department with a suspicion of needle swallowing. On admission, X-ray of the thorax and abdomen revealed a foreign body shadow in the mediastinum. An emergency esophagogastroduodenoscopy couldn't detect any foreign body in the upper gastrointestinal tract. In the flexible bronchoscopy, a needle was successfully removed from the left bronchial system (left main bronchus).

Keywords: Needle Aspiration; Foreign Body Aspiration; Aspiration in Adults; Pin Aspiration

Abbreviation

CT: Computer Tomography

Introduction and Case Report

We report a case of a 48-year-old male with a history of drug abuses, who presented in our emergency department giving a history of swallowing a foreign body. Upon questioning, the patient reported that he accidentally swallowed a needle while trying to suck the rest cocaine left after intravenous cocaine injection. Few minutes later, he had a retrosternal pain and was brought to the emergency department.

The initial physical examination showed normal vital signs, with no signs of bleeding or airway obstruction. An X-ray of thorax and abdomen revealed a foreign body in the mediastinum (Figure 1-3).

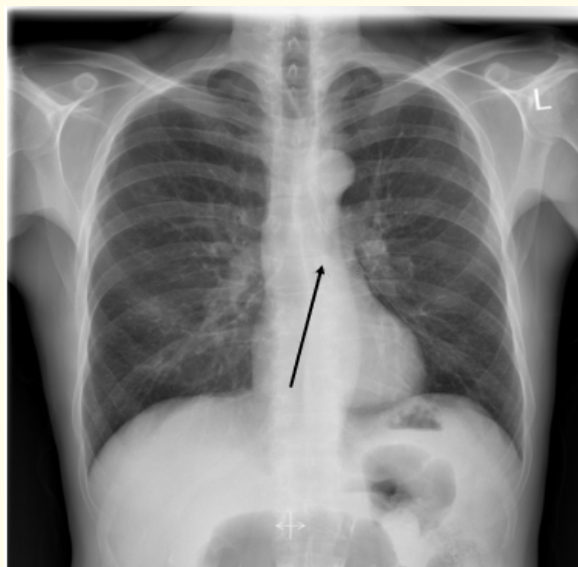


Figure 1: Posterior-anterior thorax X-ray.

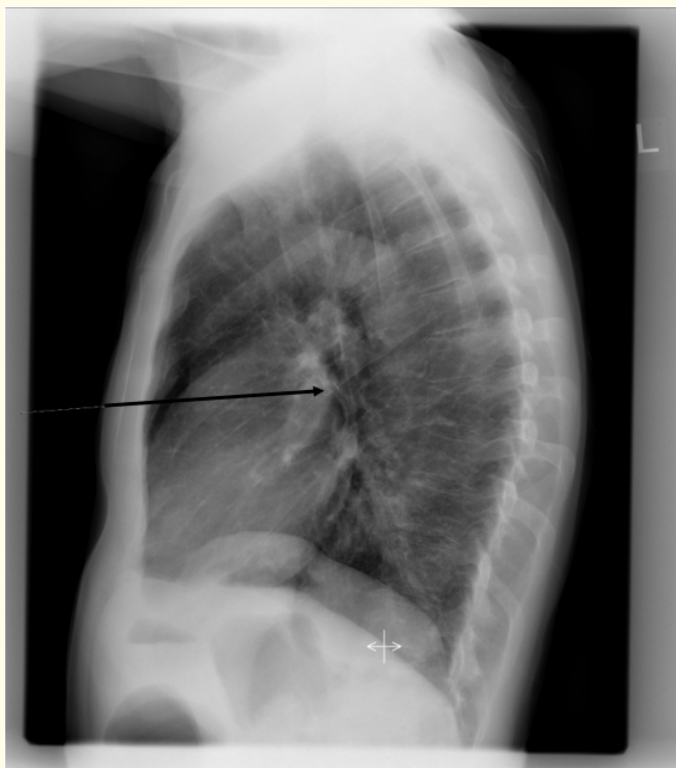

Figure 2: Lateral thorax X-ray.

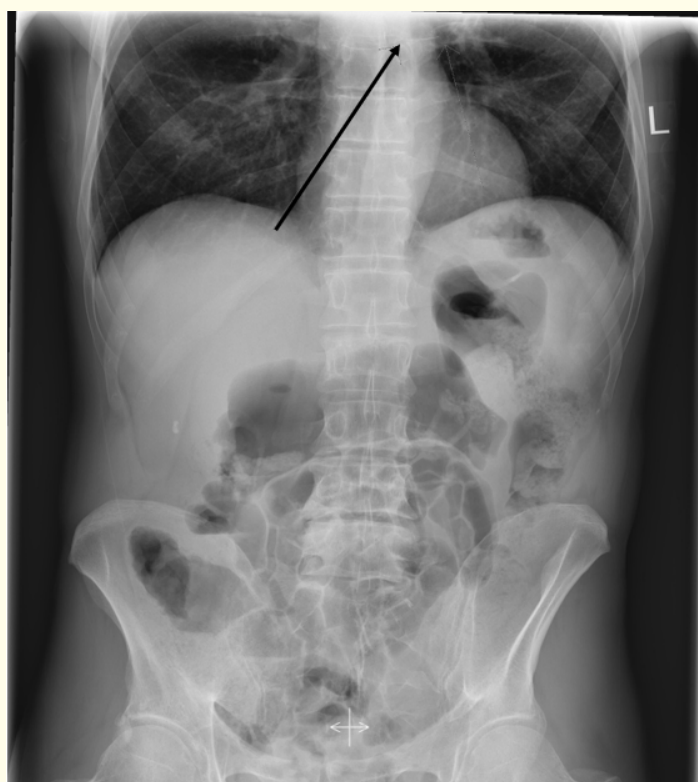

Figure 3: Posterior-anterior abdomen X-ray.

A pneumothorax was not detected. An emergency esophagogastroduodenoscopy didn't detect any foreign body in the upper gastrointestinal tract. An emergency flexible bronchoscopy showed a needle in the left main bronchus (Figure 4 and 5) without any sign of mucosal penetration or bleeding and was successfully removed without any complications (Figure 6 and 7).

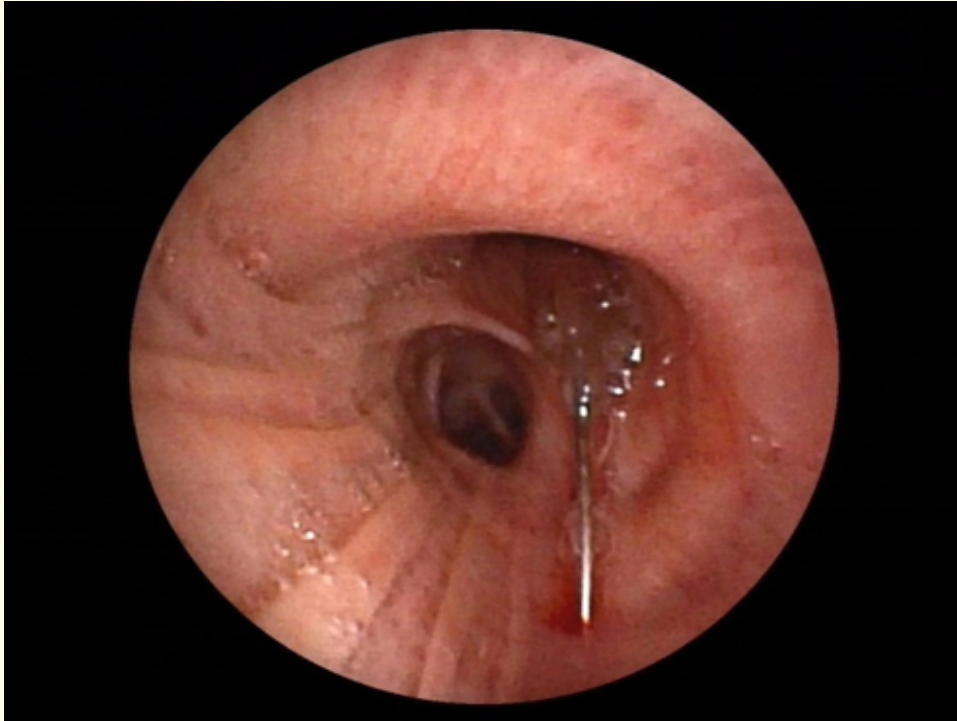


Figure 4: Bronchoscopy: The needle was found in the left main bronchus.

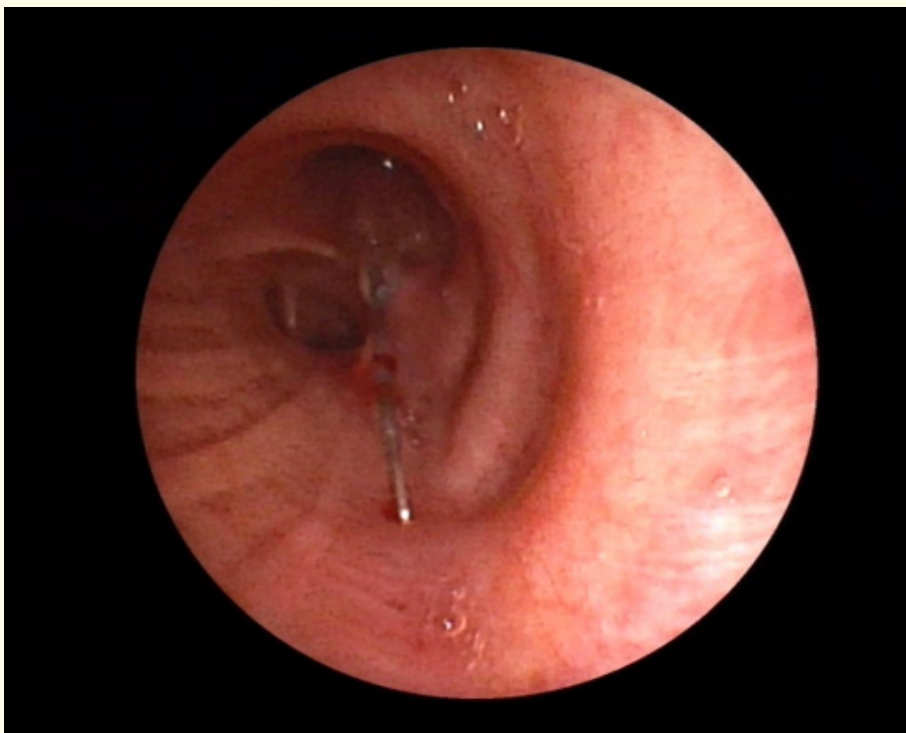


Figure 5: Bronchoscopy: the needle was found in left main bronchus.

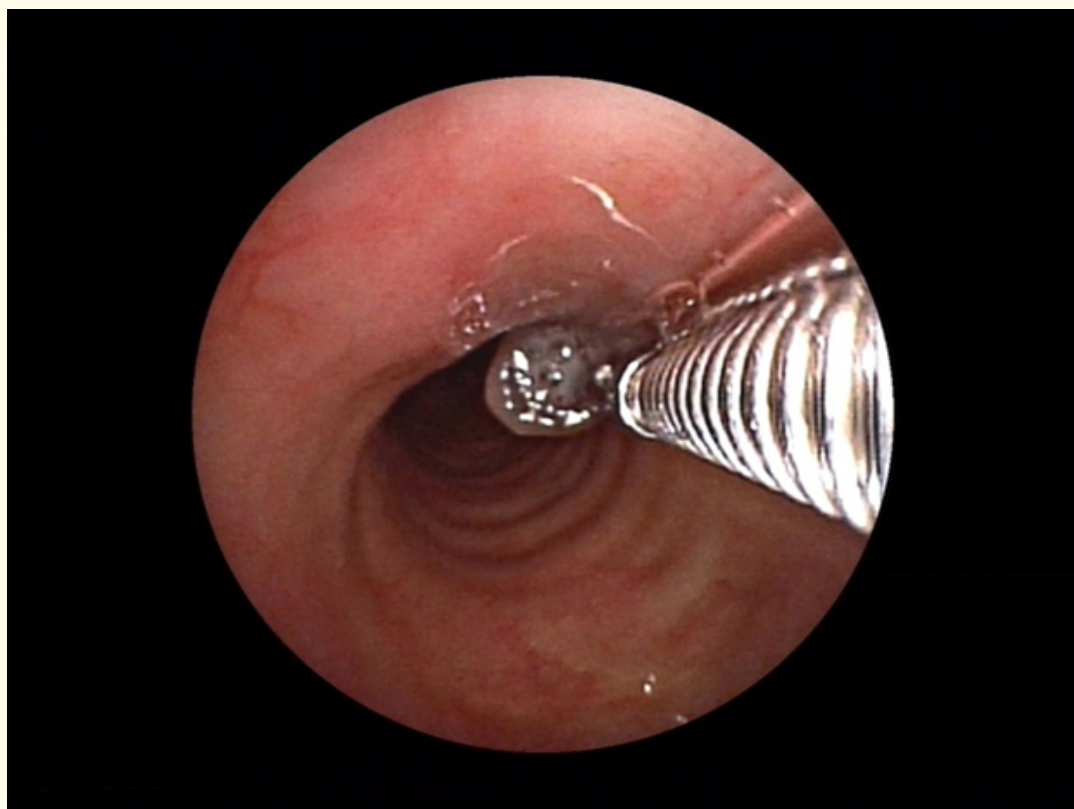


Figure 6: Bronchoscopy: The needle was removed without complications.

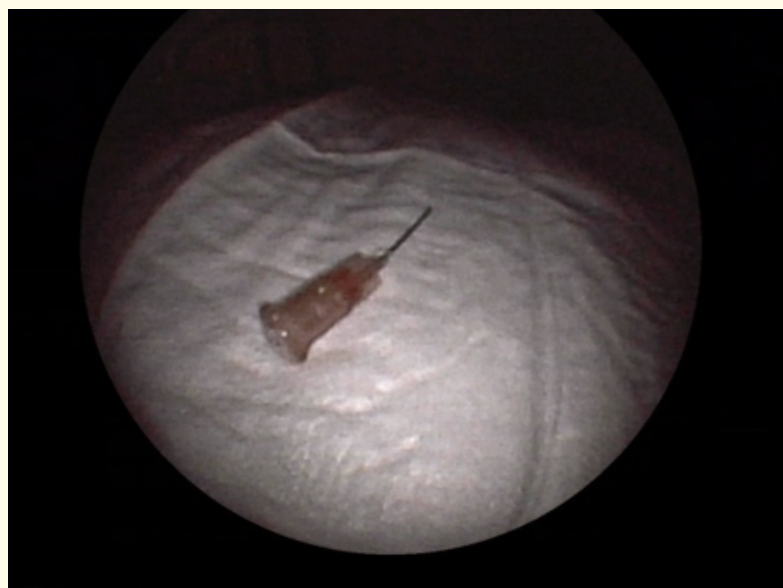


Figure 7: The needle was removed without complications.

Results and Discussion

Foreign body aspiration is common in the pediatric population and rarely described in adults. The most common presentation of foreign body aspiration is coughing attack combined with signs of airway obstruction. The right main bronchus is predominantly selected for foreign body aspiration [1] owing to the fact that it is anatomically wider, shorter and runs steeper than the left main bronchus. In children up to three years old, there is no significant difference in the allocation of foreign body aspiration in the bronchial tree. On the other side, in children older than three years, foreign bodies are more commonly found in the right main bronchus [2,3]. In our case, the foreign body was detected in the left main bronchus. Upon reviewing the literature, hairpin aspiration is commonly reported among young muslim girls who start wearing hijab (scarf) and was referred to as 'hijab syndrome' [4-10]. In these studies, the pin was mostly detected in the left main bronchus. This finding is attributed to the Bernoulli effect, which describes that the diameter of the left bronchus is smaller than the right one and for this reason a higher negative pressure is caused in the left main bronchus while breathing, speaking, laughing or coughing. As a result, the left bronchial system outweighs the anatomically vertical position of the right bronchial system in cases of foreign body aspiration.

Conclusion

In case of needle or pin aspiration, it is most common that the foreign body is detected on the left bronchial tree and this could be explained according to Bernoulli effect. A CT scan is a gold standard procedure for identifying the nature, position, and orientation of a pin. A multidisciplinary approach is important when managing this type of case in order to remove the foreign body as early as possible to prevent possible complications.

Conflict of Interest

The authors declare that there is no conflict of interest.

Bibliography

1. Lau CT, et al. "A light bulb moment. An unusual cause of foreign body aspiration in children". *BMJ Case Reports* (2015): bcr2015211452.
2. van Looij MAJ, et al. "Aspirated foreign bodies in children. Why are they more commonly found on the left?" *Clinical Otolaryngology and Allied Sciences* 28.4 (2003): 364-367.
3. Hamouri Shadi, et al. "Unique Challenges to the Approach and Management of Pediatric Headscarf Pin Aspiration". *Journal of Laparoscopic and Advanced Surgical Techniques. Part A* 28.10 (2018): 1243-1247.
4. Noh KB, et al. "Metallic hair pin aspiration into the left tertiary bronchus". *Malaysian Family Physician* 13.2 (2018): 36-38.
5. Rizk Nabil, et al. "Metallic hairpin inhalation. A healthcare problem facing young Muslim females". *Journal of Otolaryngology - Head and Neck Surgery* 43.1 (2014): 21.
6. Elsayed Abdelrahman AA, et al. "Bending of an Aspirated Pin During Rigid Bronchoscopy. Safeguards and Pitfalls". *Journal of Bronchology and Interventional Pulmonology* 25.3 (2018): 245-247.
7. Baram Aram, et al. "Scarf pin-related hijab syndrome. A new name for an unusual type of foreign body aspiration". *The Journal of International Medical Research* 45.6 (2017): 2078-2084.
8. Fenane Hicham, et al. "Scarf pin inhalation. Clinical characteristics and surgical treatment". *Journal of Cardiothoracic Surgery* 10 (2015): 61.
9. Hebbazi Afafe, et al. "L'inhalation d'épingle à foulard. Urgence pneumologique émergente". *The Pan African Medical Journal* 22 (2015): 277.
10. Parvez Yusuf, et al. "Accidental aspiration of head scarf pin in left bronchus piercing the lung parenchyma. A rare case in a child". *Lung India* 33.4 (2016): 424-426.

Volume 8 Issue 3 March 2019

©All rights reserved by Michail Galanis, et al.

Citation: Michail Galanis, et al. "A Rare Case of Foreign Body Aspiration (Needle)". *EC Pulmonology and Respiratory Medicine* 8.3 (2019): 252-256.