

Silhouette Sign: A Vital Chest Radiographic Indicator of Cardiac and Lung Pathologies

Rumi Khajotia*

Consultant Pulmonologist, Hospital Tuanku Ja'afar and International Medical University, Seremban, Malaysia

***Corresponding Author:** Rumi Khajotia, Consultant Pulmonologist, Hospital Tuanku Ja'afar and International Medical University, Seremban, Malaysia.

Received: January 02, 2019; **Published:** January 22, 2019

Abstract

The 'silhouette sign' is an important radiographic marker in diagnosis in clinical medicine. Obliteration of the cardiac silhouette can signify an adjoining lung pathology. The difference in the density between the heart and the aerated lungs enables us to clearly visualize the cardiac silhouette. However, when the normal aeration of the lung parenchyma is lost due to a lung pathology such as a consolidation or a collapse, the density of the lung parenchyma nears the 'water density' of the heart, resulting in an obliteration of the cardiac silhouette, provided the pathological lung segment is in direct anatomical contact with the heart and the two structures are aligned to each other, namely the cardiac border and the lung segment.

In this article we discuss the importance and clinical implications of the 'loss of cardiac silhouette,' popularly known as 'the silhouette sign'.

Keywords: *Silhouette Sign; Chest Radiographic Indicator; Cardiac Silhouette; Lung Collapse; Lung Consolidation; Bronchopulmonary Segments; Bronchoscopy*

The 'Silhouette sign' is one of the most useful signs in chest radiology.

The cardiac silhouette is the outline of the cardiac shadow as seen in posteroanterior (PA), anteroposterior (AP) and lateral chest radiographs. The silhouette sign describes the loss of the normal cardiac outline (silhouette) due to any pathology that replaces normal air-filled lung tissue.

The cardiac silhouette has great significance in the medical diagnosis of a number of heart and lung conditions.

While a change in size and shape of the cardiac silhouette can signify various cardiac pathologies, a loss of the cardiac silhouette typically signifies pathologies in the lungs.

It is a 'loss of cardiac silhouette' that signifies a 'positive silhouette sign,' and hence the term 'Silhouette sign' is somewhat a misnomer. In some instances, it is hence known as 'loss of silhouette sign' or 'loss of outline sign' [1]. It was Drs. Benjamin Felson and Henry Felson who actually popularized the term, 'silhouette sign' [2] though it was Dr. Henry Kennon Dunham an American chest physician and radiologist who was the first to describe this sign in the late 1920s.

To understand the significance of the 'silhouette sign' and its importance in clinical practice, it is firstly important to know what constitutes the cardiac silhouette.

From a frontal (PA, AP) view, the cardiac silhouette can be traced in a clockwise fashion starting from the lower right cardiac border and ending at the lower left cardiac border, as follows:

- From the right cardiophrenic angle, going upwards, the right border of the heart is formed by the right atrium, followed by the inferior vena cava (IVC) and then the superior vena cava (SVC).

Then tracing the border (silhouette) on the left side:

- The cardiac border (silhouette) is formed by the aortic arch superiorly, followed by the pulmonary conus, the left atrial appendage and finally the left ventricle, which extends downwards up to the left hemidiaphragm and also helps form the left cardiophrenic angle.

Remember, the right ventricle does not contribute to the formation of the cardiac border (silhouette) on a frontal (PA, AP) chest x-ray.

In comparison, on a lateral chest radiograph, the anterior border of the heart is formed by the right ventricle while the posterior border of the heart is formed by the left atrium superiorly and the inferior vena cava (IVC) and the left ventricle, inferiorly.

Size and shape of cardiac silhouette

The cardiac silhouette is considered to be enlarged if the cardiothoracic ratio is greater than 50% on a PA view of the chest [3,4].

The shape of the cardiac silhouette also gives crucial indications of possible underlying cardiac or lung pathologies, such as:

- If there is ‘straightening of the left cardiac border, it indicates either a valvular heart disease such as mitral stenosis or a lingular lobe lung collapse, most commonly, collapse of the inferior segment of the lingula.
- If the heart has a ‘bottle-shaped contour,’ it could either indicate the presence of a pericardial effusion or a severely dilated cardiomyopathy.
- If a ‘boot-shaped heart’ is seen (popularly known as *coeur en sabot*), it indicates right ventricular hypertrophy. This is commonly seen in patients with Tetralogy of Fallot. In such patients, the chest radiograph also usually shows an ‘exaggerated cardiac waist’ which indicates that the pulmonary segment is small and concave due to infundibular pulmonary stenosis.
- If the heart is enlarged on chest radiograph and the apex is shifted ‘downwards and outwards,’ it indicates left ventricular enlargement.
- Narrowing of the cardiac silhouette, also known as a ‘tear-drop heart,’ is indicative of hyperinflated lungs, as commonly seen in emphysema.

These are some of the more common pathologies related to the size and shape of the cardiac silhouette.

A ‘positive silhouette sign’ (loss of cardiac silhouette) on a frontal chest radiograph can occur due to the following conditions [5,6]:

- Obliteration of the right paratracheal stripe and superior vena cava are indicative of a right upper lobe collapse (Figure 1). The right upper lobe collapse occurs medially and the horizontal fissure is shifted superiorly with convexity upwards, creating a well-defined opacity in the right upper zone on frontal chest radiography. Consequently, the right hilum is elevated and the trachea is deviated to the right due to a pull caused by the collapsed lung. A right upper lobe collapse may be mistaken for a mediastinal opacity which may be considered as a differential diagnosis, depending on the patient history, examination findings and other investigations. A right upper lobe collapse may occur due to a variety of reasons, such as a right upper lobe bronchus blockage due to a foreign body, a bronchial adenoma or a malignancy, which may be endobronchial or which may be externally compressing the right upper lobe bronchus. A right upper lobe collapse may also be seen in a patient on mechanical ventilation. This is usually due to obstruction of the right upper lobe bronchus as a result of a faulty placement of the endotracheal tube.

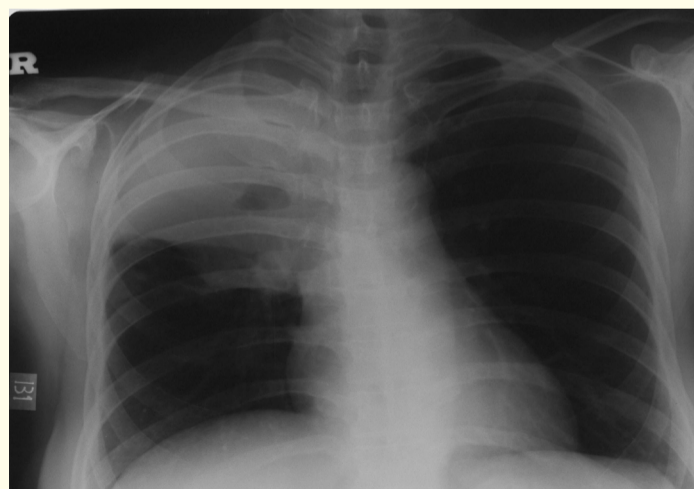


Figure 1: Right upper lobe collapse causing obliteration of the right paratracheal stripe and superior vena cava. The trachea is shifted to the right side.

- Obliteration of the right cardiac border on a frontal chest x-ray occurs due to collapse or consolidation of the medial segment of the right middle lobe. Right middle lobe collapse is also distinctly seen on a lateral chest radiograph. The middle lobe of the right lung collapses medially and is then adjacent to the right heart border, causing obliteration of a portion of the right heart border. In this case, the horizontal fissure will not be visualized as well. On the lateral chest radiograph this presents as a triangular opacity in the antero-inferior part of the thorax with the apex of the opacity pointing towards the hilum.
- Obliteration of the right hemidiaphragm on a frontal chest radiograph occurs due to right lower lobe lung collapse or consolidation. The right lower lobe collapses posteriorly, medially and inferiorly. It is seen as a wedged-shaped opacity in the right lower zone on a frontal view. The lower part of the right descending pulmonary artery is also not visualized because of the collapsed lung surrounding it. The right hemidiaphragm may be elevated (pulled upwards) indicating loss of lung volume. On lateral chest radiography, an area of opacity is seen overlying the lower thoracic vertebrae, and the right hemidiaphragm is obliterated.
- Obliteration of the aortic knuckle (aortic arch) can occur due to collapse or consolidation of the apico-posterior segment of the left upper lobe of the lung. In case of collapse of the apico-posterior segment of the left upper lobe of the lung, the trachea and the upper mediastinum are shifted (pulled) to the left side, and the left hilum is distinctly elevated. Loss of the normal left heart curvature ('straightening' of the left cardiac border) can occur due to lingular lobe collapse (especially the inferior segment of the lingula). In this case, on lateral chest radiography, a vertical strip of collapsed lung is seen located anteriorly.
- Obliteration of the left hemidiaphragm can occur due to left lower lobe lung collapse or consolidation. In case of a left lower lobe lung collapse, on frontal chest radiography, a triangular opacity is seen behind the cardiac shadow. There is also an obliteration of the lower part of the left descending pulmonary artery and the left hilum appears to be pulled downwards, accompanied by a shift of the left hemidiaphragm upwards, due to loss of aerated lung tissue. The descending aorta cannot be visualised due to the collapsed lung surrounding it. In such cases, lateral chest radiography shows an opacity overlapping the lower thoracic vertebrae with loss of contour of the left hemidiaphragm.
- Multilobar collapse: Multilobe collapse is commonly seen on the right side involving the right middle and lower lobes. This occurs due to obstruction of the bronchus intermedius. Collapse of both lobes simultaneously shows a combination of the radiographic signs that are seen in the collapse of the individual lobes. Figure 2 shows multilobar partial collapse of the right middle lobe and right upper lobe, causing obliteration of the superior vena cava and partial obliteration of the right cardiac border.

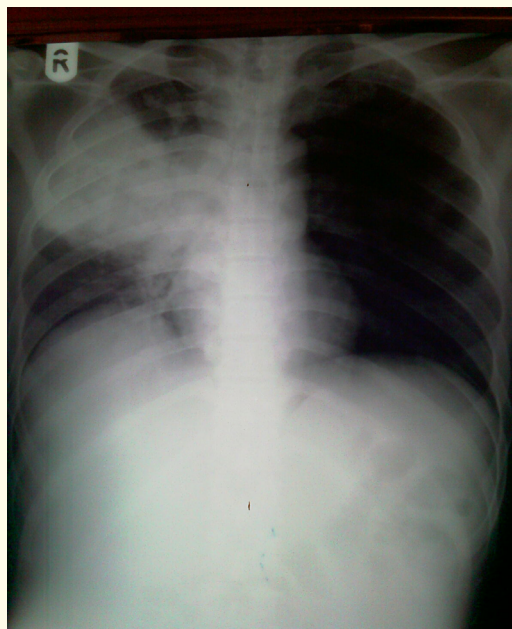


Figure 2: Multilobar collapse showing partial collapse of right middle lobe and right upper lobe, causing obliteration of the superior vena cava and partial obliteration of the right cardiac border.

A 'positive silhouette sign' (loss of cardiac silhouette) on a lateral chest radiograph is indicative of the following conditions [5,6]:

- Obliteration of the posterior cardiac border usually accompanied by obliteration of the posterior left hemidiaphragm is indicative of left lower lobe lung collapse or consolidation.
- Obliteration of the anterior right hemidiaphragm is indicative of right middle lobe lung collapse or consolidation.
- Obliteration of the posterior right hemidiaphragm is indicative of right lower lobe lung collapse or consolidation.

Discussion and Conclusion

The differential attenuation of x-ray photons by adjacent structures results in the formation of a silhouette or contour. In this case, the cardiac borders form a silhouette (contour) against the adjacent lung parenchyma.

The difference in the density between the heart and the air in the lungs enables us to clearly visualize the cardiac silhouette. However, when there is a pathology in the lung such as a collapse or a consolidation, the density of the lung parenchyma nears the 'water density' of the heart resulting in an obliteration of the cardiac silhouette, provided the pathological lung segment is in direct anatomical contact with the heart and the two structures are aligned to each other, namely the cardiac border and the lung segment.

In contrast, if the two structures are not anatomically aligned, the cardiac silhouette remains intact. For example, in case of right lower lobe lung collapse, while the right hemidiaphragm is obliterated due to the collapsed lung segment being in direct anatomical contact with the right hemidiaphragm, the right cardiac border remains distinct and intact and is not obliterated because the collapsed lung segment and the right cardiac border are not aligned to each other and are not in direct anatomical contact. In such a case, the collapsed lung margin can be distinctly seen as a 'double margin' behind the right cardiac shadow.

The 'silhouette sign' is also a very important radiographic marker prior to bronchoscopy as it clearly indicates which bronchopulmonary segment or segments are affected, so that on bronchoscopy the correct bronchopulmonary segments are visualized and suitable investigations such as bronchial brushings, washings and biopsy are carried out at the correct site, as needed in the patient.

Hence, the understanding of the mechanism and pathological significance of the 'Silhouette Sign,' is integral to the proper interpretation of cardiac and lung pathologies on chest radiography.

Bibliography

1. Wright FW. "Radiology of the chest and related conditions". CRC Press (2001).
2. Felson B and Felson H. "Localization of intrathoracic lesions by means of the postero-anterior roentgenogram the silhouette sign". *Radiology* 55.3 (1950): 363-374.
3. Brant WE and Helms C. "Fundamentals of diagnostic radiology". Lippincott Williams and Wilkins (2012).
4. Donna G Blankenbaker. "Signs in Radiology". *Radiology* 208 (1998): 319-320.
5. Webb WR and Higgins CB. "Thoracic Imaging". Lippincott Williams and Wilkins (2010).
6. Collins J and Stern EJ. "Chest radiology, the essentials". Lippincott Williams and Wilkins (2007).

Volume 8 Issue 2 February 2019

©All rights reserved by Rumi Khajotia.