

A Potentially Lethal Cause of Dysphagia

Atul Palkar* and Ankit Gupta

Division of Pulmonary and Critical Care Medicine, Department of Medicine, W. W. Backus Hospital, Hartford Healthcare, Norwich, CT, United States

***Corresponding Author:** Atul Palkar, Attending Physician, Division of Pulmonary and Critical Care Medicine, Department of Medicine, W. W. Backus Hospital, Hartford Healthcare, Norwich, CT, United States.

Received: December 17, 2018; **Published:** January 19, 2019

Abstract

A young woman was admitted with a 2-day history of painful swallowing and drooling. On imaging her epiglottis was swollen and contained gas. Direct laryngoscopy confirmed the presence of an epiglottic abscess. The abscess was drained with micro-direct laryngoscopy after endotracheal intubation and general anaesthesia. The patient recovered after empiric antibiotic and systemic corticosteroid therapy.

Keywords: *Dysphagia; Epiglottis; Laryngoscopy*

Introduction

An epiglottic abscess is a life-threatening collection of pus in the supraglottic region of the oropharynx. It may present as a deglutition disorder, and it may lead to critical upper airway obstruction. It is an infrequent complication of infectious epiglottitis, occurring in about 4% of cases [1]. Other rare causes of acute epiglottitis may include radiotherapy, thermal injuries, and caustic trauma [2]. Early suspicion in adults is critical to initiate timely therapy and prevent fatal complications.

Case Report

A 37-year-old woman presented to the emergency department with a 2-day history of sore throat, generalized malaise, dysphagia, odynophagia, and fever. She had difficulty with deglutition of solids and liquids, and complained of drooling. She had no diplopia, gait instability, ataxia, neck pain, or arm weakness, and denied sick contacts, trauma, or inhalation of chemicals. She did not take any medications or herbal supplements. She worked in a spa, was a non-smoker, and denied consuming alcohol, or any recreational drugs. Her family history was significant for hypertension and diabetes mellitus in both parents.

On physical examination, she was febrile up to 102°F. Her pulse was 107 per minute, respiratory rate was 14 breaths per minute, blood pressure was 130/83 mm Hg, and oxygen saturation on pulse oximetry was 100% on 2 litres per minute by nasal cannula.

She had a muffled voice. Examination of her oropharynx was normal. Exam of the neck revealed no adenopathy or stridor. There was mild tenderness on palpation of her thyroid cartilage. Intranasal exam is normal. Her lungs were clear to auscultation. She was alert and oriented with intact cranial nerve function and no focal neurologic deficits. Rest of her physical examination was within normal limits. Complete blood count showed neutrophilic leucocytosis. Rapid strep throat test was negative.

Computed tomography of her neck with intravenous contrast (Figure 1-3) revealed thickening and gas within the epiglottis. A fiberoptic laryngoscopy was performed at the bedside after ENT consultation. Nasopharynx and tongue base were normal. Exam of the epiglottis revealed diffusely erythematous and edematous epiglottis more enlarged on the left with a cystic appearance. The vocal cords are normal and showed good mobility. Due to concern for impending airway compromise due to the degree of epiglottic swelling, the patient was taken to the operating room after endotracheal intubation and a micro-direct laryngoscopy was performed with biopsies and drainage of epiglottic abscess.

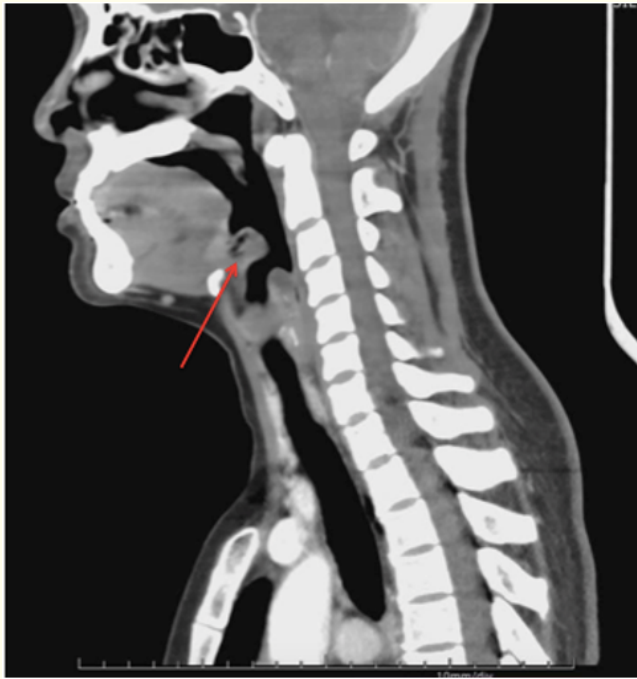


Figure 1: Sagittal view of computed tomography (CT) of neck with intravenous contrast shows epiglottic swelling (red arrow).

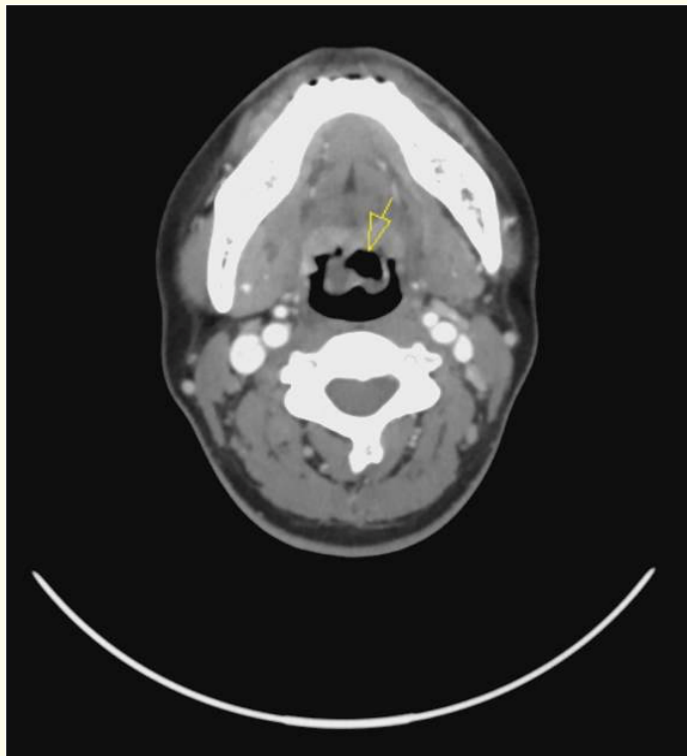


Figure 2: CT neck axial view shows gas filled epiglottis (yellow arrow).

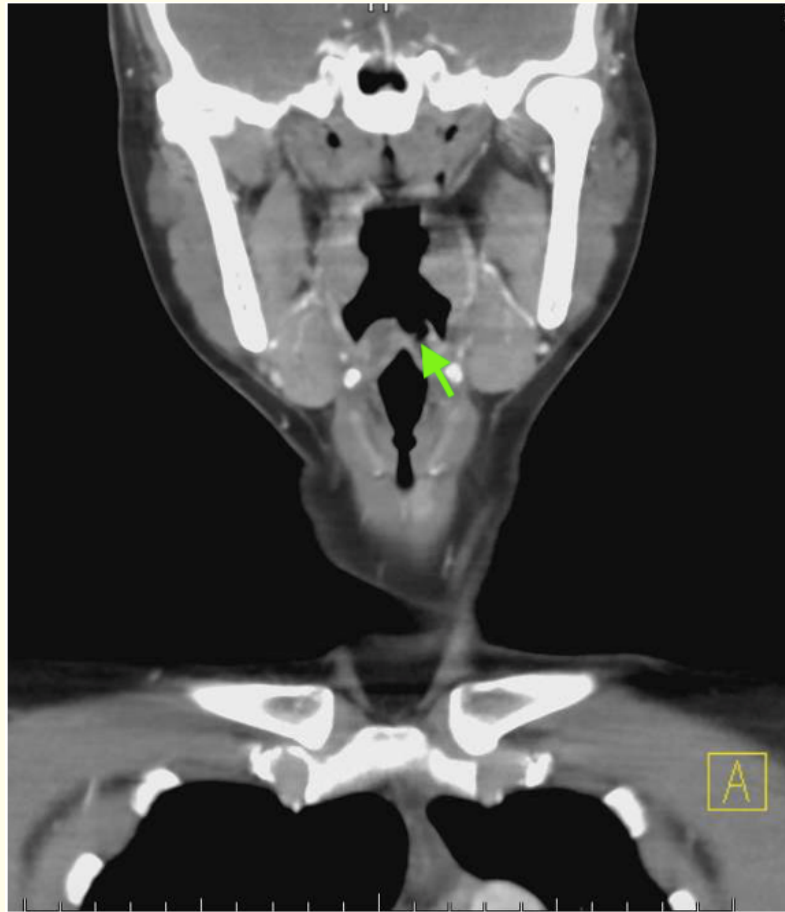


Figure 3: CT neck coronal view shows gas within the epiglottis (green arrow).

Utilizing up-biting cup forceps, a large amount of pus was drained. Because of the degree of edema it was decided to keep the patient intubated for 24 hours.

Wound culture from the drained abscess grew methicillin sensitive *Staphylococcus aureus*, a few α -hemolytic Gram positive cocci, and moderate β -hemolytic Streptococci. She was treated with intravenous ampicillin-sulbactam and dexamethasone along with supportive therapy. After a negative cuff leak test on day 2 of admission she was extubated. She had gradual improvement in dysphagia and throat pain and tolerated soft diet well. She was discharged home on a 10-day course of amoxicillin-clavulanate and continues to do well on follow up.

Discussion

Since introduction of *Haemophilus influenzae* type B immunization, the incidence of pediatric epiglottitis has reduced, however, the incidence in adults has shown a steady increase [3]. The ratio of incidence in children to adults was 2.6:1 in 1980 and dropped to 0.4:1 in 1993 [3]. The incidence in adults is about 1 case per 100,000 per year. It is considered that this increase is due to greater awareness and recognition of the disease in adults. Epiglottitis is more common in males than in females with a ratio approximately 3:1. The average age among adults presenting with acute epiglottitis is 45 years [3-5].

Abscesses occur principally to the lingual surface of the epiglottis probably due to the higher incidence of mucocele on the lingual surface and to the loose mucosal covering of the cartilage [6]. The mortality from epiglottic abscess is about 30% from older literature [6], mainly from asphyxiation by obstruction, abscess rupture or hemorrhage [7] and therefore requires a high level of suspicion, despite its rarity.

The diagnosis of an epiglottic abscess should be considered in any adult presenting with a deglutition disorder due to sore throat, fever, dyspnea, or stridor. Lateral neck radiographs and CT imaging can be suggestive but the prompt and accurate diagnosis is established with the flexible fiberoptic nasopharyngolaryngoscopy. Physical findings that should raise the suspicion of an epiglottic abscess are the epiglottic asymmetry, a yellow-coloured epiglottis, prominent median glossoepiglottic furrow and taut appearing epiglottic mucosa [8].

Management of this condition involves securing the airway early, broad-spectrum intravenous antibiotics, corticosteroids and surgical drainage. The techniques described to secure the airway include intubation in the awake status, after inhalation induction, rapid sequence intubation, fiberoptic bronchoscopic intubation, cricothyroidotomy, or tracheostomy under local anesthesia; of these tracheostomy may be considered to be safest but is associated with prolonged hospitalization [9,10]. There is no clear guideline to recommend any particular technique over the other to secure the airway; choice depends on clinical scenario, and the available expertise. Our patient was intubated in the operating room in a controlled setting prior to micro-surgical drainage.

Conclusions

An epiglottic abscess is a life-threatening collection of pus in the supraglottic region of the oropharynx and may lead to critical upper airway obstruction and asphyxiation. Other complications may include abscess rupture or hemorrhage. Early suspicion in adults is critical. Management of an epiglottic abscess includes airway protection, broad-spectrum intravenous antibiotics, corticosteroids and early surgical drainage.

Conflict of Interest

None.

Bibliography

1. Salman R., *et al.* "Adult epiglottic abscess: A case report". *Indian Journal of Otolaryngology and Head and Neck Surgery* 63.1 (2011): 85-86.
2. Harvey M., *et al.* "Fatal epiglottic abscess after radiotherapy for laryngeal carcinoma". *American Journal of Forensic Medicine and Pathology* 33.4 (2012): 297-299.
3. Mayo-Smith MF., *et al.* "Acute epiglottitis: an 18-year experience in Rhode Island". *Chest* 108.6 (1995): 1640-1647.
4. Ioannis Vasileiadis., *et al.* "Epiglottic abscess causing acute airway obstruction in an adult". *Journal of the College of Physicians and Surgeons Pakistan* 23.9 (2013): 673-675.
5. Barrow HN., *et al.* "Adult supraglottitis". *Otolaryngology-Head and Neck Surgery* 109 (1993): 474-477.
6. Heeneman H and Ward KM. "Epiglottic abscess: its occurrence and management". *Journal of Otolaryngology* 6.1 (1997): 31-36.
7. Cao Y., *et al.* "Asphyxia death caused by epiglottic abscess rupture in an adult: A case report". *Romanian Journal of Legal Medicine* 22 (2014): 233-236.

8. Stack BC and Ridley MB. "Epiglottic abscess: case report". *Head Neck* 17.3 (1995): 263-265.
9. Baxter FJ and Dunn GL. "Acute epiglottitis in adults". *Canadian Journal of Anesthesia* 35.4 (1988): 428-435.
10. Berger G., *et al.* "The rising incidence of adult epiglottitis and epiglottic abscess". *American Journal of Otolaryngology* 24.6 (2003): 374-383.

Volume 8 Issue 2 February 2019

©All rights reserved by Atul Palkar and Ankit Gupta.