

Surgical Treatment of Lung Tuberculosis

Milislavljevic Slobodan^{1,2}, Maric Nebojsa³, Spirovski Zoran⁴ and Spasic Marko^{1,2}

¹Department of Surgery, Faculty of Medical Sciences, University of Kragujevac, Serbia

²Clinic for General and Thoracic Surgery, Clinical Center "Kragujevac", Kragujevac, Serbia

³Clinic for Thoracic Surgery, Military Medical Academy, Belgrade, Serbia

⁴Clinic for Thoracic and Vascular Surgery, University Clinical Center, Skopje, Macedonia

***Corresponding Author:** Milislavljevic Slobodan, Department of Surgery, Faculty of Medical Sciences, University of Kragujevac, Serbia.

Received: May 14, 2018; **Published:** June 28, 2018

Abstract

Tuberculosis is a chronic progressive infection caused by an acid - resistant germs of tuberculosis. Surgical treatment of pulmonary tuberculosis cannot be used without prior medical treatment of anti-tuberculosis treatment. Therefore, surgical treatment is not an independent method, but only one phase in the drug therapy of tuberculosis. The ideal indications for the surgical treatment of lung tuberculosis are the unilateral localization of the disease, the complete stabilization of the disease (primarily in the presence of a bacterial infection), a negative finding of a tuberculosis virus in the spleen, or an occasional finding without resistance and a good general patient condition. Surgical indications in relation to the pathoatomic finding can be absolute and relative. Absolute surgical indications in relation to the pathoatomic finding are: casey hearths (limited to one lobes), tuberculum, filled cavern (closed supply bronchus), primary tuberculosis and enlarged lymph nodes with a predominantly bronchoglandular fistula (perforation of the casein masses in the bronchial system), bronchial stenosis and distal nonspecific or tuberculous bronchiectasis, a tuberculous process in the lungs with a pleural spread. Relative surgical indications refer to conditions that require additional medical treatment or are indicated and usefully apply one of the methods of so - called collapse therapy, and only then evaluate the justification and the possibility of surgical treatment (first of all, it is thought of the use of some of the resection methods or, first resection and then collapse therapeutic methods).

Keywords: Tuberculosis; Tuberculous empyema; Surgery; Treatment; Chest; Indications; VATS

Introduction

Tuberculosis is a chronic progressive infection caused by an acid - resistant germs of tuberculosis (*Mycobacterium tuberculosis*). *Mycobacterium bovis*, *Mycobacterium africanum* and *Mycobacterium microti* can also cause similar disease. In addition to these mycobacteria, there is also a wide spectrum of non - cellular microbacteria, many of which are saprophytic and significant because in some conditions such as HIV infection, they can lead to tuberculosis sickening with a very severe clinical picture, since these bacteria are generally resistant to conventional tuberculostatics. It is estimated that around 1.6 billion people are infected with tuberculosis today, and an active disease will be detected in about 15 million people at a time. In the past, when tuberculosis was widespread in highly industrialized countries, it was possible to prove, by tuberculin testing, that most young people were infected with tuberculosis, but only a small number of patients (10%) developed the disease. Whether the infection goes into the disease depends on the size of the infectious dose and the selected infected person. In some cases, the infection rapidly progresses toward the disease. In other cases, the disease can remain asleep with several "sleeping" bacteria that the body's defense keeps under control. But some later conditions that lead to reduced defenses of the

organism (HIV, malnutrition, age) can allow sleepy germs to reproduce and cause the disease. Tuberculosis is almost exclusively caused by inhalation of droplets that contain *M. tuberculosis*, during speech, coughing or in other conditions when there is an increased involvement of the respiratory system of a person with active pulmonary tuberculosis, whose sputum contains a significant number of samples (typically sufficient for smear to be positive). They are especially infectious with cavernous tuberculosis. Droplets containing tuberculosis bacteria can float in the air for several hours, increasing the possibility of spreading the infection. Patients with a direct positive sputum (*Mycobacterium tuberculosis* visible under the microscope) are much more infectious because they cough up far more germs than those that are positive only in culture. The closer some person is to the patient, the greater the dose of *Mycobacterium tuberculosis* he will likely inhale. Infected urine or feces are theoretically risky, but are less important because they contain relatively few bacteria tuberculosis. [1-3].

Pathophysiology of tuberculosis

After inhalation of tuberculosis germs into the tracheobronchial tree, the tuberculosis bacteria cause a primary infection, followed by a latent period of, in some cases, an active disease. In the primary and latent period, the infection is not contagious.

Primary infection

Droplet tuberculosis germs comes into terminal alveoli, usually subpleural localization, predominantly to the lower part of the lungs, and is usually implanted only in one place in the lungs. Germs tuberculosis is proliferating within the macrophages leading to their destruction, after which migration of inflammatory cells that lead to the formation of tuberculoma and sometimes pneumonitis occur in that part of the body. In the first weeks of the infection, some infected macrophages migrate to the regional node (hilar or mediastinal), and haematogenous dissemination can occur, particularly in the apical lung parts, epiphysis of the bones, the kidneys, the spinal cord and the brain envelope. In 95% of cases, after about 3 weeks of undisturbed growth of the bacteria, the immune system suppresses the propagation of the bacteria before the symptoms or signs of the disease develop. Inflammation of the infection in the lungs or elsewhere is withdrawn without treatment, becoming granulomas built of epithelium cells, the center of which may be caseous necrosis. Germs tuberculosis in this material can survive for years, and the resistance of the host organism determines whether the infection is finally withdrawn without treatment, whether it will remain latent or will be activated. Infections can leave scars in the tops of one or both lungs (Simon's hotspots), calcified scars primary infection (Ghon hotspots) or calcification of the hilar lymph node. Tuberculin skin test is positive. In rare cases, a primary focus may occur, leading to an acute disease with pneumonia (sometimes cavitation), pleural effusion and enlargement of the hilar or mediastinal lymph nodes. Small pleural effusions contain predominantly lymphocytes, as a rule, they contain little cause and withdraw within a few weeks. Primary extrapulmonary tuberculosis can sometimes manifest at any site in the body without signs of lung involvement. Tuberculous lymphadenopathy is the most commonly extrapulmonary manifestation, but the greatest danger is tuberculous meningitis, due to high mortality of very young and very old patients [4-6].

Active disease

In about 10% of patients, latent tuberculosis infection develops in active disease, although the percentage depends largely on the patient's lifespan and other risk factors. In about 50% to 80% of those patients in whom active disease develops, tuberculosis is reactivated in the first two years, but until reactivation of the disease can occur after several tens of years. Each initially affected organ can be the site of reactivation, but reactivation is most commonly occurring in the lungs, where the pressure of oxygen is greatest. The reactivation of Ghon's hotspots and affected hilar lymph nodes is significantly less common. Stomach that relieves reactivation of the disease is damage to the immune system (especially HIV infection), some immunosuppressive drugs (corticosteroids, infliximab and other tumor necrosis factor blockers), gastrectomy, jejunoileal anastomosis, silicosis, renal failure, stress, diabetes, carcinoma of the head and neck, adolescence and older life (especially over 70 years of age). Tuberculosis damages the tissues by a delayed reactions, leading to the formation of granules with histologically visible caseous necrosis. Changes in the lungs are cavitory. Pleural effusion is less common than in progressive primary tuberculosis, but can be due to direct or hematogenic spread. Rupture of large tuberculous changes in the pleural cavity can cause tuberculous empyema pleura, with or without bronchopleural fistula, and sometimes pneumothorax can occur. In the pre - antibiotic era,

the tuberculous pleural empyema sometimes complicated the medical/heterogenic - induced pneumothorax and usually ended with a flight outcome. Acute respiratory distress syndrome (ARDS), thought to be caused by hypersensitivity to tuberculosis antigens, rarely occurs, mainly after hematogenous dissemination or rupture of a large cavern with dissemination to the lung tissue [7].

Diagnosis of tuberculosis

Lung tuberculosis is often suspected based on radiographs of the chest caused by non - specific respiratory symptoms (coughing lasting more than three weeks, haemoptysis, chest pain, difficulty breathing), febrile state of unknown etiology, or positive tuberculin skin test. In adults, a multinodular infiltrate above or behind the key bone may indicate reactivation of tuberculosis. Infiltrates in the middle or lower pulmonary arteries are not specific, but should trigger suspicion of primary tuberculosis in patients (usually young) whose symptoms or history indicate recent non - infection, especially if there is a pleural effusion.

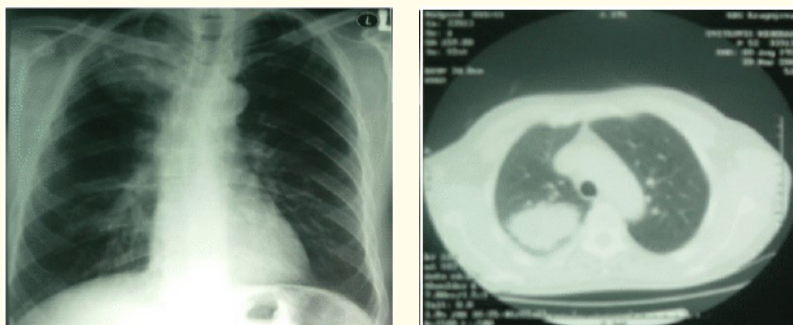


Figure 1: Tuberculous infiltrate of the right upper lobe of the lung (RTG and MSCT).

Initial diagnostic procedures in suspected tuberculosis of the lungs are: radiography of the chest, examination of sputum (staining and cultivation in culture) and tuberculin skin test (PPD). In a person with risk factors for tuberculosis, RTG of the chest is very characteristic (cavitation in the upper lobe), a sputum test is needed, but the skin test is often not performed. Finding acidophore resistant bacteria in the sputum provides a strong assumption that it is a tuberculosis, but for the final diagnosis is sputum culture in a sputum culture or a fast molecular test. The results of a culture may take ≥ 3 weeks, while the search for molecular methods usually takes only a few days. Rapid molecular tests can also detect gene mutations associated with resistance to rifampicin, a major feature of MDR - TBC. In positive cultures, resistance to isoniazid, rifampicin and ethambutol is routinely tested, while along with conventional bacteriological methods, it takes up to eight weeks to obtain the results. Patients who cannot spontaneously cough up, sputum can be caused by inhalation of aerosols of a hypertonic physiologic solution, or bronchial spray, which are a particularly sensitive method, can be obtained by fiberoptic bronchoscopy. In case of infiltrative changes in the liver, transbronchial biopsy should be done and the result should be sent to culture in culture, pathohistological processing and molecular testing. Gut flushes are usually positive, but today they are no longer performed often, except for small children, which usually cannot give a good sputum pattern. Germs tuberculosis is a nominal gram positive, but are bad for coloring by Gram. For conventional light microscopy, the samples are best stained by Ziehl - Neelsen and Kinyoun, or for fluorescent microscopy with fluorescent colors [8,9].

Tuberculin skin test

Usually a tuberculin skin test (tuberculin skin test = TST, Mantoux or PPD - purified protein derivative) is performed, although it is a test that proves the infection, latent or active, and there is no diagnostic value for the active disease. The usual dose of 5 PPDs in 0.1 ml of the solution is injected onto the wool side of the forearm. It is very important that the injection be given intradermally rather than subcutaneously. A well - restricted skin tumor should be created. The induction diameter is measured from 48 to 72 hours after injection. Induction of ≥ 10 mm as a rule means infection with *M. tuberculosis*, but does not indicate its activity. Sometimes, different marginal values are more useful in order to improve the sensitivity and specificity of the method. Induction of ≥ 5 mm is considered a positive finding in HIV - infected patients or in people with radiographic evidence of frozen tuberculosis, or in people who have been in close contact with TB patients, while in patients without risk factors the test is not considered positive until the injection is > 15 mm. Scabies

can be falsely negative, most commonly in febrile patients, elderly patients, or in HIV- infected patients (especially if the number of CD4⁺ cells is <200 cell/ μ L) and in severely affected patients, many of whom do not show a reaction to any skin test (anergy). Anergy is probably due to inhibitory antibodies, or as many T lymphocytes have been mobilized at the site of the disease, so that there is too little to cause a significant skin reaction. Today, there are blood problems that are based on the insertion of gamma - interferon by lymphocytes exposed to tuberculosis - specific antigens *in vitro*, and in the near future, these methods will replace the tuberculin skin test for routine testing for tuberculosis infection [10,11].

The prognosis and treatment of tuberculosis

In immunocompetent patients with pulmonary tuberculosis, which is sensitive to drugs, even when severe disease and large cavitation are recovered quickly, if appropriate treatment is carried out. Tuberculosis leads to fatal outcome in about 10% of patients, mainly in patients with reduced defenses of the organism. Diseased tuberculosis and tuberculous meningitis can be fatal in about 25% of cases, despite adequate treatment. Tuberculosis is much more aggressive in immunocompromised patients and if it is not treated in an adequate manner it can be fatal even within 2 months of the onset of treatment. This is especially common in MDR - TBC, where mortality is up to 90%. Most patients with uncomplicated tuberculosis and all complicated diseases (AIDS, hepatitis, diabetes), adverse drug reactions and drug resistance should be referred to the pulmonologist. However, most patients can be treated at home with education to prevent the spread of the disease. These measures include staying at home, avoiding visits and covering the face with a scarf or hand while coughing. Precautions must be continued for several weeks at the hospital or outside. The main indications for hospitalization are severe clinical picture of the disease, the need for diagnostic procedures and the need for respiratory insulation, as when people live in an overpopulated environment in which they will come in contact with previously unenlightened people. All hospitalized patients must initially have respiratory insulation, preferably in a negative pressure room and 6 to 12 air changes per hour. Drugs for the first choice for the treatment of tuberculosis are: isoniazid (INH), rifampicin (RIF), pyrazinamide (PZA) and ethambutol (EMB) and are administered together in the initial phase of treatment. Isoniazid (INH) is given per axis 1 x day, well penetrates the tissues, including the liquor and is highly bactericidal. It remains the single most effective and cheapest drug for tuberculosis. However, years of uncontrolled use (often one drug, i. e. monotherapy) in many countries increased the percentage of resistant tuberculosis strains. Isoniazid is innocuous in pregnancy. Adverse effects are dizziness, fever, anemia and agranulocytosis. Isoniazid in about 20% of patients causes an increase in aminotransferases and symptomatic (usually reversible) hepatitis in about 1/1000 (more often people over 35 years of age, alcoholics and chronic liver disease patients). Rifampicin (RIF) when given per axis has a bactericidal effect, is well absorbed, penetrates well into cells, and the liquor quickly works. It also destroys dead germs of tuberculosis in macrophages, or by casual hearths that lead to late relapse. Therefore, rifampicin can be used throughout the treatment of tuberculosis. Adverse reactions are cholestatic jaundice (rare), febrile, thrombocytopenia, and renal insufficiency. Rifampicin is non-toxic during pregnancy. Ethambutol (EMB) is given per os, and best suited for all drugs of the first choice. Its main toxicity is expressed as an ocular neuritis, and more often in larger doses and in patients with impaired kidney function. Patients at first cannot distinguish between blue and green, which results in a deterioration in visual acuity. Since both reversible and irreversible are detected early, patients should have basic visual acuity and color recognition tests, and the vision should be controlled every month. If eye neuritis occurs, ethambutol is replaced by another medicine. During pregnancy it can be freely applied. Drugs for the second choice for the treatment of tuberculosis: and other antibiotics are effective against tuberculosis, and are used mainly for MDR-TBC. The two most important groups are: aminoglycosides and fluoroquinolones. Streptomycin, the most commonly used aminoglycoside, is highly effective and bactericidal. It falls poorly into the liquor, and if other drugs are available, it should not be applied intrathecally. Adverse effects include damage to the kidney canal, vestibular and ototoxicity. The dose is about 15 mg 7 kg IM (usually 1g for adults, reduced to 0.5g for elderly > 60 years, persons < 45 kg or those with any degree of renal failure). Patients should be monitored regularly for possible side effects (appropriate equilibrium, hearing, and serotonin levels). Allergic reactions are rash, febrile, agranulocytosis, and serum sickness. Injection is often followed by redness and tingling around the lips, but is rapidly retreating. Streptomycin is contraindicated in pregnancy because it can damage the eighth brain fetus of the fetus. Kanamycin and amikacin can be effective if resistance to streptomycin has de-

veloped. Some fluoroquinolones (levofloxacin, moxifloxacin and gatifloxacin) are the most effective and unsafe drugs against tuberculosis after isoniazid and rifampicin. Other drugs of the second choice are ethionamide, cycloserine and paraaminosalicylic acid (PAS). They are less effective and more toxic than first-line drugs, but are useful for the treatment of MDR - TB. All patients with newly discovered, previously untreated tuberculosis should undergo initial therapy for 2 months, followed by a sustained treatment phase of four to seven months. In the first two months, 4 antibiotics are used: isoniazid, rifampicin, pyrazinamide and ethambutol. After two months, the use of pyrazinamide is terminated and samples for culture and smears are taken. If culture and smear are negative, regardless of radiographs of the chest, or if the culture or smear is positive but no cavitation is seen on the X-ray, the application of isoniazid and rifampicin continues for another four months (six months in total). If cavity radiographs find cavity, and culture and smear are positive, with isoniazid and rifampicin being continued for another seven months (a total of nine months). In any route of administration, ethambutol is discontinued if the antibiogram does not show resistance to any medicinal product. In an extended stage of treatment, medication can be administered daily, two or three times a week. Patients with negative cultures and smears and no chest radiographs that are HIV-negative may be given once weekly isoniazid plus rifapentine. Both in the initial and in the extended treatment phase, the total number of doses (calculated per dose/i.e. multiplied by the number of weeks) must be applied, and if any dose is skipped, the treatment is prolonged. The method of resistant tuberculosis depends on drug resistance. In MDR - TB, prolonged treatment (18 to 24 months) is required with the remaining drugs of the first choice (fluoroquinolone and aminoglycoside or capreomycin). In patients with acute respiratory distress syndrome (ARDS) meningitis or pericarditis, corticosteroid administration has been reported. Adults and children over 25 kg are given dexamethasone 12 mg PO or IV every 6 hours; children with less than 25 kg are given 8 mg. Treatment continues for two to three weeks. Corticosteroids that are required due to other indications do not pose a risk to those with active tuberculosis who receive adequate anti-tuberculosis therapy [12-14].

The role of surgery in the treatment of lung tuberculosis

The correct application of a significant number of drugs in the treatment of pulmonary tuberculosis, and early detection of the disease allows the curable and extended tuberculous pulmonary lesions. Surgical treatment is not an independent method, but only one phase in the drug therapy of tuberculosis. The use of anti-tuberculosis in the preoperative and postoperative phase of treatment allows the success of therapy with low postoperative morbidity and mortality [15].

The failure of drug therapy of tuberculosis

Unsuccessful anti-tuberculosis therapy occurs exceptionally rarely in fresh and properly treated cases. This can happen when the tuberculosis bacillus is primarily resistant to anti-tuberculosis or when there is very pronounced hypersensitivity to these drugs. However, failures in treatment are more likely to occur due to improper or insufficiently long drug use. The failure of treatment is determined on the basis of the positive finding of the tuberculosis virus in the spleen, by the insight into the type, amount, method and duration of the administration of drugs, and by comparing radiographs of the lungs before and during treatment. A conclusion about the failure of medical treatment can be made only after the expiry of at least six months of properly performed therapy. It is recommended that the decision on a surgical procedure be made only after one year of continuous treatment. In such cases, patients with massive hemorrhage from cavernous limited, localized lesions filled with casey masses (for example, tuberculosis) are exception.

Complications or sequelae of cured lung tuberculosis

In the part of lungs where an active tuberculosis process was, there may be a persistent pulmonary (pyogenic) or fungal infection. The most common cause of the emergence of such non - specific infections is incomplete scarring bronchial stenosis (the most common is middle lobe syndrome on the right or syndrome of the lingula in the left lung). As a consequence of a chronic infection in such areas massive haemoptysis may occur, or the development of a mucous membrane of the pleura (empyema), with or without signs of broncho-pleural, pleurocutaneous and bronchopleurocutaneous fistulae. Pulmonary complications are resolved by surgical resection of diseased segments, the lobe or rare and whole lungs. Pleural complications are solved by decortication of the lungs [16].

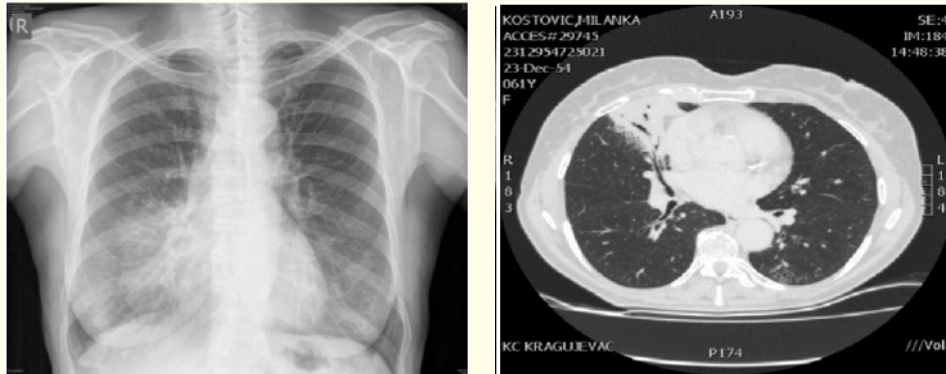


Figure 2: Syndrome of the middle lobe (PA radiography and MSCT of the chest).

Complications of previously performed surgery for the treatment of pulmonary tuberculosis

Patients who need to solve the problems due to previously used so - called collapse methods for the treatment of tuberculosis are rarely found in practice. A special group of patients consists of those who develop complications following pulmonary resection, such as an pleural empyema with or without a bronchopleural or bronchopleurocutaneous fistula. In patients treated with lung tuberculosis or in those who are suspected of this disease, one should never forget the possibility of a co - occurrence of tuberculosis and lung cancer. Such a possibility relates specifically to those patients in whom radiographs have peripheral nodular lesions or in whom early inflammatory lesions (fibrotic lesions) are detected, and that the BK finding is negative in the spleen, and the tuberculin test is positive.

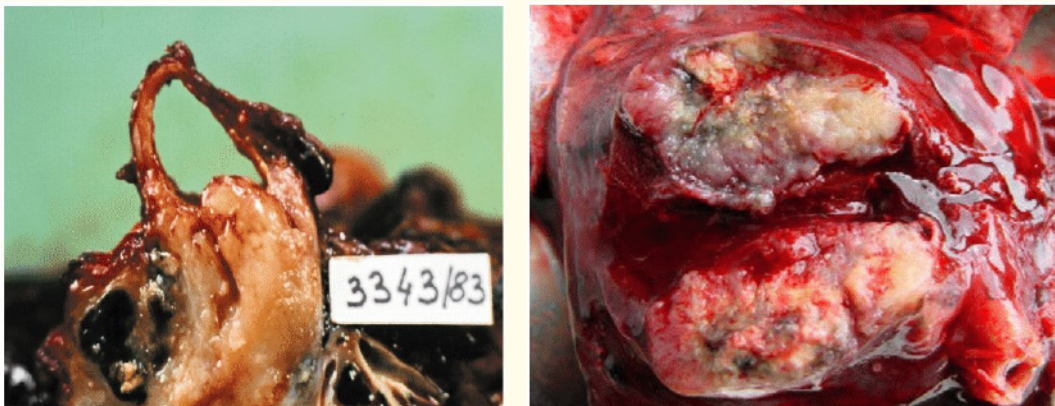

Figure 3: Lung carcinoma on the scar of tuberculosis.

Selection of patients for surgical treatment

The choice of patients for surgical treatment primarily involves estimates that look at the possibilities for preventing further evolution of the disease or the emergence and development of post - operative complications and assessments that accurately determine the degree of disruption of the respiratory function in relation to the volume and type of surgery. According to the surgical criteria, the prospects for the success of surgical treatment can be ideal, reduced or the indications are poor. The ideal indications for the surgical treatment of lung tuberculosis are the unilateral localization of the disease, the complete stabilization of the disease (primarily in the presence of a bacterial infection), a negative finding of a tuberculosis virus in the spleen or an occasional finding without resistance and a good general patient

condition. Any surgical assessment for the operative treatment of pulmonary tuberculosis must be made, inter alia, with respect to the pathoatomic finding. Surgical indications in relation to the pathoatomic finding can be absolute and relative. Absolute surgical indications in relation to the pathoatomic finding are: casey hearths (limited to one lobes), tuberculoma, filled cavern (closed supply bronchus), primary tuberculosis and enlarged lymph nodes with a predominantly bronchoglandular fistula (perforation of the casein masses in the bronchial system), bronchial stenosis and distal nonspecific or tuberculous bronchiectasis, a tuberculous process in the lungs with a pleura emporium. Relative surgical indications refer to conditions that require additional medical treatment or are indicated and usefully apply one of the methods of so - called collapsotherapy, and only then evaluate the justification and the possibility of surgical treatment (first of all, it is thought of the use of some of the resection methods or, first resection and then collapse therapeutic methods). Today, the number of such indications is negligible. Definitive surgical indications are made based on the pathoatomic findings, the evaluation of the evolution of the process, the assessment of the possibilities and justification of further drug treatment, the assessment of the respiratory function, the estimation of the possibility of postoperative administration of antitubercular drugs, the patient's lifespan, and the estimation of the prospects for the success of the intended operation [17-19].

Contraindications for surgical treatment of lung can be absolute and relative

Absolute contraindications are pulmonary emphysema, decompensated cardiac insufficiency, severe respiratory failure, extensive bilateral lung tuberculosis, cachexia, psychosis. Relative contraindications include: lungs tuberculosis in evolution, insufficiently rehabilitated tuberculosis process, fresh bilateralization of the tuberculous process in the lungs, active extrapulmonary localization of the of the tuberculous process, evolutive tuberculosis of the bronchus at the site of the planned resection and suture bronchia. In contemporary conditions, indications for surgical treatment of pulmonary tuberculosis are related to cases: primary tuberculosis, postprimary tuberculosis, tuberculosis sequelae (post - tuberculosis syndrome), tuberculous pleural effusion and tuberculous pleural empyema.

Primary tuberculosis

Primary tuberculosis is a rare indication for surgical treatment. The operation is used to solve the problem of very pronounced extraluminal compression and threatens the acute perforation of enlarged lymph nodes at tracheal or main bronchial levels.

Postprimary tuberculosis

In post - primary tuberculosis, the operation is applied to tuberculoma and cavernous tuberculosis. Diffuse case - site infiltration in the lung without a positive finding of tuberculosis bacteria in a localized sputum in a single lobe and without previous evidence of etiology changes are a rare indication for surgical treatment. Most often, such lesions are detected by exploratory diagnostic thoracotomy, which is induced to exclude the malignant etiology of the disease.

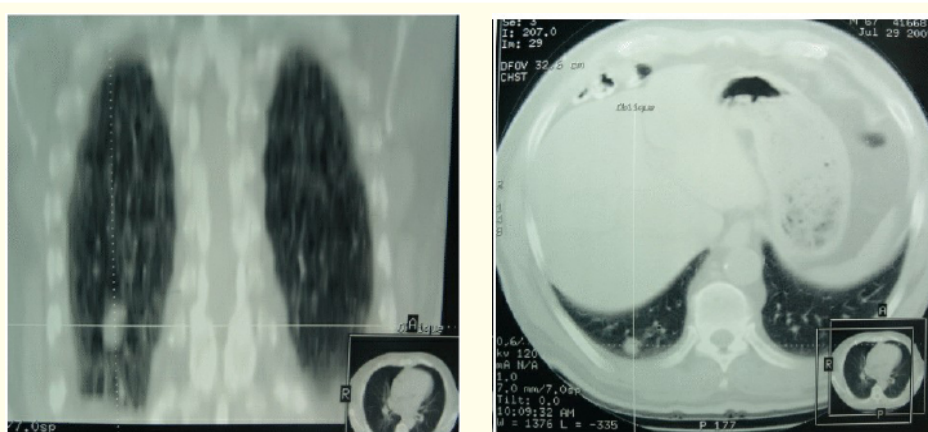


Figure 4: Tuberculoma in the right lower lobe of the lung (RTG and MSCT chest).

Tuberculosis sequence (post - tuberculosis syndrome)

Secondary aspergillosis is most commonly developed from third to twelve years after a sputum conversion has been achieved. It mainly develops in spacious sequelae of previously treated and cured tuberculosis, such as cavities of smooth walls or in the small cavity system in naturally altered lung parts. The reasons for the development of this fungal infection have not been fully clarified, but the development of aspergillosis is considered to be favorable by two groups of factors. On the one hand, these are the general factors of the disorder of the immune defense mechanism of the lungs and the whole organism caused by chronic infection, and on the other hand it is a disturbance of drainage of the bronchial secretion due to the metaplasia of the bronchial mucosa in the plate - layer epithelium. Bronchial stenosis with secondary bronchiectasis is an indication for surgical treatment only when there are massive haemoptysis and recurrent pneumonia, or when secondary aspergillosis is confirmed. It is known for middle lobe syndrome in the right lung and lingua syndrome in the area of the left upper lobe of the lung. Broncho -esophageal fistula as a tuberculosis sequela meets very rarely, but in clinical practice it is considerably more frequent than the complication of lung cancer.

Tuberculous pleural effusion

Tuberculous pleural effusion, when it occurs in the absence of radiographically visible tuberculosis, can present a nasal core of primary tuberculous lung infections occurring 6 weeks or 12 weeks, or may be reactivated by tuberculosis. Tuberculous pleural effusion is the result of the rupture of subplurally localized case - focuses in the lungs. Late hypersensitivity is thought to play a major role in the pathogenesis of tuberculous pleural effusion. The microbacterial cultures of pleural fluid in most patients with tuberculosis pleural effusion are negative. T lymphocytes specifically sensitized to tuberculosis protein are found in pleural fluid. It is not known whether the increased percentage of specifically sensitized lymphocytes in the pleural fluid was due to their clonal expansion or migration of PPD - reactive T lymphocytes in the blood. When lymphocytes of patients with tuberculous pleural effusion are cultivated with PPD, lymphokines are produced. The level of production of lymphokines is much higher in lymphocytes in pleural fluid than in peripheral blood lymphocytes. Second, there may be sequestration of PPD reactive T lymphocytes of the pleural space, including Leu - 2 (suppressor/cytotoxic) and Leu - 3 (assistant) positive T cells. Tuberculous pleural effusion is enriched by many potentially immunoreactive cells and substances that constitute a strong cell - mediated immune response. In comparison with peripheral blood, pleural fluid is rich in T lymphocytes. The relationship between CD4 (helper/induction) to CD8 (supersoric/cytotoxic) is 3: 4 in the pleural fluid, compared to 1:7 in the peripheral blood. It has been observed that the pleural fluid lymphocytes of patients with tuberculous pleuritis show a stronger response to PPD than peripheral blood lymphocytes. Some authors believe that tuberculous pleural effusion is a consequence of a late hypersensitivity reaction that increases the permeability of the pleural capillaries to the proteins, and an increase in the level of proteins in the pleural fluid leads to the appearance of pleural effusion, while other authors consider a strong inflammatory reaction of pleura to interfere with lymphatic drainage from the pleural space and leads to the appearance of pleural effusion, probably both of these mechanisms participate in the pathogenesis of tuberculous pleural effusion. In many parts of the world, tuberculosis remains the most common cause of pleural effusion, especially in immunodeficiency patients, in whom the incidence of tuberculous pleura is very high. Clinically, tuberculous pleural effusion manifest with dry cough, chest pain, loss of appetite and body weight, difficulty breathing, febrile, although normal body temperature does not exclude the existence of a tuberculous pleura. Clinical manifestations of tuberculous pleural effusion are more severe in HIV positive patients. Systemic signs and symptoms such as: night sweats, fatigue, diarrhea, hepatomegaly, splenomegaly and lymphadenopathy are significantly more common in HIV positive patients. The diagnosis of tuberculous pleural effusion is based on RTG of the chest or computed tomography of the chest (CT), where the classic picture of the pleural effusion is seen, while the definitive diagnosis is made by pleural puncture and the analysis of the pleural punctate. Often, the level of pleural fluid protein is above 5 g/dlm, and this finding suggests tuberculous pleural effusion. In most patients, the leukocyte - differentiated pleural fluid (WBC) reveals more than 50% of small lymphocytes. In patients with symptoms lasting less than two weeks, pleural fluid differentiated by the number of leukocytes may exhibit predominantly polymorphonuclear leukocytes. A useful study for the exclusion of tuberculous pleuritis is the analysis of pleural fluid on

mesothelial cells. Four separate studies have confirmed that pleural fluid in patients with tuberculous pleuritis rarely contains more than 5% of mesothelial cells. Today, the level of adenosine deaminase (ADA) is used for the diagnosis of tuberculous pleural effusion. Adenosine deaminase is an enzyme that catalyzes the conversion of adenosine into inosine. ADA is T lymphocyte enzyme and its plasma activity is high in diseases in which cellular immunity is stimulated. Numerous studies have shown that the level of adenosine deaminase of the pleural fluid is higher in patients with tuberculous pleuritis than in patients with other types of pleural effusion. Another useful test for the diagnosis of tuberculous pleuritis is the level of interferon gamma in the pleural fluid. Interferon gamma produces CD4 + lymphocytes of patients with tuberculous pleuritis. Patients with tuberculous pleural effusion tend to have higher levels of interferon gamma in the pleural fluid than patients with pleural effusions of another etiology. In recent years, the possibility of diagnosing tuberculous pleural effusion by measuring the level of tuberculous antigens or specific antibodies to tuberculous proteins of pleural fluid has been investigated, but the results of these studies are still not reliable enough. Other chemical analysis of pleural fluid have a limited value in diagnosing tuberculous pleural effusion. Although in the past, the level of pleural fluid glucose was thought to be diminished in most cases of tuberculous pleural effusion, recent studies show that the majority of patients with tuberculous pleuritis have a pleural fluid level above 60 mg/dL. Also, a low pH of pleural fluid has sometimes been indicative of tuberculous pleural effusion, and tuberculous effusion patients have a lower pH of pleural fluid than those with malignant effusion, but recent studies suggest that the pH of the pleural fluid has approximately the same distribution in malignant as well in tuberculous pleural effusions. The mean C-reactive protein (CRP) is higher in tuberculous effusion than in other exudative effusions. Measurement of the level of pleural fluid lysosomes was proposed as a useful diagnostic test because it was observed that the median level of lysosomal levels in the pleural fluid of patients with tuberculous pleural effusion is higher than in other exudative pleural effusions. In the last few decades of diagnosis of tuberculous pleural effusion, it is most commonly referred to as a pleura biopsy, whether it is a radio biopsy of various needles (Abrams, Cope), or video - Assisted Thoracic Surgery (VATS), which today is considered a golden standard for determining the etiology of any code the pleural effusion and the tuberculous. We can say that today percutaneous pleural biopsy is only applied in patients in a poor general condition who cannot tolerate general anesthesia, whereas in the vast majority of patients today, Video - Assisted Thoracic Surgery (VATS) is applied.

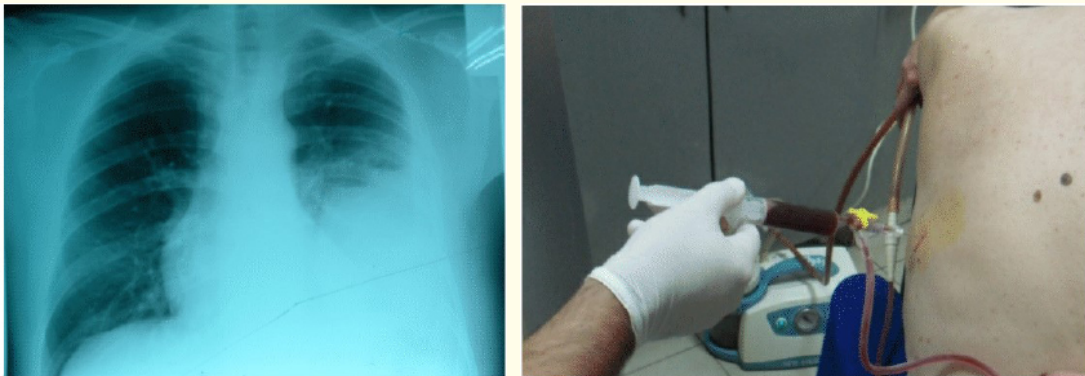


Figure 5: Tuberculous pleural effusion on the left, pleural puncture on the left.

Video - Assisted Thoracic Surgery (VATS) is a minimally invasive method for endoscopic instrumental exploration of intrathoracic lesions by access through small intercostal incisions. A video camera, which is connected to a standard surgical endoscope, allows the surgeon a two -dimensional visualization of the operating field on the monitor. Surgeon cures videoendoscope and endoscopic instrumentarium directly into the pleural cavity and to the pathoatomic substrate. Video - Assisted pleural biopsies are performed in general anesthesia by intubation of patients by a two - channel endobronchial tubus, which allows ipsilateral lung collapse for intervention. The

preparation of the operating field is externally the same as for standard thoracotomy. The patient is in the position of the lateral decubitus, as for posterolateral thoracotomy, but with an elevated arm for easier access to space limited by the topographic lines of the axillary region. Access to the thoracic cavity is through intercostal spaces through small incisions in which the thoracoscope, video camera and additional instruments, pliers, scissors, staplers, needle holders aspirator, instruments for retraction of the lungs and others are placed. The material obtained by biopsy of the parietal pleura is sent for analysis, which in most cases sets the diagnosis of tuberculous pleuritis.

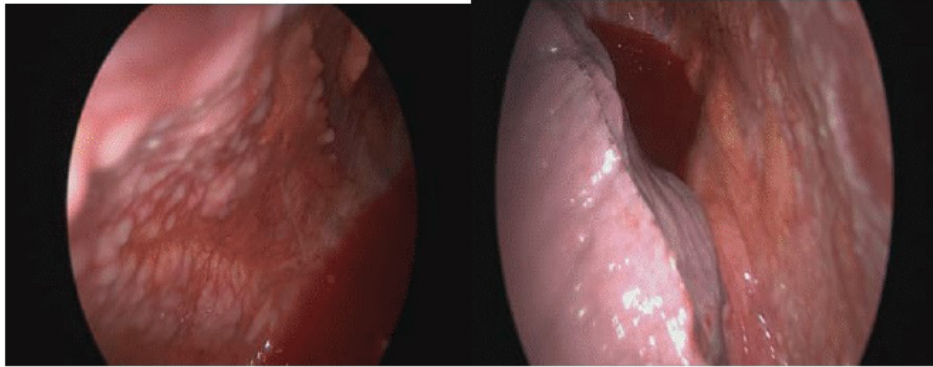


Figure 6: VATS in the diagnosis of tuberculous pleural effusion.

The treatment of tuberculous pleuritis has three objectives: to prevent the subsequent development of active tuberculosis, to alleviate the symptoms of the patient and to prevent the development of fibrothorax. After diagnosis, a six month treatment is started that involves the use of isoniazid, rifampicin and pyrazinamide for a period of two months, after which the isoniazid and rifampicin are given within the next four months. With this treatment, the symptoms and radiographic signs of tuberculous pleural effusion are gradually lost. The average patient becomes afebrile within two weeks, but high temperature jumps can last up to two months. If therapeutic pleural function is performed at the same time as anti-tuberculosis therapy is induced, most patients become afebrile within five days. The average duration for complete resorption of pleural fluid is about six weeks, but may take up to twelve weeks. Patients should be isolated only if their sputum is positive for the microbacteria. In patients with localized tuberculous pleural effusion, intrapleural administration of fibrinolytic agents can reduce the degree of pleural thickening. If the patient is disposable due to a large pleural effusion, a pleural puncture should be applied. Surgery should not be included early until a pleural thickening occurs. Although the pleura can thicken when the patient is diagnosed for the first time, the thickening is reduced by treatment, and decortication should not be considered until the patient has undergone treatment for at least six months. After this period of observation, decortication is rarely needed. Decontamination should only be applied if the quality of life of a patient is diminished by dyspnoea [20,21].

Tuberculous bronchopleural fistula

Tuberculous bronchopleural fistula is a rare complication of tuberculosis today, as most tuberculosis patients are successfully treated with anti-tuberculosis therapy. These fistulas are commonly seen in patients with old, healed tuberculosis and especially in patients with previously treated pneumothorax who have never been treated with anti-tuberculous therapy. When such patients develop a bronchopleural fistula, sputum production increases, and sometimes bacterial superinfection occurs. The diagnosis is made by finding the level of fluid in the pleural area, especially if the level varies in the serial radiographs of the chest. The fistula can be confirmed by injection of methylene blue into the pleural space, and then it is observed whether the color appears in the sputum or tracheobronchial tree. Definitive diagnosis is established by bronchoscopy. Tuberculous bronchopleural fistula is a very dangerous complication of tuberculosis

because communication between bronchial tree and pleural space allows bacteria to enter the pleural area and cause infection of the pleura. In addition, when bacterial superinfection occurs, the patient can very often receive fulminant pneumonia caused by the entry of infectious material from the pleural space to the rest of the tracheobronchial tree. This is of particular importance because tuberculous germs in the pleural area are most likely to become resistant to anti-tuberculous drugs. The initial treatment of a tuberculous broncho-pleural fistula should be the application of appropriate anti-tuberculous chemotherapy, with the drainage of the pleural space. Thoracic drainage eliminates the risk of contralateral lung contamination by infected pleural fluid and the systemic toxicity of bacterial infection is controlled. Before attempting to perform definitive surgical procedures, the patient should be administered anti-tuberculous therapy for ninety to one hundred and twenty days, or until the sputum analysis is negative for tuberculosis bacillus. Definitive surgical treatment involves the decortication of pleura, which can sometimes be combined with thoracoplasty, since the pulmonary parenchyma is usually so damaged that complete re-expansion of the lungs cannot be achieved. Decortication of pleura is a serious surgical procedure with high perioperative morbidity and mortality that can go up to 20% [22,23].

Tuberculous pleural empyema

Tuberculous pleural empyema is today a rare clinical entity characterized by the presence of pus in the pleural area. Pus content in the pleural area is rich in tuberculous germs. Tuberculous empyema pleura usually develops in the fibrous scar tissue that occurs as a result of disease, artificial pneumothorax, or thoracoplasty. Usually occurs as a subacute or chronic disease characterized by general weakness and malabsorption, fatigue, subfebrile temperature and loss of appetite and body weight. In some, mainly untreated cases, pus from the pleural space can be ruptured through the chest wall to the outer environment, and thus a condition is identified that is designated as empyema necessitatis (pleurocutaneous fistula). Radiographically, there may be evident pleural effusion, but often radiographs of the chest show only pleural thickening.

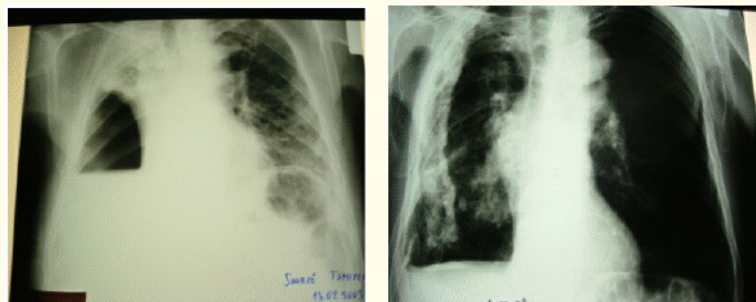


Figure 7: a) tuberculous pleural empyema on the right.
b) after thoracic drainage of the empyema - fibrothorax on the right.

Computerized tomography of the chest usually shows the thickening or calcification of the pleura, the thickening of the rib that surrounds the pleural fluid. Diagnosis is made by pleural puncture and the finding of thick pus in a punctate in which tuberculosis is proven.

The treatment of tuberculous empyema is long lasting and it must be persistent. The main goal of the therapy is to achieve control of the infection in the empyema cavity, often in the lungs, and to achieve the sterilization of the empyema cavity by removing the pus. The ultimate goal of the therapy is that the lungs expand, the empirical syringe is reduced and the obliterate of the empyema cavity is prevented with the eradication of the focal area. In most patients, cure is achieved by the use of pleural punctures, or by permanent active aspiration drainage. In all patients, anti-tuberculosis drug therapy is continuously applied and it continues even after the goals of the therapy are achieved. Surgical treatment of tuberculous pleural empyema is achieved by the decortication of the lung which is used in a smaller number of patients. By decortication, the empirical collection and cavity are removed by thick fibrotic deposits. Indications for lung decortication are strict and limited. The preoperative assessment is focused on the condition of the pulmonary lesions in the diseased lung and the functional state of the opposite lung. The best results are achieved under the condition that the lungs are healthy and able to fully spread, and the necessary prerequisite for the success of the operation is to maintain the function of the diaphragm [24,25].

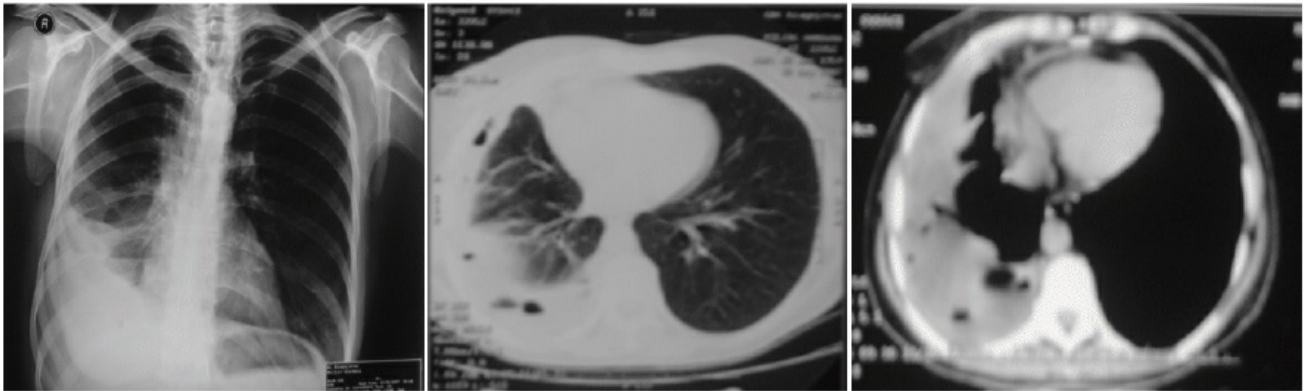


Figure 8: Right - side tuberculosis empyema (RTG and MSCT of the chest).

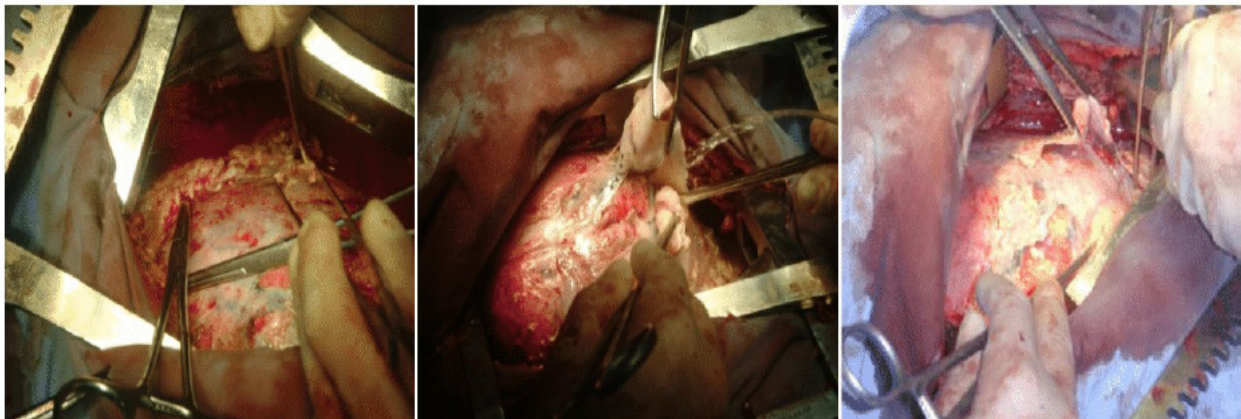


Figure 9: Decortication in the treatment of tuberculous empyema.

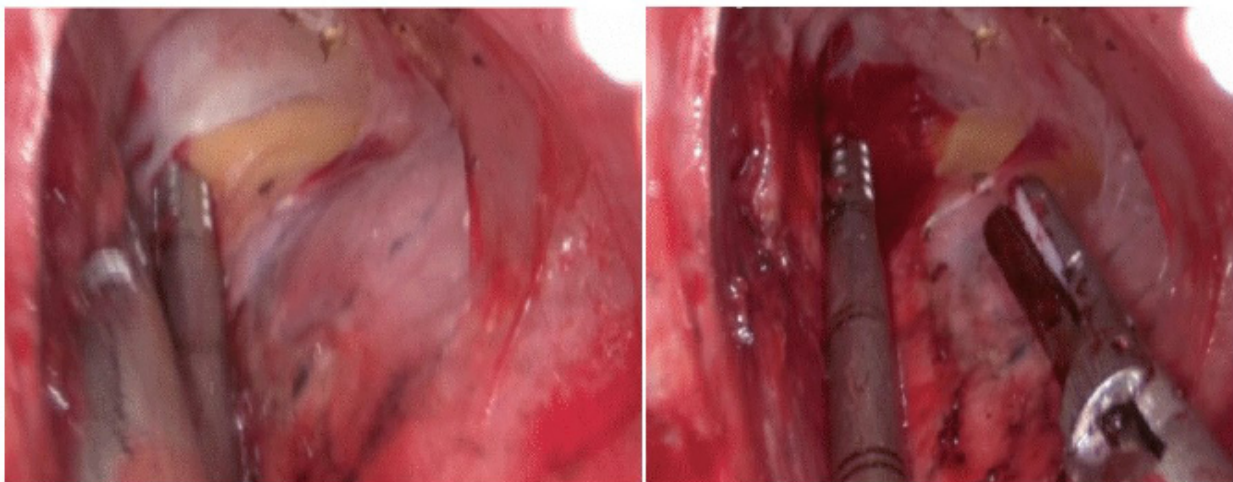


Figure 10: VATS decortication for tuberculous empyema.

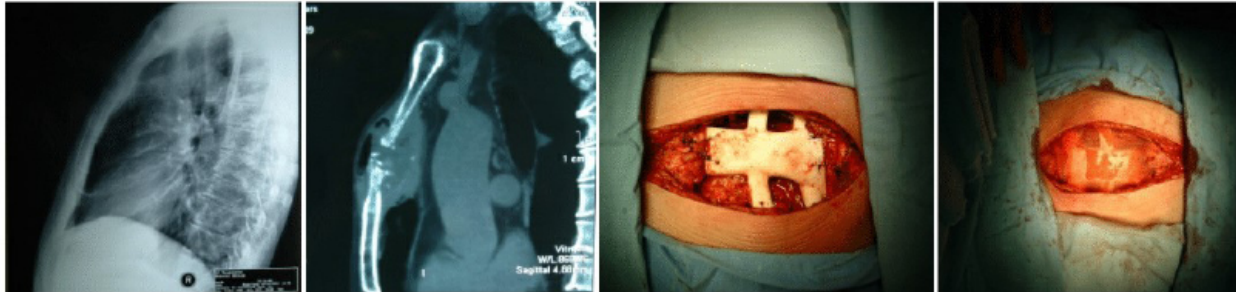


Figure 11: Tuberculosis of the sternum (RTG and MSCT of the chest), resection and reconstruction of sternum with anatomical methyl acrylate implant.

Results of surgical treatment of lung tuberculosis

In the surgical treatment of pulmonary tuberculosis, resection of diseased lung parts is most often applied. Resection may include a small part of the pulmonary tissue in the extreme peripheral localization and a lesion of diameters up to 2 centimeters (atypical or wedge resection), one or two segments (segmentectomy), pulmonary lobes (lobectomy), or even whole lung (pneumonectomy), or pleuropneumonectomy, when resection of the parietal pleura is included. After any resection, careful bronchial sutures are required, regardless of their dimensions. In such a way, the formation of a bronchopleural fistula is prevented. The main goal of each operation is radicality, and at the same time preserving as much functional lung parenchyma as possible. Postoperatively it is necessary to continue controlled treatment with anti-tuberculosis from the first postoperative day. The length of postoperative therapy depends on the preoperative, intraoperative and postoperative pathohistological and bacteriological findings, and it is recommended that it lasts for at least 9 - 12 months. The choice of anti-tuberculosis depends on the finding of resistance of tuberculosis isolated on Low and later from the operative preparation. A sample for sowing on Low - Basin from the operative preparation is taken immediately after its extirpation. Post - operative difficulties after surgery due to lung tuberculosis are in the bone with the occurrence of slow retardation of the remaining lungs, excessive bleeding, the development of bronchopleural fistula and the occurrence of postoperative infection. The results of surgical treatment of tuberculosis are good, with a mortality rate below 1%. Recurrences occur in about 2 - 3% of cases after surgery. Surgical treatment of lung tuberculosis should only be applied when the previously correctly performed anti-tuberculous therapy has been left without effect. Today, surgical treatment of tuberculosis is rarely indicated, but the decision on surgery should not be delayed if there are reasons for its implementation. The chronic tuberculosis process in its evolution causes severe cirrhosis in the lungs which prevent the cavity's healing and closure. Therefore, the effectiveness of treatment with anti-tuberculosis is crucial in the first two months. The goal of the treatment should be rehabilitation of the cavern and prevention of fibrotic transformation of peribronchial and pericardial tissue, as well as prevention of the formation of extensive adhesions in the area of the tuberculosis caverna. Preservation of elasticity of the pericardial pulmonary parenchyma allows rapid collapse and disappearance of the cavern. This prevents the formation of cavernous smooth walls and the possibility of subsequent complications (fungal infection, bleeding). When the presence of cavernous thick walls that persists for a prolonged period of controlled treatment is detected, it is not justified to continue further therapy but to approach surgery. The results of surgical treatment of tuberculosis depend primarily on the choice of the patient to be operated [26-30].

Conclusion

The successes in the medicament treatment of pulmonary tuberculosis have been influenced by the fact that surgical treatment of this disease is rarely applied today. Surgical treatment of pulmonary tuberculosis cannot be used without prior medical treatment of anti-tuberculosis treatment. Surgical treatment is indicated when surgery can be assessed that the failure of anti-tuberculous drug therapy can be solved, which has not achieved the cure of tuberculous changes in the lungs, complications, or the treatment of the cerebral tuberculosis cure.

Acknowledgement

This study was partially financed by grant III 41007 and III 41017, given by Serbian Ministry of Education, Science and Technical Development.

Bibliography

1. Lönnroth K, *et al.* "Tuberculosis control and elimination 2010-50: cure, care, and social development". *Lancet* 375.9728 (2010): 1814-1829.
2. Bustamante-Montes LP, *et al.* "Predictors of death from pulmonary tuberculosis: the case of Veracruz, Mexico". *International Journal of Tuberculosis and Lung Disease* 4.3 (2000): 208-215.
3. Hargreaves JR, *et al.* "The Social Determinants of Tuberculosis: From Evidence to Action". *American Journal of Public Health* 101.4 (2011): 654-662.
4. Johansson E, *et al.* "Gender and tuberculosis control Perspectives on health seeking behaviour among men and women in Vietnam". *Health Policy (New York)* 52.1 (2000): 33-51.
5. Korhonen V, *et al.* "Recurrent tuberculosis in Finland 1995-2013: a clinical and epidemiological cohort study". *BMC Infectious Diseases* 17.1 (2017): 721.
6. Rojas-Alvarado Mde L, *et al.* "Association of pulmonar tuberculosis with HLA system antigens in Northeastern Mexico". *Gaceta Medica de Mexico* 144.3 (2008): 233-238.
7. Vieira Pascual MC, *et al.* "Epidemiological and clinical study of patients diagnosed with tuberculosis in the northeastern area of Madrid". *Anales de Medicina Interna* 20.1 (2003): 10-15.
8. Bonadonna LV, *et al.* "Why wait? The social determinants underlying tuberculosis diagnostic delay". *PLoS One* 12.9 (2017): e0185018.
9. Caminero Luna JA. "Update on the diagnosis and treatment of pulmonary tuberculosis". *Revista Clínica Española* 216.2 (2016): 76-84.
10. Dobler CC and Murad MH. "Interpreting diagnostic tests with continuous results and no gold standard: a common scenario explained using the tuberculin skin test". *Evidence-Based Medicine* 22.6 (2017): 199-201.
11. de Lima Corvino DF and Kosmin AR. "Tuberculosis, Screening". StatPearls. Treasure Island (FL): StatPearls (2017).
12. Pfannschmidt J and Schönfeld N. "Interdisciplinary Treatment of Patients with Pulmonary Tuberculosis". *Zentralblatt für Chirurgie* 142.S01 (2017): S53-S65.
13. Shepherd JG and Chapman ALN. "Assessment and management of active and latent TB". *Practitioner* 260.1798 (2016): 21-24.
14. Chushkin MI and Ots ON. "Impaired pulmonary function after treatment for tuberculosis: the end of the disease?" *Jornal Brasileiro de Pneumologia* 43.1 (2017): 38-43.

15. World Health Organization. "The role of surgery in the treatment of pulmonary TB and multidrug- and extensively drug-resistant TB".
16. Chan ED, et al. "Treatment and outcome analysis of 205 patients with multi-drug-resistant tuberculosis". *American Journal of Respiratory and Critical Care Medicine* 169.10 (2004): 1103-1109.
17. Pomerantz BJ, et al. "Pulmonary resection for multi-drug resistant tuberculosis". *Journal of Thoracic and Cardiovascular Surgery* 121.3 (2001): 448-453.
18. Yamada K, et al. "A study of surgical treatment for patients with mycobacterium abscessus pulmonary disease and a comparative examination of mycobacterium avium complex disease". *Kekkaku* 90.3 (2015): 407-413.
19. Cummings I, et al. "Surgery and tuberculosis". *Current Opinion in Pulmonary Medicine* 18.3 (2012): 241-245.
20. Hsu KY, et al. "Value of video-assisted thoracoscopic surgery in the diagnosis and treatment of pulmonary tuberculoma: 53 cases analysis and review of literature". *Journal of Zhejiang University Science B* .5 (2009): 375-379.
21. Han Y, et al. "Surgical treatment for pulmonary tuberculosis: is video-assisted thoracic surgery "better" than thoracotomy?" *Journal of Thoracic Disease* 7.8 (2015): 1452-1458.
22. Montez ASJ, et al. "Bronchopleurocutaneous fistula: a rare complication of pulmonary tuberculosis". *Acta Médica Portuguesa* 28.2 (2015): 260-262.
23. Ghalimi J, et al. "Tuberculous pleuro-cutaneous fistula". *International Journal of Clinical Medicine* 6.7 (2015): 506-511.
24. Aylk S, et al. "Tuberculous abscess on the chest wall". *Monaldi Archives for Chest Disease* 71.1 (2009): 39-42.
25. Sahn SA and Iseman MD. "Tuberculous empyema". *Seminars in Respiratory Infections* 14.1 (1999): 82-87.
26. Byun CS, et al. "Early and Long-term Outcomes of Pneumonectomy for Treating Sequelae of Pulmonary Tuberculosis". *Korean Journal of Thoracic and Cardiovascular Surgery* 45.2 (2012): 110-115.
27. Kerti CA, et al. "The role of surgery in the management of pleuropulmonary tuberculosis - seven years' experience at a single institution". *Interactive Cardiovascular and Thoracic Surgery* 8.3 (2009): 334-337.
28. Laisaar T, et al. "Long-term follow-up after thoracoscopic resection of solitary pulmonary tuberculoma". *Indian Journal of Tuberculosis* 61.1 (2014): 51-56.
29. Yen YT, et al. "The role of video-assisted thoracoscopic surgery in therapeutic lung resection for pulmonary tuberculosis". *Annals of Thoracic Surgery* 95.1 (2013): 257-263.
30. Opanasenko NS, et al. "Video-assisted pulmonary resection application for pulmonary tuberculosis". *Klinicheskaia Khirurgiia* 8 (2016): 40-43.

Volume 7 Issue 7 July 2018

©All rights reserved by Milisavljevic Slobodan, et al.