

Broncho-Pericardial Fistula with Air Tamponade – A Rare but Lethal Condition

Abhijeet Shelke*

Head of Department of Cardiology, Krishna Institute of Medical Sciences, Maharashtra, India

***Corresponding Author:** Abhijeet Shelke, Head of Department of Cardiology, Krishna Institute of Medical Sciences, Maharashtra, India.

Received: January 04, 2018; **Published:** March 05, 2018

Abstract

Broncho-pericardial fistula involves communication between tracheobronchial tree and pericardium. It is an uncommon condition. Tension pneumopericardium (air tamponade) due to broncho-pericardial fistula is a rare and often lethal complication. Patients surviving with this condition are rare and there are very few reported cases in the literature. Although treatment options are limited, prompt diagnosis and early intervention may save patient's life.

Keywords: *Broncho-Pericardial Fistula; Air Tamponade; Transpericardial Intervention*

Abbreviation

BPF: Broncho-Pericardial Fistula

Introduction

Pneumopericardium, first described by Bricheteau in 1844 is a rare condition. It is defined as the presence of air or other gases in the pericardial sac. A broncho-pericardial fistula (BPF) is an uncommon entity and one of the etiologies for developing pneumopericardium. This condition is not discussed in most of the standard textbooks and literature. It can be spontaneous or iatrogenic, secondary to procedures such as bronchoscopy and transbronchial biopsy [1]. This condition may not cause significant symptoms. However; rarely it may progress to air tamponade leading to cardiovascular collapse.

BPF involves communication between tracheobronchial tree and pericardium. Air enters in the pericardium leading to pneumopericardium. The BPF causing tension pneumopericardium or air tamponade resulting from air trapping is rare [2]. There are very few survival reports of air tamponade in the literature. Prompt diagnosis and early intervention are important. Treatment options are limited. One of them is immediate needle aspiration and insertion of a tube for continuous pericardial drainage.

Clinical Presentation and Discussion

If pneumopericardium is small, the patient may be asymptomatic or may present with a cough. Clinical examination may be unremarkable. Larger pneumopericardium may lead to shortness of breath and chest pain.

Air Tamponade occurs if the significant amount of air is accumulated in short time or a large amount of air accumulated slowly. Study has shown that hemodynamic disturbances occur when intrapericardial pressure exceeds 145 mm of water. The patient may be tachypneic and/or hypotensive. Pulsus Paradoxus may be recorded as a sign of air tamponade. Heart sounds are usually diminished. Chest Auscultation may reveal systolic crunching, rasping sound synchronous with heart beat called as Hamman's sign. The sign was first described by Louis Hamman in 1939 and considered to be pathognomonic for pneumomediastinum. Later it was observed in the cases of pneumopericardium also. It is caused by displacement of the air in the pericardium during systole and diastole of heart. Air tamponade can cause hemodynamic collapse and death in an extremely short period of time.

Aetiopathogenesis

Air tamponade in the setting of BPF occurs due to ball valve mechanism, wherein air from tracheobronchial tree gets trapped in pericardial space. Reported causes of BPF leading to air tamponade include following:

1. **Bronchogenic carcinoma:** Direct pericardial invasion from necrotic bronchogenic carcinoma can lead to communication between bronchus and pericardium [3-5].
2. **Infections:** Necrotizing respiratory infections like tuberculosis, invasive pulmonary aspergillosis, histoplasmosis, staphylococcal infections are known to cause broncho-pleura fistula. However rarely it opens into pericardium leading to BPF [6-8].
3. **Trauma:** A penetrating injury causing the communication between the bronchus and the pericardium can cause BPF and air tamponade. This condition should not be missed in patients with chest trauma as it may cause death in short period [9].
4. **Iatrogenic:** There are reported cases of BPF due to diagnostic procedures like transbronchial biopsy [1,3,10] and Cardiothoracic surgeries like lung resection, coronary artery bypass graft surgery [11]. Barotrauma caused by positive pressure ventilation can also lead to the BPF especially in neonates.

Diagnostic methods

BPF should be suspected when the pneumopericardium is evident on the chest X-ray. Chest X-ray (PA view and/or lateral chest x-ray) may show “halo sign, small heart sign, flattened heart sign” suggestive of air around the heart (Figure 1). It is a simple tool to diagnose pneumopericardium. ECG may reveal non-specific ST-T changes and low voltage pattern in air tamponade [12]. 2D Echocardiography may reveal interesting “air gap sign” described by Reid, *et al.* in 1983 [13]. This occurs because air accumulates in the anterior pericardium during the cardiac systole and gets displaced from anterior pericardium in late diastole. As air is a bad conductor of ultrasound, there is an echo drop out posteriorly during the cardiac systole and in late diastole there is a visualization of cardiac structure. This cyclic appearance of imaging is called as “air gap sign”.

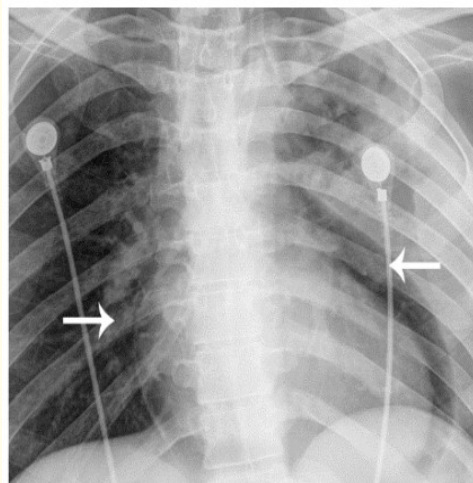


Figure 1: X-ray chest showing “halo sign” suggesting air in pericardial space (white arrows).

Although X-ray Chest and 2 D echocardiography diagnose air in pericardium, both cannot demonstrate BPF as its cause. CT chest can help in diagnosing small pericardial air collection or even can visualize BPF directly [14]. Chest CT can be useful to define the underlying disease and to determine the number and location of BPFs which helps in managing these patients. Iodinated Contrast injection in pericardial space can also delineate BPF track and help in deciding treatment strategy [3,6] (Figure 2).

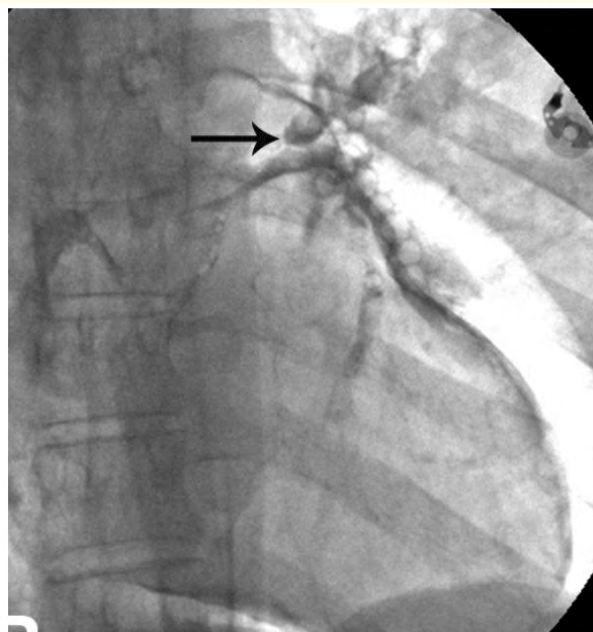


Figure 2: Visualization of BPF after injecting Iodinated contrast into the pericardial cavity. The contrast entered left upper lobe bronchus (black arrow) suggesting communication between pericardial space and left upper lobe bronchus.

If the patient with pneumopericardium deteriorates on mechanical ventilation or if pericardial drainage tube drains air synchronously with mechanical inspiration, BPF should be suspected [6,12].

Treatment

There are no specific guidelines to treat this condition. The BPF should be suspected in patient with pneumopericardium. The condition should be strongly suspected in patients with lung carcinoma, necrotizing lung infections or post endo-bronchial procedure. Chest X ray is easily available and simple tool to diagnose pneumopericardium. However CT scan of chest should be performed to confirm diagnosis of the BPF if patient's hemodynamic status permits.

Once the BPF with air tamponade is diagnosed; prompt attempt to decompress the pericardial space should be made. Treatment is frequently unsuccessful due to intra-operative hemodynamic instability and complex anatomy. Initially, traditional therapy like needle aspiration or tube decompression can be attempted in an emergency with or without fluoroscopy guidance. This approach may not be successful especially when there is a large communication as air may reaccumulate in pericardial space fast. If this fails, surgical interventions like Video assisted Thoracoscopy guided pericardial window [15] or emergency mini-thoracotomy and cut in the pericardium [5] may be life saving. Making large cut or hole in the pericardium helps draining air effectively. Surgical intervention also gives opportunities to explore the cause of the BPF and closing the BPF in same setting.

If the patient is too sick for the emergency surgery, attempt to seal the fistula should be made along with decompressing pericardial space by non-surgical methods. Treatment directed towards closing the BPF may be more easily undertaken if the fistula is directly imaged. Bronchoscopic closure of the BPF with covered stent or tissue sealants can be attempted in such sick patients. Placement of the covered stent across the fistula under bronchoscopic vision can close the BPF [16]. There are published reports of closure of the bronchopleural fistula with the use of tissue sealants or glue [17]. Similarly, glue can be applied near opening and surrounding area of the BPF bronchoscopically to close it.

However, finding BPF on bronchoscopy is challenging. Innovative procedure like trans-pericardial intervention reported by shelke, *et al.* [3] can be another option. Author demonstrated that BPF can be visualized by injecting iodinated contrast in pericardial space. Selective cannulation of BPF through pericardial space and closure of fistula with vascular plug is possible. Management of the BPF with air tamponade underlines that; all efforts should be made to get rid of air from pericardium and to close the fistula if possible.

Conclusion

BPF with air tamponade is a rare condition. At times diagnosis of BPF may be difficult unless this rare condition is clinically suspected. Once diagnosed, prompt intervention is needed as it is associated with high mortality rate in short time. Treatment options reported in literature are limited. Immediate decompression of pericardial space along with all attempts to close the fistula should be made.

Bibliography

1. Sugiyama S., *et al.* "A Dumon stent inserted for bronchial stenosis causing a left bronchopericardial fistula: report of a case". *Surgery Today* 28.10 (1998): 1091-1094.
2. Golota JJ., *et al.* "Air tamponade of the heart". *Kardiochirurgia i Torakochirurgia Polska* 13.2 (2016): 150-153.
3. Shelke AB, *et al.* "A case of bronchopericardial fistula with tension pneumopericardium closed successfully by transpericardial intervention: A novel procedure". *Catheterization and Cardiovascular Interventions* 190.7 (2017): 1117-1120.
4. George LD., *et al.* "Bronchogenic carcinoma presenting as a bronchopericardial fistula". *International Journal of Clinical Practice* 53.2 (1999): 147-148.
5. Kubisa A., *et al.* "Pneumopericardium as a non-small-cell lung carcinoma complication". *Kardiochirurgia i Torakochirurgia Polska* 13.3 (2016): 257-259.
6. Arab AA., *et al.* "Broncho-pleuropericardial fistula complicating staphylococcal sepsis". *Saudi Journal of Anaesthesia* 5.4 (2011): 434-437.
7. Owens CM., *et al.* "Bronchopericardial fistula and pneumopericardium complicating invasive pulmonary aspergillosis". *Clinical and Laboratory Haematology* 12.3 (1990): 351-354.
8. Devasia AJ., *et al.* "Broncho-Pericardial Fistula Leading to Pneumopericardium Following Allogeneic Stem Cell Transplantation". *Indian Journal of Pediatrics* 83.10 (2016): 1206-1207.
9. Visser F., *et al.* "Pneumopericardium: two case reports and a review: case report". *Southern African Journal of Anaesthesia and Analgesia* 14.2 (2008): 41-45.
10. Quin EM., *et al.* "Iatrogenic pneumopericardium and cardiac tamponade after fiberoptic bronchoscopy with transbronchial biopsy". *Journal of Investigative Medicine* (2015).
11. Haddad R., *et al.* "Pneumothorax and tension pneumopericardium following cardiothoracic surgery". *Jornal Brasileiro de Pneumologia* 32.1 (2006): 84-87.
12. Cummings RG., *et al.* "Pneumopericardium resulting in cardiac tamponade". *Annals of Thoracic Surgery* 37.6 (1984): 511-518.
13. Reid CL., *et al.* "Echocardiographic detection of pneumomediastinum and pneumopericardium: the air gap sign". *Journal of the American College of Cardiology* 1.3 (1983): 916-921.

14. Bennett JA and Haramati LB. "CT of bronchopericardial fistula: an unusual complication of multidrug-resistant tuberculosis in HIV infection". *American Journal of Roentgenology* 175.3 (2000): 819-820.
15. Al-Taweel A., *et al.* "Pneumopericardium Leading to Cardiac Tamponade in a Patient with Lung Cancer". *Thoracic and Cardiovascular Surgeon Reports* 5.1 (2016): 13-15.
16. Dabar G., *et al.* "[Bronchopericardial fistula treatment by a metallic stent]". *Revue des Maladies Respiratoires* 30.5 (2013): 429-432.
17. Sandeep Gupta Simica. "Endoscopic Closure of Bronchopleural Fistula using Glue Therapy: A Case Report". *Journal of Pulmonary and Respiratory Medicine* 1 (2011): 103.

Volume 7 Issue 4 April 2018

©All rights reserved by Abhijeet Shelke.