

Clinical Presentation and Diagnosis of Pulmonary Alveolar Microlithiasis

Ali Nawaz Khan^{1*}, Klaus Irion², Carolyn Allen Carolyn³ and Koteyar Shyam Sunder Radha Krishna⁴

¹Consultant Radiologist/Professor Honorary, North Manchester General Hospital, United Kingdom

²Consultant Cardiothoracic Radiologist, Manchester Royal Infirmary the United Kingdom and Honorary Professor, Manchester University, United Kingdom

³Consultant Thoracic Radiologist and Clinical Director, North Manchester General Hospital, United Kingdom

⁴Consultant Radiologist, North Manchester General Hospital, Manchester, United Kingdom

*Corresponding Author: Ali Nawaz Khan, Consultant Radiologist/Professor Honorary, North Manchester General Hospital, United Kingdom.

Received: January 08, 2018; Published: February 22, 2018

Abstract

Pulmonary alveolar microlithiasis (PAM) is a rare idiopathic disorder thought to be caused by a mutation in SLC34A2 resulting in the inactivation of a sodium-dependent phosphate cotransporter. The cotransporter usually clears phosphate from the degraded surfactant, which when inactivated cause an accumulation of phosphate in the alveoli, forming calcium phosphate microliths. Most cases are reported from Asia and Europe, with a slight female preponderance in the familial form. PAM is an autosomal recessive disorder and does not support the role of other, non-genetic, factors. PAM is often discovered incidentally on a Chest X-ray (CXR). There is usually a clinical-radiological dissociation; the imaging findings are often disproportionate to the clinical symptoms. The radiographic changes in children differ from that in adults. There is a rare association with testicular microlithiasis. A CXR shows diffuse, bilateral sand-like calcification, with middle to lower zone predilection. The pleural black line has been described in represents a strip of tangential peripheral lucency, underlying the ribs, which contrasts with a heavily calcified adjacent lung. HRCT better shows the extensive sand-like microliths, with additional features, including a crazy paving appearance, calcified interlobular septae, subpleural cysts, emphysematous changes, and ground glass opacification, which is more common in children. The radiographic appearance is considered as pathognomonic. The overall prognosis is good but occasionally slow progression can result in end-stage lung fibrosis requiring lung transplantation. The differential diagnosis includes dense granular opacities include; silicosis, healed varicella pneumonia idiopathic pulmonary hemosiderosis, pulmonary stannosis, pulmonary baritosis, and mitral stenosis.

Keywords: Phosphate Homeostasis; Pulmonary Alveolar Microlithiasis; SLC34A2; Type II b Sodium-Phosphate Cotransporter (NPT2B) HRCT; Type-II Sodium-Dependent Phosphate Cotransporter; Calcospherites; Microliths and Micronodular Opacities, Lung Transplantation; Outcome; Chest Ultrasound

Introduction

Pulmonary alveolar microlithiasis (PAM) is a rare idiopathic disorder thought to be caused by a mutation in SLC34A2; resulting in the inactivation of a sodium-dependent phosphate cotransporter; the latter is also found in alveolar type II cells. The cotransporter usually clears phosphate from the degraded surfactant, which when inactivated cause an accumulation of phosphate in the alveoli, forming calcium phosphate microliths (calcospherites) [1]. Most cases are reported from Asia and Europe. There is a slight female preponderance in the familial form [2]. A review by Castellana, *et al.* [1], confirms that PAM is an autosomal recessive disorder and does not support the role of other, non-genetic, factors. PAM is often discovered incidentally on a CXR. There is usually a clinical-radiological dissociation. The

imaging findings are often disproportionate to the clinical symptoms [3,4]. The radiographic changes in children differ from that in adults [2]. There is a rare association with testicular microlithiasis [4].

A CXR in PAM show diffuse, bilateral sand-like calcification distributed throughout the lungs, with middle to lower zone predilection [2,3]. The pleural black line has been described in PAM and is seen as a strip of tangential peripheral lucency, underlying the ribs, which contrasts with a heavily calcified adjacent lung [2].

HRCT better shows the extensive sand-like microliths throughout the lungs with subpleural and peribronchial distribution (typically ~1 mm) [5]. Additional accompanying HRCT features include a crazy paving appearance [5,6], calcified interlobular septae [6], subpleural cysts, emphysematous changes [6,7], the black line [2] and ground glass opacification, which more common in children [2]. Korn, *et al.* consider the radiographic appearance pathognomonic [8]. The overall prognosis is good but occasionally slow progression can result in end-stage lung fibrosis requiring lung transplantation. The differential diagnosis includes dense granular opacities include; silicosis, healed varicella pneumonia idiopathic pulmonary hemosiderosis, pulmonary stannosis, pulmonary baritosis, and mitral stenosis.

Clinical Presentation

Türktaş and associates report a case of a 10-year-old boy with PAM that presented with a chronic cough for more than 3-years. The authors proposed that as most children with PAM are asymptomatic, the likely cause of his chronic cough was a direct consequence of PAM [15].

Dahabreh and Najada describe a case of PAM in an 8-month-old male infant. The infant presented with worsening respiratory distress and cyanosis at the age of 2-months. A CXR and CT showed extensive pulmonary reticulonodular densities with a preference for the mid and lower zones. A tissue diagnosis of PAM was achieved by an open lung biopsy, which showed diffuse alveolar calcium deposits [16].

Khaladkar, *et al.* describe a clinico-radiological dissociation in PAM and add a case report. Clinically patients with PAM remain asymptomatic till the onset of hypoxemia and cor pulmonale. PAM remains stable; but some patients progress to pulmonary fibrosis, respiratory failure, and cor pulmonale. The authors report a case of a 44-year-old man that presented with exertion-related dyspnea, dry cough, for more since last six months. The CXR showed dense micronodules that gave a sandstorm appearance. The HRCT confirmed calcified micronodules associated with pleural calcification and subpleural cysts. Lung tissue sampling showed calcospherites within alveolar sacs [17].

PAM in pregnancy; Mittal and associates report a case report of a 30-year-old woman that presented with exertional dyspnea, lower limb edema, and mild dry cough of 4 to 5 months' duration. The symptoms occurred in the last month of her pregnancy, with gradually increasing dyspnea, lower limb edema and, and reduced urinary output. There were no features of, pulmonary TB, expectoration, hemoptysis or chest pain. Physical examination did not reveal figure clubbing or lymphadenopathy. Auscultation of the chest revealed a few end-inspiratory crepitations at the lung bases. Bronchial alveolar lavage showed calcium particles, whereas the transbronchial lung biopsy showed changes of PAM [18].

Radiology, CT, and Ultrasound

PAM is often asymptomatic despite significant changes in chest imaging. Diagnosis is usually made when patients become symptomatic in adult life. No definitive therapy is available, but earlier diagnosis may allow for evaluation of preventative strategies that could improve outcome. It is important to consider that children have marked radiographic findings with only mild symptoms or physical findings. Diagnosis can be made by imaging alone but may necessitate lung biopsy for definitive diagnosis [19]. Preventive measures advocated by Palombini BC, da Silva Porto N, Wallau CU, *et al.* include supplemental oxygen therapy in patients that are hypoxemic with rest, exercise or sleep and vaccination against pneumococcus and influenza.

Diagnostic Methods used and recommended

Absent technetium-99m MDP uptake of lungs in PAM

Turktas, *et al.* report a case PAM, who was treated for miliary tuberculosis eight years earlier and whose Tc-99m MDP scan revealed absent lung uptake. The diagnosis was achieved by bronchoalveolar lavage. A CXR and HRCT showed changes of PAM [20].

Chest ultrasound findings in PAM

HRCT is regarded as the gold standard for PAM imaging. Rea, *et al.* described the first case of trans-thoracic ultrasound instrumental in the diagnosis of PAM. The patient was young markedly obese with PAM at the age of 10 and referred for restaging at the age of 36. Unlike expected, no reverberation or additional artifacts were appreciated on trans-thoracic ultrasound (TU) examination despite the severity of the interstitial/alveolar involvement seen on conventional CT imaging. To date, no ring-down or comet-tail artifacts were detected.

The only transthoracic finding was an increased thickness and irregular profile, more evident in the dorsal and lower lung regions, of a hyper-echoic pleural line. The unusual finding in the case described was the discrepancy between TUS and CT findings [21].

Chest CT Signs of Pulmonary Disease

Raju, Ghosh, and Mehta in their pictorial review describe CT scanning of the thorax, particularly HRCT as the most critical development in the imaging of interstitial lung disease; although a CXR remains useful imaging, albeit with limited utility. The authors describe metaphoric chest CT scan feature that is linked to a variety of lung diseases. Some of the related elements are specific to a condition, while others help limit the differential diagnosis [22].

Planar and SPECT/CT bone scan versus 18F-FDG and 18F-sodium fluoride PET/CT scanning; A lung biopsy provides a definitive diagnosis of PAM; however, non-invasive imaging such as a CXR, HRCT, and radionuclides such as (99m) Tc-MDP bone scan can suggest the diagnosis in most of the patients. The authors used 18) F-sodium fluoride PET/CT in the in the characterization and the extent of PAM and found it superior to all other non-invasive imaging modalities. Thus, the authors recommend that (18) F-sodium fluoride PET/CT should be considered the imaging of choice in PAM [23].

Differential Diagnosis Pulmonary Calcification

The differential diagnosis of calcific nodules within the lungs is wide and include common causes such as tuberculosis and other rarer causes that include chronic fungal infections, healed chickenpox pneumonia and sarcoidosis besides PAM. In the pictorial assay the authors, categorize the nodules them based on the cause, including neoplastic calcifications, non-neoplastic calcified nodules, and iatrogenic- and exposure-related causes of pulmonary calcifications. The authors also illustrate the most characteristic imaging features and the clinical importance of each entity to provide a right approach to these calcifications [24].

Tissue Diagnosis of PAM; Diagnosis by sputum examination and transbronchial biopsy

Chatterji and associates report a case of PAM that presented with unusual imaging features that were diagnosed on sputum cytology and a transbronchial biopsy. Moreover, the patient also had azoospermia and primary infertility and increased lung volumes as determined by a helium dilution test [25].

Treatment of PAM; Lung Transplantation

Klikovits, *et al.* reviewed five consecutive patients with PAM, which underwent lung transplantation for severe disease. One patient required urgent re-transplantation on the second postoperative day and died of sepsis on the 11th postoperative day. One patient developed re-perfusion lung edema, requiring a prolonged recovery. Four patients remain alive with no further complications. In conclusion, lung transplantation is a feasible option for patients with end-stage PAM. No recurrence of PAM occurred in the surviving patients. The

study concluded that lung transplantation was a viable option in patients with end-stage PAM, with favourable post-operative results comparable to other indications for lung transplantation. [26].

Drug Therapy; Etidronate

Etidronate is a bisphosphonate that inhibits osteoclastic activity, crystal formation, and bone mineralization. Etidronate is FDA-approved drug to treat Paget's disease and heterotopic calcification [27]. Literature review reveals a few case reports of improvement in lung function and lung opacification with the use of etidronate in patients with PAM [28-32]. Other reports have shown etidronate to be ineffective in PAM [28,33]. As overall the study cohorts are small further studies are required to determine the role of etidronate in PAM [27].

Steroids

Steroid treatment in PAM has therapy been ineffective for PAM, though a few reports have shown subjective improvement in some patients [14,34].

Bronchoalveolar Lavage

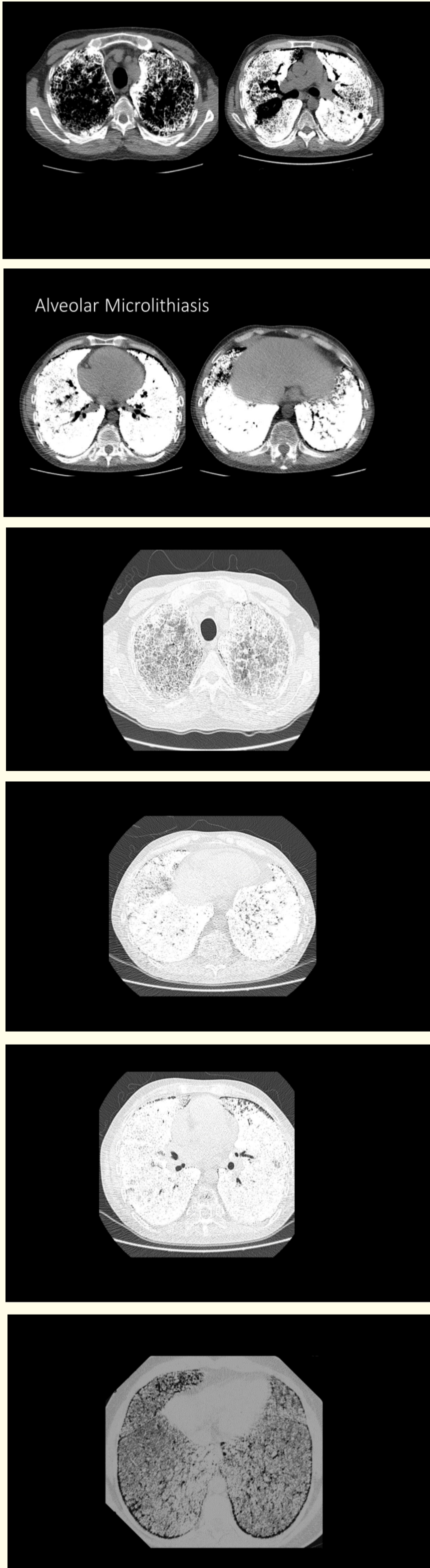
In PAM the microliths are localized in the alveolar sacs, and hence it is feasible that bronchoalveolar lavage may provide effective therapy. However, this mode of treatment has not been shown to be effective by Palombini BC, da Silva Porto N, Wallau CU, *et al* [35].

Oxygen Therapy and Vaccinations

Palombini BC, da Silva Porto N, Wallau CU, *et al.* advocated supplemental oxygen therapy in patients that were hypoxemic with rest, exercise or sleep. The authors also recommended that patients with PAM be vaccinated against pneumococcal and influenza [35].

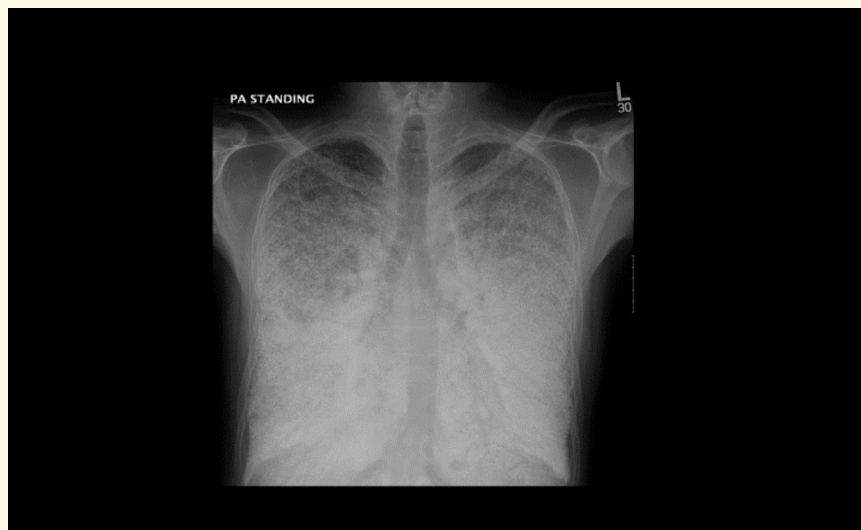

Figure 1: A PA CXR in PAM, shows sand-like calcification distributed throughout the lungs with bilateral distribution with middle to lower zone predilection subtle black pleural lines are seen.



Figures 2-7: Shows typical HRCT appearances of PAM, with a diffuse sand-storm pattern due to micro-calcification within the lungs. Note that the distribution is predominantly subpleural and peribronchial. A variety of other HRCT signs are seen including a crazy paving pattern, calcified interlobular septa small subpleural cysts emphysema black and ground-glass opacification.

Discussion

Castellana, *et al.* reviewing the clinical features, described PAM as a rare, autosomal recessive lung disease that is characterized by intra-alveolar formation and accumulation of tiny “microliths” [1]. The name “alveolar microlithiasis” was first used by Puhr in 1933 [2].

Emiralioglu, *et al.* described PAM as a genetic disorder caused by mutations in sodium-phosphate co-transporter encoding a type 2b sodium phosphate cotransporter. Turkey has a high prevalence of PAM. The authors describe three patients with presenting features of PAM, treated with disodium etidronate [9]. Castellana and Lamorgese published an early review of world literature of PAM up to the end of 2001. A total of 424 cases were reported; 269 were sporadic with male predominance. The study showed familial cases (155), more prevalent in females. The highest number of cases has been reported in Europe, followed by Asia, especially Asia Minor, while the single nations with the highest number of reported cases were Turkey, then Italy and the USA. The authors analyzed the family history, clinical presentation, and the presence of calcification in other organs. In the patients, reported in the 60s and 70s, the diagnosis was primarily made at autopsy [10].

Mariotta, *et al.* reviewed 576 cases with PAM published in the world literature till 2004 [ref]. Most of the patients came from Europe and Asia. The countries involved included Bulgaria, France, Germany, India, Italy, Japan, Poland, Spain, Russia, Turkey and the USA. Half the patients were symptomatic. The symptoms encountered were: chest pain, cough and dyspnoea. A family history of PAM was found in a third of the patients. A CXR and HRCT Chest x-rays showed enough characteristics to be diagnostic of PAM. Evidence of alveolar microliths was obtained in most cases by biopsy, autopsy, or bronchoalveolar lavage. PAM was misdiagnosed as pulmonary TB and sarcoidosis in 88 cases out of the 576. The course of PAM was protracted; the patients eventually died from cardio-respiratory failure. The study revealed that the etiology remains unknown and therapy is ineffective except for lung transplantation [11].

In a State-of-the-art review (2013); Ferreira Francisco, *et al.* describe the clinical-radiological dissociation as a hallmark of PAM, where typical features correlate well with specific pathological findings. The authors discuss the main pathological, clinical, and imaging aspects of PAM, ranging from its genetic basis to treatment. The hallmark of PAM described is the clinical-radiological dissociation, with typical imaging findings that correlate well with specific pathological findings. The long-term prognosis remains poor as no definitive therapy is available to date [12].

In a new publication Castellana, *et al.* reviewed 1022 patients with PAM reported worldwide in 544 papers up to December 2014. The study showed that PAM is found on all continents and in many nations, in particular in China, India, Italy, Japan, Turkey, and the United States of America. The clinical course is variable and non-genetic. The study explored the genetic, clinical, imaging and therapeutic options. The study showed that HRCT and broncho-alveolar lavage had the best diagnostic yield. However, a CXR may be sufficient for follow-up in families in which PAM has already been diagnosed. Presently lung transplantation is the only definitive therapy. However, improved exploration of the gene responsible for PAM offers hope for new therapeutic measures [13].

Ganesan, *et al.* report a case of PAM and provides a systemic analysis of cases reported from India. The authors present a 23-year-old woman that presented with a cough, wheeze, chest pain, and an episodic wheeze of five months duration. The pulmonary function tests were of an obstructive pattern, and the CXR showed fine micronodular opacities predominantly involving the middle and lower zones of both lungs. A transbronchial lung biopsy confirmed the diagnosis of PAM. The patient showed a good symptomatic response to inhaled steroids. A review of Indian literature identified 73 cases of PAM. The mean age of the patients was 28.8 (14.9) years, with no gender bias. Most of the patients were asymptomatic at presentation. The most common symptoms were shortness of breath and cough; the disease progressed to respiratory failure with cor pulmonale. India, a third of the patients, were initially misdiagnosed as TB and treated as pulmonary tuberculosis. Extra-pulmonary manifestations and other comorbidities contributed to the overall outcome as reported from other parts of the world. Emphases are needed to concentrate on the diagnosis and cost-effective therapy of PAM [14].

Conclusions

PAM is a genetic disorder, associated with the accumulation of calcium phosphate deposits in the lung alveoli. There is evidence of a genetic link with mutations in the type II sodium phosphate cotransporter and Npt2b. The affected patients have no symptoms early on in life, but, young patients are often found with diffuse calcific lung infiltrates on an incidental CXR, usually obtained for an unrelated purpose. Progression of PAM is insidious and slowly progress to incremental dyspnea on exertion and desaturation, ultimately, respiratory insufficiency by late middle age. Extrapulmonary disease is uncommon. Treatment remains supportive, including supplemental oxygen therapy. For patients with end-stage disease, lung transplantation is available as a last resort. Patients are so rare and geographically dispersed that trials are difficult. The recent development of laboratory animal model has revealed several promising treatment approaches for future trials.

Bibliography

1. Castellana G., *et al.* "Pulmonary alveolar microlithiasis: clinical features, evolution of the phenotype, and review of the literature". *American Journal of Medical Genetics* 111.2 (2002): 220-224.
2. Pühr L. "Mikrolithiasis alveolaris pulmonum". *Virchows Archiv A, Pathological Anatomy and Histology* 290.1 (1933): 156-160.
3. Helbich TH., *et al.* "Pulmonary alveolar microlithiasis in children: radiographic and high-resolution CT findings". *American Journal of Roentgenology* 168.1 (1997): 63-65.
4. Gasparetto EL., *et al.* "Pulmonary alveolar microlithiasis presenting with crazy-paving pattern on high resolution CT". *British Journal of Radiology* 77.923 (2004): 974-976.
5. Castellana G., *et al.* "Pulmonary alveolar microlithiasis: a review of the 1022 cases reported worldwide". *European Respiratory Review* 24.138 (2015): 607-620.
6. Webb WR and Higgins CB. "Thoracic Imaging". Lippincott Williams and Wilkins (2010).
7. Marchiori E., *et al.* "Diffuse high-attenuation pulmonary abnormalities: a pattern-oriented diagnostic approach on high-resolution CT". *American Journal of Roentgenology* 184.1 (2005): 273-282.
8. Korn MA., *et al.* "Pulmonary alveolar microlithiasis: findings on high-resolution CT". *American Journal of Roentgenology* 158.5 (1992): 981-982.
9. Emiralioğlu N., *et al.* "Diagnosis and treatment of pulmonary alveolar Microlithiasis". *Pediatrics International* 58.8 (2016): 805-807.
10. Castellana G and Lamorgese V. "Pulmonary alveolar Microlithiasis. World cases and review of the literature". *Respiration* 70.5 (2003): 549-555.
11. Mariotta S., *et al.* "Pulmonary alveolar Microlithiasis: report on 576 cases published in the literature". *Sarcoidosis, Vasculitis and Diffuse Lung Diseases* 21.3 (2004): 173-181.
12. Ferreira Francisco FA., *et al.* "Pulmonary alveolar Microlithiasis. State-of-the-art review". *Respiratory Medicine* 107.1 (2013): 1-9.
13. Castellana G., *et al.* "Pulmonary alveolar Microlithiasis: review of the 1022 cases reported worldwide". *European Respiratory Review* 24.138 (2015): 607-620.
14. Ganesan N., *et al.* "Pulmonary alveolar Microlithiasis: an interesting case report with systematic review of Indian literature". *Frontiers in Medicine* 9.2 (2015): 229-238.

15. Türktas I, *et al.* "Pulmonary alveolar Microlithiasis presenting with a chronic cough". *Postgraduate Medical Journal* 69.807 (1993): 70-71.
16. Dahabreh M and Najada A. "Pulmonary alveolar Microlithiasis in an 8-month-old infant". *Annals of Tropical Paediatrics* 29.1 (2009): 55-59.
17. Khaladkar SM., *et al.* "Pulmonary Alveolar Microlithiasis - Clinico-Radiological dissociation - A case report with Radiological review". *Journal of Radiology Case Reports* 10.1 (2016): 14-21.
18. Mittal BR., *et al.* "Radioisotope bone scanning in pulmonary alveolar Microlithiasis". *Clinical Nuclear Medicine* 25.6 (2000): 474-475.
19. Mehta K., *et al.* "Pulmonary Alveolar Microlithiasis". *Canadian Respiratory Journal* (2016): 4938632.
20. Turktas H., *et al.* "Pulmonary alveolar Microlithiasis with the absence of technetium-99m MDP uptake of lungs". *Clinical Nuclear Medicine* 13.12 (1988): 883-885.
21. Rea G., *et al.* "Chest ultrasound findings in pulmonary alveolar Microlithiasis". *Journal of Medical Ultrasound* (2001) 42.4 (2015): 591-594.
22. Raju S., *et al.* "Chest CT Signs of Pulmonary Disease: A Pictorial Review". *Chest* 151.6 (2017): 1356-1374.
23. Sahoo MK., *et al.* "Pulmonary alveolar Microlithiasis: imaging characteristics of planar and SPECT/CT bone scan versus 18F-FDG and 18F-sodium fluoride PET/CT scanning". *Japanese Journal of Radiology* 31.11 (2013): 766-769.
24. Amin SB., *et al.* "Pulmonary calcifications: a pictorial review and approach to formulating a differential diagnosis". *Current Problems in Diagnostic Radiology* 44.3 (2015): 267-276.
25. Chatterji R., *et al.* "Pulmonary alveolar microlithiasis: diagnosed by sputum examination and transbronchial biopsy". *Indian Journal of Chest Diseases and Allied Sciences* 39.4 (1997): 263-267.
26. Klikovits T., *et al.* "A rare indication for lung transplantation - pulmonary alveolar microlithiasis: institutional experience of five consecutive cases". *Clinical Transplantation* 30.4 (2016): 429-434.
27. Watts NB., *et al.* "Intermittent cyclical etidronate treatment of postmenopausal osteoporosis". *New England Journal of Medicine* 323.2 (1990): 73-79.
28. Mariotta S., *et al.* "Pulmonary microlithiasis. Report of two cases". *Respiration* 64.2 (1997): 165-169.
29. Kumazoe H., *et al.* "Reversed halo sign of high-resolution computed tomography in pulmonary sarcoidosis". *Journal of Thoracic Imaging* 24.1 (2009): 66-68.
30. Ozcelik U., *et al.* "Treatment and follow-up of pulmonary alveolar microlithiasis with disodium editronate: radiological demonstration". *Pediatric Radiology* 32.5 (2002): 380-383.
31. Ozcelik U., *et al.* "Long-term results of disodium etidronate treatment in pulmonary alveolar microlithiasis". *Pediatric Pulmonology* 45.5 (2010): 514-517.
32. Zompatori M., *et al.* "Bronchiolitis obliterans with organizing pneumonia (BOOP), presenting as a ring-shaped opacity at HRCT (the atoll sign). A case report". *La Radiologia Medica* 97.4 (1999): 308-310.
33. Jankovic S., *et al.* "Pulmonary alveolar microlithiasis in childhood: clinical and radiological follow-up". *Pediatric Pulmonology* 34.5 (2002): 384-387.

34. Flynn A and Agastyaraju AD. "Pulmonary alveolar microlithiasis". *International Journal of Case Reports and Images* 4.2 (2013): 108-110.
35. Palombini BC, *et al.* "Bronchopulmonary lavage in alveolar microlithiasis". *Chest* 80.2 (1981): 242-243.

Volume 7 Issue 3 March 2018

©All rights reserved by Ali Nawaz Khan., *et al.*