

Spinal Clearance in Unconscious Patients Admitted to an Intensive Care Unit (ITU), Following a Blunt Non Penetrating Trauma to Neck (Deliberate Self Hanging)

V Anumakonda^{1,2*}

¹Senior Honorary Clinical Lecturer, University of Birmingham, United Kingdom

²Critical Care Consultant, Russell's Hall Hospital, Dudley Group of Hospital NHS Foundation Trust, United Kingdom

*Corresponding Author: V Anumakonda, Senior Honorary Clinical Lecturer, University of Birmingham and Critical Care Consultant, Russell's Hall Hospital, Dudley Group of Hospital NHS Foundation Trust, United Kingdom.

Received: December 22, 2017; Published: February 16, 2018

Abstract

An unrecognised injury to the cervical spine could lead to catastrophic neurologic disability, henceforth clinicians are meticulous and err on side of caution; whilst clearing a cervical spine in an unconscious patient admitted to intensive care unit (ITU) for invasive ventilation, following a blunt non-penetrating trauma (BNPT).

Aim: A retrospective review of all the cases of unconscious blunt non-penetrating trauma (hanging) admitted from 2003. The study meant to highlight challenges faced by intensive care physicians whilst assessing these difficult cohort of patients.

Method: A retrospective analysis of all the admissions to the critical care unit admitted with blunt injury following hanging from 2003 till 2016.

Findings: Abnormalities including fractures were noted in four cases of thirteen patients pertinent to our clinical practice. Computer tomography (CT) neck was inconclusive in one as it was not possible to rule out ligamentous injury. In two cases clinically ruling out cervical spine injury was not possible. One of these CT neck reports was reported as abnormal initially. Interestingly, patient was cleared clinically. But this patients CT report was not amended or addendum was not added, despite a verbal report by a second radiology consultant.

Conclusion: Thin section (1 mm) CT head and neck of patients admitted to ITU by two different radiology consultants independently to mitigate risk of observation bias.

Magnetic resonance imaging could be considered only if there is uncertainty on helical reconstruction CT neck imaging in these high risk patients due to current limitations with manpower and resources.

Keywords: Intensive Care Unit; Trauma; CT Neck

Introduction

An unrecognised injury to the cervical spine could lead to catastrophic neurologic disability, henceforth clinicians are meticulous and err on side of caution; whilst clearing a cervical spine in an unconscious patient. Based on National Emergency X-Radiography Utilization Study (NEXUS) validated set of criteria [1-3], patients with blunt trauma have a low probability of injury to the cervical spine if they meet all five of the following criteria: they do not have tenderness at the posterior midline of the cervical spine, they have no focal neurologic deficit, they have a normal level of alertness, they have no evidence of intoxication, and they do not have a clinically apparent, painful injury that might distract them from the pain of a cervical spine injury. A simple decision instrument based on clinical criteria can help physicians to identify reliably these patients who need radiography of the cervical spine after blunt trauma [4].

However, other patients involved in significant blunt trauma must be assumed to have an unstable injury to their spine; the incidence is approximately 2% and increases up to 34% in the unconscious patient.

This is compounded by the fact that history, clinical examination finding available for the emergency crew is very limited. Moreover, most of these patients are under the influence of alcohol or sedatives as a part of their attempts to commit deliberate self-harm.

In addition, immobilisation with full spinal precautions for prolonged periods creates several difficulties in intensive care units. Spinal immobilisation is associated with pressure sores and pulmonary complications and is not recommended for more than 48 hours. In the neck, cervical ligamentous disruption without a major bony injury may lead to instability, which is an added concern for clinicians involved [5-12].

Aim

A retrospective review of all the cases of unconscious blunt non-penetrating trauma (hanging) admitted from 2003. The study meant to highlight challenges faced by intensive care physicians whilst assessing these difficult cohort of patients.

Method

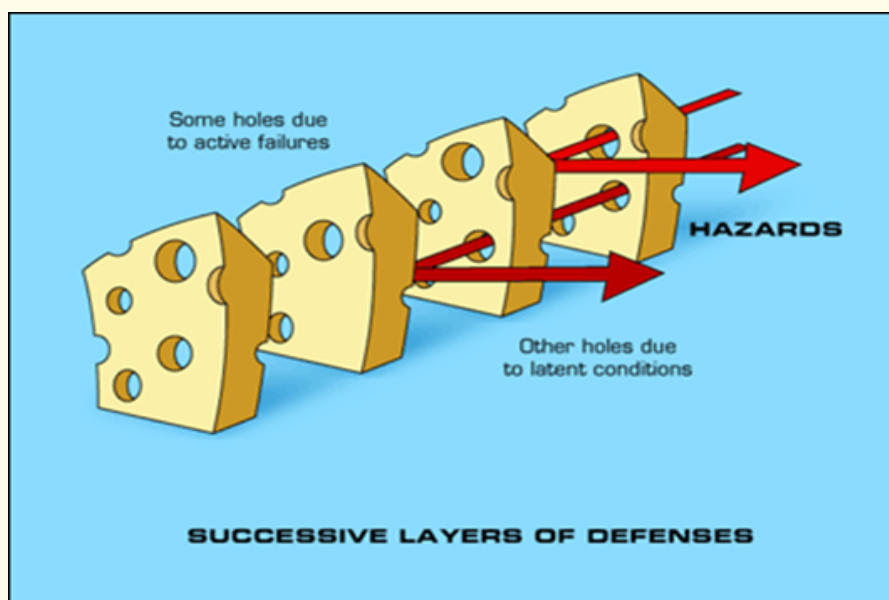
A retrospective analysis of all the admissions to the critical care unit admitted with blunt injury following hanging from 2003 till 2016 were included in the study. Data were collected from electronic patient records, patient case notes and picture archive and communication system. Data collected from ICIP (electronic patient’s records databases) using a structured query language (SQL) database queries. SQL, SPSS and Microsoft excel were used for analysis of the data.

Findings

A total of sixteen cases, all males admitted through resuscitation room of an accident and emergency department of the acute hospitals. The average age of the patients in this cohort was forty-two years 42 years. One of the patient of this cohort was transferred from different trust. CT neck was not done in two patients. Three patients amongst this cohort died on the unit.

Abnormalities including fractures were noted in four cases (30.7%) of 13 pertinent to our clinical practice. Two patients (15.35%) were noted to have significant fractures on their CT imaging. CT neck was inconclusive in one as it was not possible to rule out ligamentous injury. Two cases clinically ruling out cervical spine injury was not possible. One of these CT neck reports was reported as abnormal but ICIP documentation revealed a verbal report as being normal. ICU physician involved in clinical care, confirmed the verbal report with the radiologists. Patient was cleared clinically also by the ICU clinician. But this patient’s CT report was not amended or addendum was not added by the radiology department.

A further root cause analysis of the critical incident of radiology clinical report revealed a chain of flaws that lead to the event like a Swiss cheese model (Figure 1).



The Swiss cheese model of accident causation illustrates that, although many layers of defense lie between hazards and accidents, there are flaws in each layer that, if aligned, can allow the accident to occur.

During the last decade, radiology out of hours out-sourcing and telemedicine has increased across the several acute hospitals across UK and rest of the world. This change in practice has been mandated by human resources constrains.

This adds further complexity to a clinical governance process. Several risk mitigation simulation models were trailed to develop risk management strategies.

Current radiology practice involved most of the neuro-imaging were reported by radiologists individually. It was deemed an independent review by two different radiologists of neuro-imaging in this cohort, would minimise near misses whilst reporting the scans.

Subsequent, report dictation and rechecking of the CT report were verified by clinical administrative staff independently.

A multidisciplinary meeting involving radiologists, intensive care physicians and other allied professionals were used to address any governance issues and further risk mitigation issues apart from regular departmental quality peer review meetings.

Challenges of performing a MRI of an intubated patient

Unlike a quick run through a CT scanner, most of these patients have to have paralysed and sedation modified to tolerate a MRI. As most ventilators in MRI scanner are Boyle's machines, theatre staff are needed to ensure safety of anaesthetic machine. Main problems related to older anaesthesia machines can broadly be classified into delivery of lower inspired oxygen concentrations, delivery of dangerously high or low concentrations of volatile anaesthetic agents, insufficient ventilation, excessive airway pressures, foreign bodies, hyperventilation and miscellaneous. Modern machines have overcome many such drawbacks. However, addition of several mechanical, electronic and electric components has contributed to recurrence of some of the older problems such as leak or obstruction attributable to newer gadgets and development of newer problems. Human factors and unfamiliar operating surrounding in a MRI scanner also needed to be factored in to greater complications than machine faults.

Conclusion

Thin slice CT head and neck of BNPT patients admitted to ITU is the most effective practical solution in this challenging cohort. Subsequently, independent reporting by two different radiology consultants of these imaging to mitigate risk of observation bias.

MRI could be considered only if there is uncertainty on helical reconstruction CT neck imaging in these high risk patients due to current limitations with manpower and resources.

Bibliography

1. Hoffman JR, *et al.* "Selective cervical spine radiography in blunt trauma: methodology of the National Emergency X-Radiography Utilization Study (NEXUS)". *Annals of Emergency Medicine* 32.4 (1998): 461-469.
2. Lindsey RW, *et al.* "Efficacy of radiographic evaluation of the cervical spine in emergency situations". *Southern Medical Journal* 86.11 (1993): 1253-1255.
3. Roberge RJ and Wears RC. "Evaluation of neck discomfort, neck tenderness, and neurologic deficits as indicators for radiography in blunt trauma victims". *Journal of Emergency Medicine* 10.5 (1992): 539-544.
4. Dorsch JA and Dorsch SE. "Understanding Anesthesia Equipment. 5th edition". Philadelphia, USA: Lippincott Williams and Wilkins. Hazards of anesthesia machines and breathing systems (2007): 373-403.
5. Merchant R, *et al.* "Guidelines to the practice of anesthesia revised edition 2013". *Canadian Journal of Anesthesia* 60.1 (2013): 60-84.
6. Hartle A, *et al.* "Checking anaesthetic equipment 2012: Association of anaesthetists of great Britain and Ireland". *Anaesthesia* 67.6 (2012): 660-668.
7. Australian and New Zealand College of Anaesthetists. Recommendations on checking anaesthesia delivery systems 4.2.3.4.2. (2003).
8. Recommendations for Pre-Anesthesia Checkout Procedures. Sub-committee of ASA committee on equipment and facilities (2008).
9. Brockwell RC and Andrews JJ. "Complications of inhaled anesthesia delivery systems". *Anesthesiology Clinics of North America* 20.3 (2002): 539-554.
10. Harris TJ, *et al.* "Clearing the cervical spine in obtunded patients". *Spine (Phila Pa 1976)* 33.14 (2008): 1547-1553.
11. Martinez-Pérez R, *et al.* "MRI Prognostication Factors in the Setting of Cervical Spinal Cord Injury Secondary to Trauma". *World Neurosurgery* 101 (2017): 623-632.
12. Pourtaheri S, *et al.* "The role of magnetic resonance imaging in acute cervical spine fractures". *Spine Journal* 14.11 (2014): 2546-2553.

Volume 7 Issue 2 February 2018

©All rights reserved by V Anumakonda.