

## Methotrexate Induced Pneumonitis: A Case Report

Gayathri Devi HJ<sup>1\*</sup>, Neha R<sup>2</sup>, Richa D'cruz<sup>2</sup> and Viswam Subeesh<sup>3</sup>

<sup>1</sup>Professor and Head, Department of Respiratory Medicine, M S Ramaiah Medical College, Bangalore, India

<sup>2</sup>Pharm D Student, Department of Pharmacy Practice, Faculty of Pharmacy, M S Ramaiah University of Applied Sciences, Bangalore, India

<sup>3</sup>Assistant Professor, Department of Pharmacy Practice, Faculty of Pharmacy, M S Ramaiah University of Applied Sciences, Bangalore, India

\*Corresponding Author: Gayathri Devi HJ, Professor and Head, Department of Respiratory Medicine, M S Ramaiah Medical College, Bangalore, India.

Received: November 16, 2017; Published: January 05, 2018

### Abstract

Methotrexate is a widely used drug to manage neoplastic disorders, rheumatoid arthritis, psoriasis and psoriatic arthritis. It has been implicated in a variety of pulmonary complications. Low dose methotrexate has very few side effects which are clinically significant.

Methotrexate induced pulmonary toxicity is an infrequent and potentially serious adverse reaction. Although it is reversible, it may be fatal. Prompt withdrawal of methotrexate leads to clinical improvement. We report a case of methotrexate induced pneumonitis in a 52-year-old woman who was on methotrexate for psoriatic arthritis.

**Keywords:** Methotrexate; Pneumonitis; Arthritis

### Introduction

Methotrexate was first developed in 1940s as a specific antagonist of folic acid [1]. It is a folate analogue with anti-inflammatory, anti-proliferative and immunosuppressive activities. Initially methotrexate was used in malignant diseases and eventually it was used in the treatment of rheumatoid arthritis (RA), psoriasis and psoriatic arthritis (PsA) [2]. Methotrexate inhibits purine and pyrimidine synthesis by inhibiting di-hydro folate reductase which results in attenuated DNA. There are several proposed hypothesis for the anti-inflammatory effects of MTX with promotion of adenosine release with adenosine-mediated suppression of inflammation being the most accepted one which is supported by in-vivo, in-vitro and clinical data. Adenosine release which binds to specific adenosine receptor, is a key mediator of the antiinflammatory effect of methotrexate. The others include reduction of antigen-dependent T-cell proliferation, suppression of trans-methylation reactions [3].

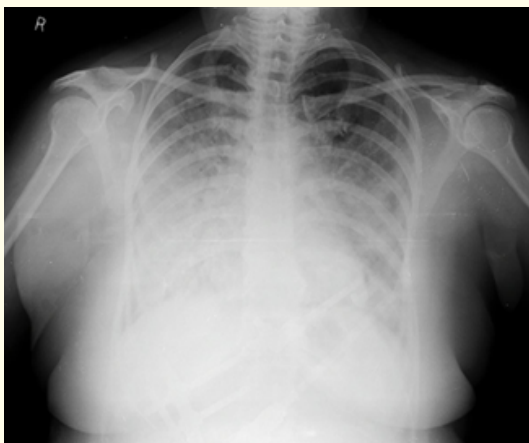
Many controlled trials and observational studies have revealed that low dose MTX have very few side effects which are clinically significant [4-6]. The most common adverse events associated with MTX are gastrointestinal, mucocutaneous, central nervous system effects followed with less frequency of hepatic and hematologic abnormalities [7]. Pulmonary toxicity, which is customarily an acute interstitial pneumonitis can also occur. Toxicity is not dose related [8,9]. The prevalence of Methotrexate induced Pneumonitis (MTX-P) is about 5% and incidence of 3.9 per 100 patients per year [8]. The typical clinical symptoms include progressive shortness of breath and cough, often associated with fever. In majority of the cases, stopping of the MTX therapy reverses the lung injury.

### Case Report

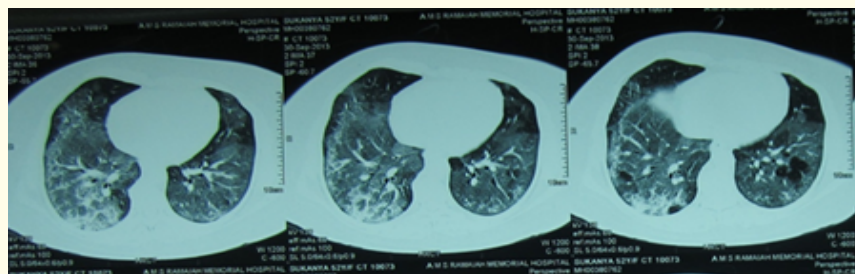
A 52 year old woman was admitted in the intensive care unit with chief complaints of dry cough and fever of 10 days duration and breathlessness of 8 days duration. She was a known case of hypertension and psoriatic arthritis. She was taking methotrexate 15 mg for psoriatic arthritis and upon consultation with a rheumatologist, the dose was increased to 20 mg which worsened her breathlessness.

On examination, patient was tachypneic and the vitals were: temperature-99.4F, pulse rate-177/min, respiratory rate- 44/min, blood pressure- 160/100 mmHg, spO2-83% at room air. She had mild pedal edema and diffuse swelling in both the hands. Chest auscultation revealed bronchial breath sounds in the right infrascapular area and bibasilar crepitation were noted, CVS/PA/CNS- normal. H1N1 and procalcitonin (PCT) were negative. Initial impression was Bilateral bronchopneumonia with Acute Respiratory Distress Syndrome (ARDS) with Interstitial Lung Disease(ILD) with psoriatic arthritis.

ABG analysis showed type 1 respiratory failure with  $paO_2/FiO_2$  - 114. Laboratory reports were total count - 14400 cells, neutrophils - 83%, lymphocytes - 12%, erythrocytes - 2%, monocytes - 3%, platelet count - 2.71 lakhs/cumm, serum electrolytes were normal, Pro BNP - 1040pg/ml, renal function test, liver function test, thyroid function test and urine routine was normal. USG abdomen was normal. Initial Chest X ray showed haziness in both the lower zones (Figure 1). High Resolution Computed Tomography (HRCT) showed patchy confluent ground-glass attenuation in both lungs with sub pleural interstitial septal thickening, no lymphadenopathy (Figure 2). 2D ECHO showed normal left ventricular systolic function, ejection fraction (EF) - 55%, Grade 3 left ventricular diastolic function.



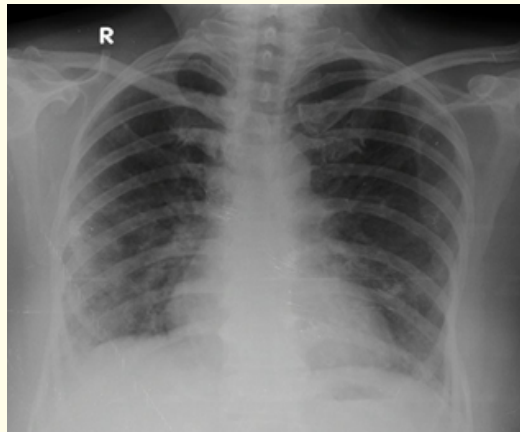
**Figure 1:** Chest x ray on admission (shows haziness in both the lower zones).



**Figure 2:** HRCT-Patchy confluent ground glass attenuation in both lungs. B/L Sub-pleural interstitial thickening, No lymphadenopathy.

Patient was treated with broad spectrum antibiotics, high dose of injection methylprednisolone and non-invasive mechanical ventilation (NIV) and MTX was discontinued with a diagnosis of methotrexate induced pneumonitis.

On the third day of admission patient showed improvement symptomatically and radiologically. Vitals were stable,  $spO_2$  - 94% at room air. Chest X ray after 2 weeks was normal (Figure 3). Patient was discharged after 16 days of admission on oral steroids and home oxygen therapy. Dramatic response to MTX cessation and steroid therapy was attributed to an adverse drug reaction rather than underlying disease process.



**Figure 3:** Chest x ray at the time of discharge.

Patient is on regular follow up. One-month post discharge pulmonary function test showed no obstructive or restrictive abnormality and Diffusing Capacity of the Lung for Carbon monoxide (DLCO) was slightly reduced. Methotrexate has been replaced with Tablet leflunomide 10mg OD for her psoriatic arthritis. Repeat Chest X-ray at the end of one year was normal.

### Discussion

Methotrexate was first introduced for the therapy of malignancies as an anti-proliferative agent that inhibits the synthesis of purines and pyrimidines [1]. The hypothesis is that the adenosine release which binds to specific adenosine receptor, is a key mediator of the anti-inflammatory effect of methotrexate [3]. In 1985, it was demonstrated that low dose intermittent methotrexate is a potent and effective therapy for rheumatoid arthritis [5].

Methotrexate-associated pulmonary toxicity was first reported in 1969 in patient with acute lymphoblastic leukemia [10]. MTX induced pulmonary toxicity is unforeseeable and infrequent adverse event. It is manifested in various forms such as acute interstitial pneumonitis, Interstitial fibrosis, bronchiolitis obliterans organizing pneumonia, pleural effusion, pulmonary nodules, non-cardiogenic pulmonary edema, Bronchitis/hyper reactivity of airways [11].

A metaanalysis of randomized controlled trials has shown that there is a small but significant increase in the risk of lung disease in patients treated with methotrexate for rheumatoid arthritis when compared with other disease modifying drugs and biologic agents [12].

MTX-P is speculated to be a hypersensitivity reaction, albeit the pathophysiology is not thoroughly understood. The alternate hypothesis includes direct drug toxicity to the lung tissue [13]. Typical bronchoalveolar lavage (BAL) and histological findings (eosinophilia, granulomas, and bronchiolitis) seen in these patients underpins the notion that MTX-induced pneumonitis delineates a hypersensitivity reaction. BAL fluid of patients with methotrexate pneumonitis shows an increase in the lymphocytes and disproportionate increase in the CD4+ cells and CD4/CD8 ratio which distinguishes it from ILD [14].

The potential risk factors for MTX-P includes increasing age, diabetes mellitus, pleuropulmonary disease, decreased albumin [15]. A study conducted by carson., et al. found significant association between MTX-P and raised creatinine, stomatitis, decreased albumin, raised LDH levels [8]. Following the commencement of the MTX therapy in psoriatic patients, pneumonitis has been documented after 4 months and up to 11 years [16]. It has been reported after 30 years of use as well [17] MTX-P presents subacutely over weeks with dry cough, progressive dyspnea, malaise, and fever. Patients are usually pyrexial, dyspneic at rest, and have bilateral fine crepitation in the lungs. HRCT will show characteristic ground-glass opacities with or without foci of consolidation [18] and chest radiograph will show diffuse interstitial infiltrates [19].

Though Searles G, McKendry RJ developed a criteria for diagnosing Methotrexate pneumonitis [20] (Table 1), it is considered to be a diagnosis of exclusion.

<ol style="list-style-type: none"> <li>1. Acute onset dyspnoea</li> <li>2. Fever &gt; 38°C</li> <li>3. Tachypnoea <math>\geq</math> 28/min, and dry cough</li> <li>4. Radiological evidence of pulmonary interstitial or alveolar infiltrates</li> <li>5. WBC &lt; 15,000/cu mm with or without eosinophilia</li> <li>6. Negative blood and sputum cultures (mandatory)</li> <li>7. Restrictive defect and decreased DLCO on PFT</li> <li>8. PO<sub>2</sub> &lt; 60 mm Hg on room air</li> <li>9. Histopathology consistent with bronchiolitis or interstitial pneumonitis with giant cells and without evidence of infection.</li> </ol>
<p>Definite: <math>\geq</math> 6 criteria; Probable: 5 of 9 criteria; Possible: 4 of 9 criteria</p>

**Table 1:** Criteria of Searles and McKendry for diagnosis of methotrexate pneumonitis.

The initial step in the treatment involves discontinuation of the methotrexate treatment. Most patients will show clinical improvement within a few days of cessation of the methotrexate, although radiographical abnormalities may take a few weeks to resolve. Supportive measures such as supplemental oxygen, assisted ventilation may be essential. Corticosteroids are used in patients who continue to have symptoms. Our patient responded promptly to withdrawal of methotrexate and steroid treatment. literature search showed similar case report which responded to methotrexate withdrawal and steroid treatment [21]. Reports show that steroids may accelerate symptom resolution [22]. The typical recommended dose is 1 mg/kg of prednisone or its equivalent with a slow taper based on clinical response. Cyclophosphamide has been used with good results in cases of methotrexate induced pneumonitis that is resistant to steroid therapy [23].

## Conclusion

We are reporting a case of pneumonitis following the use of methotrexate for the treatment of psoriatic arthritis in a 52 year old woman.

Methotrexate was discontinued and leflunomide was used. Patient recovered fully without any residual symptoms. It is vital to have sufficient evidence before implicating a lifesaving drug as a causative agent in adverse drug reaction. Prompt diagnosis helps in the favorable outcome as it is a reversible condition. Clinicians should have high index of suspicion for this condition.

Given the widespread use of Methotrexate, the present case report helps to define better the safety and risk-benefit profile of this drug.

## Bibliography

1. Chan ESL. "Cronstein BN. Molecular action of methotrexate in inflammatory diseases". *Arthritis Research* 4.4 (2002): 266-273.
2. Cronstein BN. "The mechanism of action of methotrexate". *Rheumatic disease clinics of North America* 23.4 (1997): 739-755.
3. Tian H and Cronstein BN. "Understanding the mechanisms of action of methotrexate". *Bulletin of the NYU Hospital for Joint Diseases* 65.3 (2007): 168-173.
4. Williams HJ., et al. "Comparison of low-dose oral pulse methotrexate and placebo in the treatment of rheumatoid arthritis. A Controlled Clinical Trial". *Arthritis and Rheumatology* 28.7 (1985): 721-730.
5. Weinblatt ME., et al. "Efficacy of low-dose methotrexate in rheumatoid arthritis". *New England Journal of Medicine* 312.13 (1985): 818-822.
6. Yazici Y. "Long-term safety of methotrexate in the treatment of rheumatoid arthritis". *Clinical and Experimental Rheumatology Supplements* 28.5 (2010): S65.
7. Verstappen S., et al. "Utrecht Rheumatoid Arthritis Cohort Study Group: Adverse events and factors associated with toxicity in patients with early rheumatoid arthritis treated with methotrexate tight control therapy: the CAMERA study". *Annals of the Rheumatic Diseases* 69.6 (2010): 1044-1048.
8. Carson CW., et al. "Pulmonary disease during the treatment of rheumatoid arthritis with low dose pulse methotrexate". *Seminars in Arthritis and Rheumatism* 16.3 (1987): 186-195.

9. Barrera P, et al. "Methotrexate-related pulmonary complications in rheumatoid arthritis". *Annals of the rheumatic diseases* 53.7 (1994): 434-439.
10. Clarysse AM, et al. "Pulmonary disease complicating intermittent therapy with methotrexate". *JAMA* 209.12 (1969): 1861-1864.
11. Rondon F, et al. "Methotrexate-induced pulmonary toxicity in psoriatic arthritis (PsA): case presentation and literature review". *Clinical Rheumatology* 30.10 (2011): 1379-1384.
12. Conway R, et al. "Methotrexate and lung disease in rheumatoid arthritis: a meta-analysis of randomized controlled trials". *Arthritis and Rheumatology* 66.4 (2014): 803-812.
13. Nagaraj S, et al. "Methotrexate induced pneumonitis". *Indian Journal of Rheumatology* 7.2 (2012): 83-88.
14. Schnabel A, et al. "Bronchoalveolar lavage cell profile in methotrexate induced pneumonitis". *Thorax* 52.4 (1997): 377.
15. Alarcon GS, et al. "Risk factors for methotrexate-induced lung injury in patients with rheumatoid arthritis: a multicenter, case-control study". *Annals of Internal Medicine* 127.5 (1997): 356-364.
16. McKenna K and Burrows D. "Pulmonary toxicity in a patient with psoriasis receiving methotrexate therapy". *Clinical and Experimental Dermatology* 25.1 (2000): 24-27.
17. Salehi M, et al. "Methotrexate-induced Hypersensitivity Pneumonitis appearing after 30 years of use: a case report". *Journal of Medical Case Reports* 11 (2017): 174.
18. Dawson JK, et al. "Pulmonary effects of low-dose methotrexate therapy". *Clinical Pulmonary Medicine* 11.5 (2004): 307-317.
19. Lateef O, et al. "Methotrexate pulmonary toxicity". *Expert Opinion on Drug Safety* 4.4 (2005): 723-730.
20. Searles G and McKendry R. "Methotrexate pneumonitis in rheumatoid arthritis: potential risk factors. Four case reports and a review of the literature". *The Journal of Rheumatology* 14.6 (1987): 1164-1171.
21. Samad A, et al. "Methotrexate-induced pneumonitis in a patient with rheumatoid arthritis: a case report". *Journal of Pharmacy Practice and Research* 46.3 (2016): 256-260.
22. Cooper Jr JAD, et al. "Drug-induced pulmonary disease: Part 1: Cytotoxic drugs". *American Review of Respiratory Disease* 133.2 (1986): 321-340.
23. Suwa A, et al. "Rheumatoid arthritis associated with methotrexate-induced pneumonitis: improvement with i.v. cyclophosphamide therapy". *Clinical and Experimental Rheumatology* 17.3 (1999): 355-358.

**Volume 7 Issue 1 January 2018**

**©All rights reserved by Gayathri Devi HJ, et al.**