

Third Stage *Oestrus ovis* Larvae Infestation of Human Maxillary Sinuses, a First in Lebanon

Elias Rizk¹, Michel Kmeid^{1*}, Elie Azar², Jules-Joel Bakhos³, Rosette Daaboul⁴ and Nabil Moukarzel²

¹Lebanese University, School of Medicine, Beirut, Lebanon

²Department of Otolaryngology, Head and Neck Surgery, Lebanese University, Beirut, Lebanon

³Saint Joseph University, School of Medicine, Beirut, Lebanon

⁴Lebanese University, Levant Clinic Hospital, Beirut, Lebanon

*Corresponding Author: Michel Kmeid, Lebanese University, School of Medicine, Beirut, Lebanon.

Received: September 14, 2017; Published: September 28, 2017

Abstract

Background: *Oestrus ovis* is a parasite of bovid nasal and paranasal cavities. Humans are rarely infected, and larvae have rarely been found in the human maxillary sinuses where their development beyond the first stage is even more uncommon.

Cases Report: We report 3 cases of *Oestrus ovis* infestation, the first to be described in Lebanon. Two of these patients developed third stage larvae in the sinonasal tract, an unprecedented event in immunocompetent hosts. A third patient, a 12 year-old girl developed ocular myiasis with first stage larvae isolated from the conjunctivae bilaterally. She also had evidence of bilateral ethmoid and maxillary sinuses blunting on sinonasal imaging. Functional endoscopic sinus surgery was performed in all 3 patients but recovered live third stage larvae in only one of them. This patient received oral ivermectin post-operatively with total remission.

Conclusion: Sinonasal oestrosis is very unusual in humans. Development into third stage larvae may have been related to immunosuppression caused by intranasal and systemic steroids. Functional endoscopic sinus surgery is both diagnostic and curative and should include all possibly involved sinuses. Ivermectin, an anti-parasitic agent can be used as adjunctive therapy, though, further studies are required to support its efficacy when treating affected patients.

Keywords: *Sinonasal Myiasis; Oestrus ovis; Oestrosis; Head and Neck*

Introduction

Myiasis is the infestation of live vertebrates with dipterous larvae. In humans, cutaneous and wound infections are most commonly encountered [1,2]. Several types of flies can produce myiasis in the head and neck region. *Oestrus ovis* (*O. ovis*), a diptera fly and obligate parasite of the nasal cavities and sinuses, is one of them [1,3].

Oestrosis is the myiasis caused by *O. ovis* larvae. It usually infects sheep and goats in the Mediterranean Basin and develops in three larval stages as a parasite of the sinonasal cavity. The female flies deposit one to several dozen larvae, few centimeters after its entry in the host nostrils. The larvae then adhere to the nasal mucosa and migrate to the sinonasal cavity where they will molt and grow up to 20 mm in length [4]. When fully developed, they move down the nasal passage and drop to the ground where they pupate.

It is unusual in humans, rarely develops beyond the first stage and is uncommon to the maxillary sinuses [5,6]. We report three cases of healthy immunocompetent patients infested by *Oestrus ovis* larvae and we discuss their management.

Case 1

A healthy, 49-year-old Lebanese teacher living in Beirut suburbs, presented with a history of rhinitis, associated with numerous episodes of severe cough and dyspnea. He also reported left eye redness with itching and tearing prior to the onset of respiratory symptoms. His condition, ongoing for three months, was treated with antibiotics, antihistamines, steroids (prednisone) and nebulizers, yet without any remission. Consequently, he was hospitalized.

At admission, laboratory tests showed the presence of a high eosinophil count and elevated total IgE levels. Hours later, he expectorated a dead larva. It was identified as a third stage *O. ovis*. On the following day, he expelled one living larva from his nose and coughed out two other living ones. A sinus computed tomography scan was performed and showed a bilateral thickening of the maxillary and ethmoidal sinus mucosa while the frontal sinuses appeared to be normal (Figure 1 A, B and C). The nasal cavities appeared normal on nasal endoscopy, with no discharge or polyps. Bilateral endoscopic maxillotomies were then performed and six living stage three larvae were removed from the maxillary sinuses: four from the left and two from the right (Figure 2).

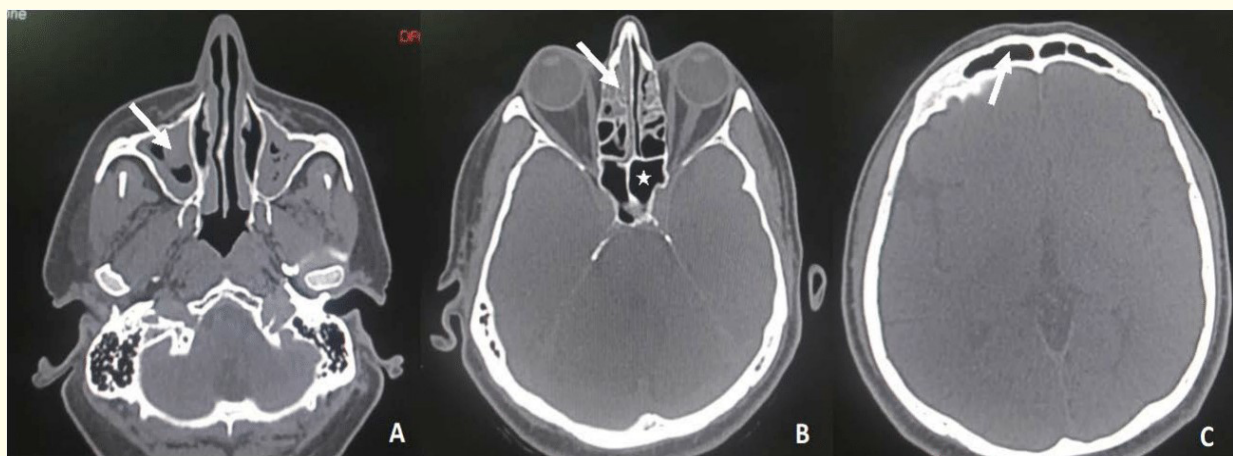


Figure 1: Axial cut CT-scans evaluating the facial sinuses. (A) Level of maxillary sinuses, showing bilateral maxillary mucosal thickening (arrow). (B) Level of ethmoidal and sphenoidal sinuses, showing bilateral mucosal thickening in both anterior ethmoidal air cells (arrow); the sphenoid sinuses are patent (star). (C) Level of frontal sinuses, normal appearance (arrow).

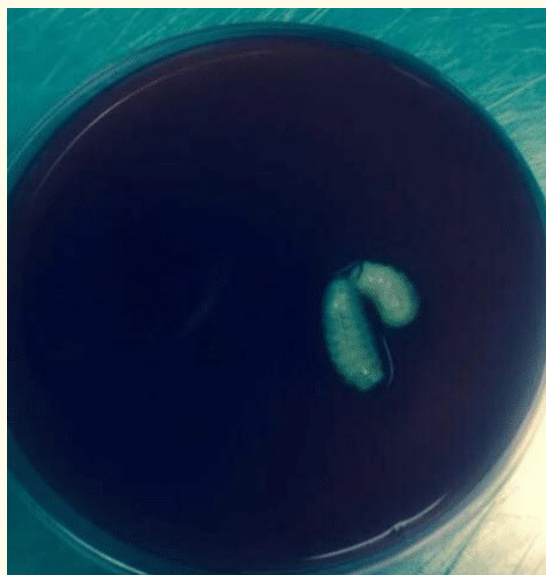

Figure 2: Stage three *O. ovis* larvae removed from the maxillary sinuses during endoscopic sinus surgery.

Postoperatively, the patient received one tablet of 3 mg Ivermectin. Two weeks later, another nasal endoscopy showed the maxillary sinus ostia to be patent. He then underwent bilateral anterior and posterior ethmoidectomy with bilateral sphenoidotomy, and no larvae were identified. Both maxillary sinuses were then washed with boric acid and the patient received four additional tablets of 3 mg Ivermectin. The respiratory problems and rhinitis resolved completely, and the patient was discharged.

Case 2

A 12 year-old girl with no previous medical history presented for headaches, nasal congestion and bilateral periorbital swelling. Earlier on, she reported that a small fly got into her left eye. The next day, she complained of left periorbital swelling, redness and itching. It later involved the right eye. She was then seen by an ophthalmologist. Microscopic examination of the conjunctival sacs revealed the presence of small stage I larvae in both eyes. The larvae were removed with thorough lavage and the patient was prescribed antibiotic eye drops. Three days later, she started complaining of nasal congestion and frontal headaches. Nasal fibroscopic exam was unremarkable. Spread into the sinonasal tract through the nasolacrimal ducts was suspected. Sinus imaging was therefore performed and showed mucosal thickening at the level of the ethmoid sinuses bilaterally. Functional endoscopic sinus surgery was then performed to confirm the diagnosis but failed to recover any gross larvae from the sinonasal tract despite the presence of extensive polypoid inflammatory mucosa. The patient was prescribed nasal saline lavage, postoperatively. Two weeks later, there was a significant improvement in symptoms and chemosis resolved completely.

Case 3

A 28 year-old woman, previously healthy, presented to our department after expelling 3 dead larvae from her nose. She complained of nasal congestion, facial pressure and cough for the past 2 months. Computed tomography of the sinuses showed the presence of mucosal thickening in the ethmoid and maxillary sinuses bilaterally and she was therefore treated for her sinusitis with antibiotics, intranasal steroid and saline lavage. Symptoms improved but she became alarmed when she expelled the dead larvae and sought medical attention. Functional endoscopic sinus surgery was performed but also failed to recover any gross larvae. Nevertheless, the patient's symptoms improved, post-operatively.

Discussion

Oestrosis is very unusual in humans. Most cases go unnoticed as the larvae rarely develop beyond the first stage. Only a few cases in humans have been reported in the literature.

Affected people with oestrosis are mainly located in areas where sheep and goats are raised, however, most patients with nasal myiasis, deny a contact with these animals [6]. Similarly, our patients lived in urban areas and could not recall contact with sheep or goats or any history of visit or travel to endemic areas. Two of them also denied any direct attack by flies.

In humans, ophthalmomyiasis related to *O. ovis* is more common than sinonasal infections and it usually manifest as an acute conjunctivitis with itchy tearing red eyes and chemosis [1,4,7,8]. The sinonasal tract, oral cavity and oropharynx can be involved but the larvae usually survive there for a few days without any further development and therefore, the patient remains asymptomatic and the infection goes unnoticed [8]. One way to explain the third stage larval development in the sinonasal tract in two of our patients could be the relative immunosuppression caused by the steroids (intranasal or systemic) that they received as treatment for their previous "rhinitis/sinusitis".

Sinonasal myiasis is difficult to diagnose as patients usually develop non-specific long-lasting symptoms of rhinitis and sinusitis (sneezing, nasal discharge, nasal congestion, pruritus) [8]. Elevated eosinophil count and IgE levels can provide additional clues to the diagnosis. In fact, animal studies on parasite infected sheep showed a marked increase in mast cells and eosinophils in the sinonasal mucous membranes, submucosa and interglandular chorion including the nasal septum and turbinates [9]. This finding supports the hypothesis of an underlying type I hypersensitivity reaction in the pathogenesis of this disorder. Clearly, the diagnosis is established when the patient

starts to expel and expectorate dead white to brown larvae. In all cases, when the disease is suspected and sinonasal involvement is evident clinically or radiologically, endoscopic surgical sinus exploration is advised as it is both diagnostic and therapeutic.

The mainstay of treatment is the mechanical removal of all visible larvae. Steroids can alleviate hypersensitivity-related symptoms but are better to be avoided as they may favor further larval development. The use of ivermectin is well established when treating infected animals. An animal-based field trial showed 100% curative results with Ivermectin when administered orally at a dosage rate of 0.2 mg/kg against naturally acquired sheep oestrosis [10]. However, further studies on the efficacy of this drug in humans are required. In our case series, patient 1 received a total dose of 15 mg ivermectin and was cured. On the other hand, favorable outcomes were noted for the other 2 patients even though they were not prescribed ivermectin as no larvae were recovered, intraoperatively.

Conclusion

Despite its rarity, patients with sudden onset of rhinitis symptoms without identifiable causes must be examined to exclude nasal myiasis, especially if areas with sheep and goat husbandry were visited. We report the first cases in Lebanon of a third stage *O. ovis* larval human sinonasal infestation in immunocompetent and healthy patients that was treated with full remission.

Financial Disclosure and Conflict of Interest

The authors whose names are listed above certify that they have NO affiliations with or involvement in any organization or entity with any financial or non-financial interest in the subject matter or materials discussed in this manuscript.

Ethical Considerations

All data collected are subjected to prior ethical approval ensuring the safety, rights and anonymity of all participants in this review. All procedures were followed in accordance with the responsible committee on human experimentation and with the Helsinki Declaration of 1975 and subsequent revisions.

Bibliography

1. Francesconia F and Lupi O. "Myiasis". *Clinical Microbiology Review* 25.1 (2012): 79-105.
2. Singh A and Singh Z. "Incidence of myiasis among humans-a review". *Parasitology Research* 114.9 (2015): 3183-3199.
3. Duque CS, et al. "Otolaryngic manifestations of myiasis". *Ear Nose Throat Journal* 69.9 (1990): 619-622.
4. Macdonald PJ, et al. "Ophthalmomyiasis and nasal myiasis in New Zealand: a case series". *New Zealand Medical Journal* 112.1100 (1999): 445-447.
5. Tligui H, et al. "Human rhinomyiasis due to *Oestrus ovis*: case report in Morocco". *Medecine Tropicale* 71.1 (2011): 83-84.
6. Einer H and Ellegard E. "Nasal myiasis by *Oestrus ovis* second stage larva in an immunocompetent man: case report and literature review". *Journal of Laryngology and Otology* 125.7 (2011): 745-746.
7. Özyol P, et al. "External ophthalmomyiasis: a case series and review of ophthalmomyiasis in Turkey". *International Ophthalmology* 36.6 (2016): 887-891.
8. Hoyer P, et al. "Human Nasal Myiasis Caused by *Oestrus ovis* in the Highlands of Cusco, Peru: Report of a Case and Review of the Literature". *Case Reports in Infectious Diseases* (2016).
9. Nguyen VK, et al. "Mast cells and eosinophils of the respiratory mucosa of sheep with *Oestrus ovis* (Linne, 1761) infection". *Parasite* 3.3 (1996): 217-221.

10. Lucientes J, *et al.* "Efficacy of orally administered ivermectin against larval stages of *Oestrus ovis* in sheep". *Veterinary Parasitology* 75.2-3 (1998): 255-259.

Volume 5 Issue 1 September 2017

©All rights reserved by Michel Kmeid., *et al.*