

Chronic Thromboembolic Pulmonary Hypertension with Atypical Image

Serkan Ünlü¹, Gülten Taçoý^{1*}, Sedat Türkođlu¹, Kıvılcım Ođuzölgen² and Atiye Çengel¹

¹Faculty of Medicine, Cardiology Department, Gazi University, Ankara, Turkey

²Faculty of Medicine, Department of Pulmonary Medicine, Gazi University, Ankara, Turkey

***Corresponding Author:** Gulden Taçoý, Professor, Faculty of Medicine, Cardiology Department, Gazi University, Ankara, Turkey.

Received: March 31, 2017; **Published:** September 14, 2017

Abstract

Chronic thromboembolic pulmonary hypertension (CTEPH) is a rare condition and occurs after less than %2 of all acute pulmonary embolic courses. Coronary artery–pulmonary artery collaterals (CAPAC) are newly described and still have been investigating condition seen in chronic thromboembolic pulmonary hypertension (CTEPH) patients [1-5]. We want to describe a female patient with coronary artery- pulmonary artery collaterals due to CTEPH.

Keywords: Chronic Thromboembolic Pulmonary Hypertension; CAPAC

Case Report

A 74 year old female was admitted for worsening dyspnea, chest discomfort and hemoptysis which started 3 days earlier. She had no history of lung or cardiac diseases. She has been a nonsmoker and never had any symptoms before. She was received total knee replacement 5 years ago and during pre-operational assessment no pathological conditions were found. She had no exposure to any toxic or harmful substance in her life. Physical examination revealed a non-febrile tachypneic (24 breaths/min) patient, with a pulse of 115 beat/min, BP of 125/72 mm Hg. 3 L/min of oxygen was needed to maintain oxygen saturation above % 92 (measured by pulse oxymetry). Cardiopulmonary examination noted jugular venous distension and a pansystolic murmur at left sternal border. She had rales bilaterally at the basal parts of lungs. The rest of the physical examination was unremarkable. A complete blood count, basic metabolic panel were studied. All was normal except BNP level. (470 pg/ml) Chest X-ray demonstrated enlarged pulmonary conus and increased cardiothoracic ratio.

Electrocardiography showed no abnormalities except sinus tachycardia. Transthoracic echocardiography revealed normal systolic LV function and enlarged pulmonary artery, a dilated inferior vena cava and enlarged right heart chambers with reduced systolic function accompanied by moderate to severe tricuspid regurgitation. Systolic pulmonary artery pressure from the peak velocity of tricuspid regurgitation jet was measured as 105 mmHg. A contrast enhanced computed tomographic pulmonary angiogram detected filling defects in the proximal and mid segments of the multiple arteries. Radionuclide ventilation/perfusion scan showed perfusion defects. Right heart catheterization confirmed pulmonary hypertension with 65 mmHg of mean pulmonary artery pressure and 12 mmHg of pulmonary capillary wedge pressure. Systolic and diastolic PAP were 107 mmHg and 34 mmHg respectively. The pulmonary to systemic blood flow ratio (QP/QS) was calculated and found to be 1.0. O₂ saturation was 47.7% in pulmonary artery, and 73.4% in aorta. Her O₂ saturation with pulse oximetry was % 80. Selective coronary angiography revealed the presence of a connection from the right coronary artery to the right pulmonary artery and non significant lesions in the left coronary system (Video I-VI, Figure 1 and 2).

Video I

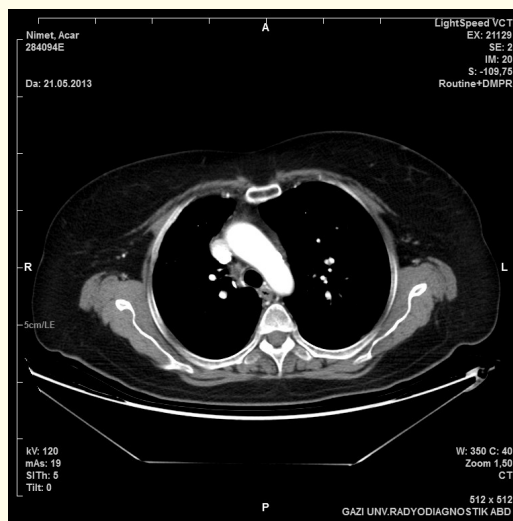
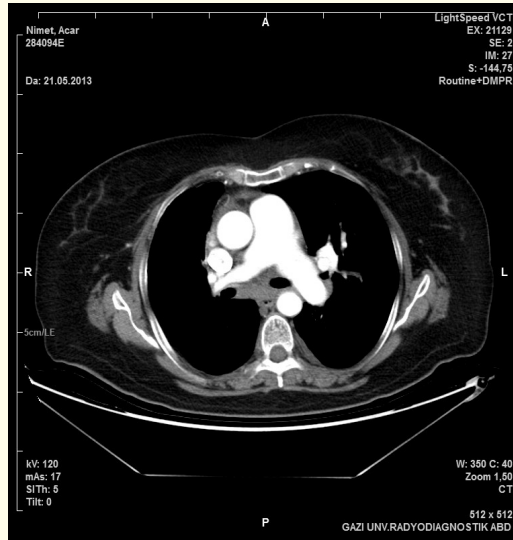
Video II

Video III

Video IV

Video V

Video VI



Discussion

Chronic thromboembolic pulmonary hypertension (CTEPH) rarely occurs after acute pulmonary embolism cases. CTEPH is one of the important reason of pulmonary hypertension. The pulmonary endarterectomy (PEA) is still the only probable cure option for the patients with CTEPH. Advanced specific PH treatment with anticoagulation seems to help clinical improvement of the patients with CTEPH, yet further studies have to be performed to confirm and validate the effectiveness of the medical treatment [4,5].

Coronary artery–pulmonary artery collaterals (CAPAC) are newly described and still have been investigating condition seen in CTEPH patients. Up to date there is no evidence that CAPACs could have a prognostic role for the CTEPH patients moreover, the characteristics of

patients with CAPAC are not readily described yet. It is suggested that patients with more severe occlusions of pulmonary arteries could have an increased incidence of having CAPACs. In the knowledge of this era, CAPACs are believed to play a role in diagnosis and prognosis of CTEPH patients just like bronchial collaterals in CTEPH patients [1-5].

CTEPH can be diagnosed by ventilation perfusion scintigraphy and also by computed tomographic angiography of pulmonary arteries. Anomalies of pulmonary artery could also have very similar radiologic view like CTEPH. Enlarged, tortuous pulmonary arteries on the unaffected side/part could be observed with oedema due to increased perfusion. Agenesis or hypogenesis of pulmonary arteries usually cause symptoms during adolescence, but patients in adulthood who remained asymptomatic were also reported. The progression of the disease plays an important role for differential diagnosis. CTEPH can extend to unaffected arteries and can result in different patterns of filling defects where a congenital anomaly would stay same.

Coronary angiography is commonly performed for differential diagnosis in CTEPH patients. CAPACs can be easily misdiagnosed as coronary artery fistulas (CAF) in angiographic views. CAFs are rare congenital anomalies which are the most frequent acquired or congenital coronary artery anomalies leading bypassing myocardial capillary network [1-3,6-8]. They can originate from the three major coronary arteries and mostly drain into the right heart chambers. They affect approximately 0.002% of the general population, accounting for 0.13% of all cardiac congenital abnormalities. They are mostly diagnosed incidentally during coronary angiography and can be seen in 0,05% to 0,025% of all procedures [1]. Although they remain asymptomatic in the majority of the patients, in the elder ages, they can cause a difficult clinical problems depending on the site and origin of the fistula, shunt volume and existing co-morbidities. Any cardiac clinical scenario might be seen like myocardial ischemia, heart failure, or sudden death in patients with coronary artery fistula. Surgical or transcatheter closure of coronary artery fistulae are treatment approaches to prevent hemodynamic impairment. Since coronary fistulas can cause pulmonary hypertension secondary to left to right shunt volume, closure of these fistulas with surgery or percutaneous approach is indicated, however CAPACs perfuses the region of occluded pulmonary arteries [4,7,9,10]. Coronary angiography also should be considered for all patients who are evaluated as a PEA candidate, to diagnose CAPACs, since patients with CAPACs have a better prognosis after PEA.

A repeated ventilation perfusion scan showed newly affected non perfused fields in the lungs which directed our diagnosis directly to CTEPH. Due to extent of the disease, older age and reduced functional capacity, pulmonary endarterectomy could not be performed.

Since the patient stated, she could not manage to use warfarin, enoxaparine was prescribed. The patient was also started specific pulmonary hypertension treatment with iloprost, tadalafil and ambrisentan.. After 10 months of treatment, her O₂ saturation was 90% with pulse oximetry and pro-BNP level was 60 pg/ml. In our country treatment with riociguat is only possible with approval of the health ministry. We are waiting now for the response of the health ministry.

Conclusions

We report a CTEPH case in which a CAPAC originating from the right coronary artery and draining into the right pulmonary artery. These formation of collateral could be seen in 10% of CTEPH patients who had gone to coronary angiographic evaluation. Misdiagnosis could lead to unnecessary interventional approaches an even surgery to close collaterals which would create unfavourable consequences.

Declaration of Conflicting Interests

No conflict of interest.

Bibliography

1. Vavuranakis M., *et al.* "Coronary artery fistula in adults: incidence, angiographic characteristics, natural history". *Catheterization and Cardiovascular Interventions* 35.2 (1995): 116-120.

2. Gillibert C., *et al.* "Coronary artery fistulas in an adult population". *European Heart Journal* 7.5 (1986): 437-443.
3. Gowda RM., *et al.* "Coronary artery fistulas: clinical and therapeutic considerations". *International Journal of Cardiology* 107.1 (2006): 7-10.
4. Nick H Kim., *et al.* "Chronic Thromboembolic Pulmonary Hypertension". *Journal of the American College of Cardiology* 62.25 (2013): D92-D99.
5. Galie N., *et al.* "Guidelines for the diagnosis and treatment of pulmonary hypertension". *European Heart Journal* 30.20 (2009): 2493-2537.
6. Krause W. "Über den Ursprung einer akzessorischen coronaria aus der pulmonalis". *Z Rati Med* 24 (1865): 225-227.
7. EH Fell., *et al.* "Surgery for congenital coronary artery arteriovenous fistulae". *AMA Archives of Surgery* 77.3 (1958): 331-335.
8. Mavroudis C., *et al.* "Coronary artery fistulas in infants and children: a surgical review and discussion of coil embolization". *Annals of Thoracic Surgery* 63.5 (1997): 1235-1242.
9. Goto Y., *et al.* "Surgical treatment of the coronary artery to pulmonary artery fistulas in adults". *Cardiology* 89 (1998): 252-256.
10. Akdeniz B., *et al.* "Multiple coronary artery-pulmonary artery fistulas in patients with chronic thromboembolic pulmonary hypertension". *Anadolu Kardiyoloji Dergisi* 12.2 (2012): E6-E7.

Volume 4 Issue 6 September 2017

©All rights reserved by Gülten Taçoy., *et al.*