

## **Medical Thoracoscopy: A Wonderful Tool in the Hands of Respiratory Physician: An Indian Experience**

**Vikas Maurya\*, Puneet Khanna, Sunny Kalra and Sandeep Nayar**

*Department of Respiratory Medicine, Allergy and Sleep Disorders, BLK Super Speciality Hospital, New Delhi, India*

**\*Corresponding Author:** Vikas Maurya, Consultant Specialist and Interventional Pulmonologist, Department of Respiratory Medicine, BLK Super Speciality Hospital, New Delhi, India.

**Received:** February 28, 2017; **Published:** March 01, 2017

### **Abstract**

Medical thoracoscopy or pleuroscopy or local anaesthetic thoracoscopy has become an important tool in the hands of respiratory physician for the diagnosis of unexplained pleural effusion. It is one of the main components of interventional pulmonology. In India it is increasingly becoming common in the management of undiagnosed pleural effusion. The objective of this review is to give our perspective about medical thoracoscopy, its common indications in India and highlights of its importance with case presentation.

**Keywords:** *Medical Thoracoscopy; Thoracoscope; Pleural Effusions; Pleurodesis*

### **Abbreviations**

VATS: Video Assisted Thoracoscopic Surgery; ADA: Adenosine Deaminase; LDH: Lactic Dehydrogenase

### **Introduction**

Medical thoracoscopy / pleuroscopy or local anaesthetic thoracoscopy is used increasingly by chest physicians and has become, after bronchoscopy, the second most important endoscopic technique in respiratory medicine. It is considered to be one of the main areas in the field of interventional Pulmonology [1]. The aim of this review is to give our perspective about medical thoracoscopy and its practice in India.

### **Medical Thoracoscopy**

Compared with “surgical” thoracoscopy, which is better termed “video-assisted thoracic surgery” (VATS) and is performed in an operating room under general anaesthesia with selective intubation, medical thoracoscopy is performed in an endoscopy suite under local anaesthesia or conscious sedation, using non-disposable rigid or semi-flexible (semi-rigid) instruments. Thus, it is considerably less invasive and less expensive.

Given the low complication rate from local anaesthetic thoracoscopy, on site cardiothoracic surgical expertise is not essential [2].

The majority of centres use a rigid thoracoscope with a cold light source, as this allows excellent visualization and inspection of the thoracic cavity, easy photographic and video recording and permits adequate-sized biopsies to be obtained [1,2]. Semi-flexible instruments are available with the potential advantage to respiratory physicians that they are similar in design to bronchoscopes. However, since the working channel is narrower only smaller biopsies can be obtained. In addition these systems are more expensive. Nonetheless, good diagnostic yields have been reported using such instruments. Although majority of thoracoscopies can be performed using a single entry port, a second port may be required in certain circumstances which is to be done by an experienced practitioner only. These include taking pleural biopsies from sites inaccessible via the single port, particularly from the diaphragm, taking larger pleural biopsies, for

“pinch” lung biopsy and to control bleeding. Some operators routinely use a second entry port because it improves visualisation of the pleural space. The second port should be in line with the first and ideally separated from it by two intercostal spaces [1,2].

### Indications

The main indications of this procedure are both diagnostic as well as therapeutic. The diagnostic indications are:

1. Pleural effusions of indeterminate origin,
2. Staging of lung cancer with pleural effusion and of malignant mesothelioma
3. Staging of pneumothorax,
4. Diffuse lung diseases,
5. Hormone receptor determination in breast cancer, localized chest wall (or lung) lesions, culture in tuberculous pleurisy.

The therapeutic indications are:

1. Talc poudrage in malignant pleural effusions and in chronic, recurrent non malignant pleural effusions,
2. Talc poudrage in pneumothorax,
3. Breaking loculations in parapneumonic effusions and empyema

### Contraindications

Contraindications of this procedure are absolute as well as relative:

Absolute contraindications:

1. Lack of a pleural space
2. Uncorrected coagulopathy, and hemodynamic instability
3. Severe Respiratory distress or hypercapnia
4. Uncontrollable cough

Relative contraindications:

1. Very severe obesity which may make the procedure technically difficult
2. Presence of obstructive central tumour
3. A high likelihood of trapped lung
4. Caution during significant comorbid conditions eg ischaemic heart disease, recent MI (procedure should be delayed 4 weeks after the initial event), clotting dysfunction, renal failure and immunocompromised condition

### Complications

Complications of medical thoracoscopy/pleuroscopy are uncommon. They include:

1. Bleeding
2. Infection of the pleural space
3. Injury to intrathoracic organs, atelectasis, and respiratory failure.

Physicians performing this procedure should have ample experience, excellent knowledge of pleural and thoracic anatomy, mature judgment in interpreting radiographic images related to pleural disease, and sufficient surgical skill. Trainees should perform at least 20 procedures in a supervised setting to establish basic competency. To maintain competency, dedicated operators should perform at least 10 procedures per year.

### Our experience

In our experience medical thoracoscopy is very useful in undiagnosed pleural effusion [3] and has greatly helped our patients in reaching

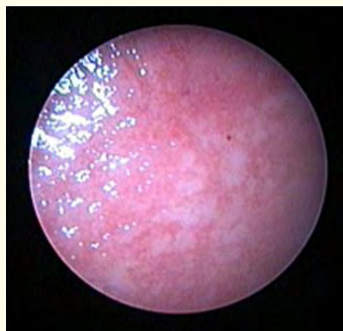
the diagnosis as well as performing talc poudrage in cancer or recurrent pneumothorax patients. The biopsies with rigid thoracoscope are extremely good and more informative. In India in majority of patients the cause of unilateral exudative pleural effusion is tuberculosis. Though with increasing age malignancy becomes the second most common cause after tuberculosis. Most of the cases of tubercular pleural effusion are treated on the basis of biochemical analysis of fluid, blood test, mantoux test positivity and this results in cure of majority of patients. Those who do not respond to the initial treatment become the candidate for pleural biopsy and culture via thoracoscopy [4]. Also those with atypical presentation like normal adenosine aminase (ADA), normal lactic dehydrogenase, negative mantoux test and those with diagnostic dilemma may become a candidate for medical thoracoscopy at the initial presentation. Regarding malignant pleural effusions [5], cytology is negative in significant number of cases, though many studies suggest positivity of around 60% and which may increase with repeated tapping [6]. In pleural mesothelioma, cytology is found to be positive in only 32% of cases. Medical thoracoscopy thus plays an important role in such cases as is found to be better than blind and CT guided pleural biopsies [7,8]. Secondly the efficacy of medical thoracoscopy is found to be as high as for video assisted thoracoscopic surgery [9]. Pleurodesis by talc insufflation (poudrage) is another important indication during thoracoscopy if the pleural is abnormal during initial inspection. Talc poudrage is as effective as talc slurry in malignant pleural effusions and efficacy is found to increase further with talc poudrage in patients without trapped lungs and in lungs and breast carcinoma [10]. Talc poudrage pleurodesis is also effective in primary and secondary pneumonothorax though the current definitive treatment is VATS or monithoracotomy. But if surgery is deemed unsuitable in secondary pneumothorax because of associated risks, medical thoracoscopy may be considered if done by experienced practioners [11,12]. Other indications in the hands of highly experienced practioners are empyema management by breakdown of septations and adhesions and allowing accurate placement of chest tubes [13,14] and pinch lung biopsy in patients with diffuse interstitial lung disease and those with diffuse shadow in immuno-compromised status [15].

### Case discussion

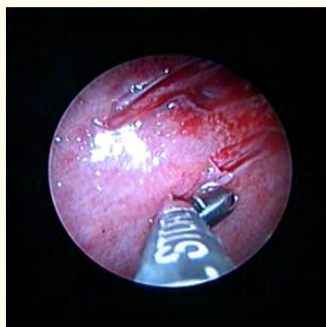Below are the details of two of the many such cases done by us so far:

#### Case 1

Patient of 25 years of age presenting with fever, cough and gradually increasing breathlessness. Chest X-ray was suggestive of unilateral pleural effusion. On tapping, effusion was found to be exudative with predominant lymphocytes but with normal adenosine deaminase (ADA) and lactic dehydrogenase (LDH) levels. Mantoux test was nonconclusive. Patient was referred to us for pleural biopsy via medical thoracoscopy. Pleural biopsy proved it to be tubercular pleural effusion (necrotizing granulomatous inflammation). Thoracoscopy showed classical sago nodules commonly seen in tubercular pleural effusion (Figures 1,2).



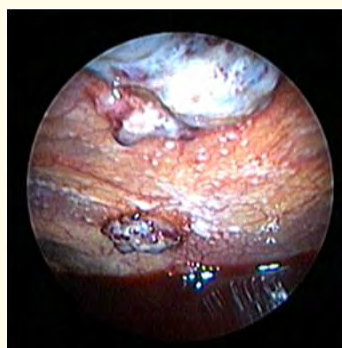**Figure 1:** Sago nodules on parietal pleura.



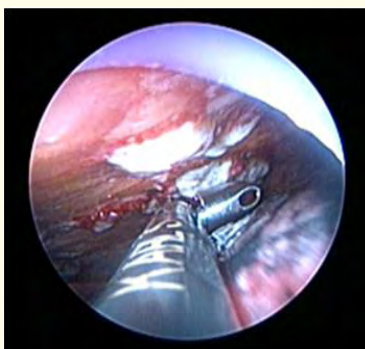
**Figure 2:** Biopsy being taken from pleural surface.

**Case 2**

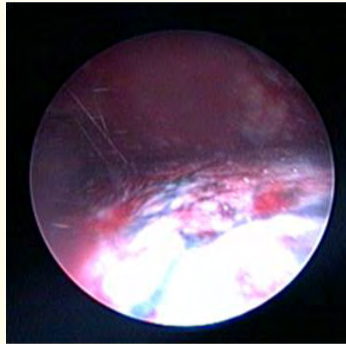
Patient of 55 years of age with past history of Carcinoma Breast for which she was treated with surgery, chemotherapy and radiotherapy. After 2 years of her treatment for carcinoma breast she presented with intermittent fever, cough and gradually increasing breathlessness. Chest X-ray was suggestive of unilateral pleural effusion. On tapping, effusion was found to be exudative with predominant lymphocytes and high ADA and LDH levels. Mantoux test was nonconclusive. Patient was started on antituberculous treatment but did not respond even after 1 month of regular treatment. CECT chest showed large effusion with pleural nodules. Patient was referred to us for pleural biopsy, tissue AFB culture via medical thoracoscopy. Thoracoscopy showed multiple large irregular nodules, hemorrhagic effusion and biopsy confirmed metastatic malignancy. Subsequently patient also underwent talc poudrage for pleurodesis (Figures 3-6).




**Figure 3:** Multiple large irregular nodules with haemorrhagic pleural effusion.



**Figure 4:** Biopsy being taken.



**Figure 5:** Visceral pleura before talc poudrage.



**Figure 6:** Talc Poudrage being done with classical cloudy appearance.

## Conclusions

In conclusion, medical thoracoscopy is an extremely safe procedure in the hands of an experienced respiratory physician. Talc poudrage results in best pleurodesis if done appropriately in malignant pleural effusion. In India, though most of the unilateral exudative effusions are due to tuberculosis, it is important to refer non resolving effusions for medical thoracoscopy and those with diagnostic dilemma at an initial presentation.

## Bibliography

1. Rahman NJ, *et al.* "Local Anaesthetic Thoracoscopy. British Thoracic Society Pleural Disease Guidelines 2010". *Thorax* 65.2 (2010): ii54-ii60.
2. Ernst A, *et al.* "A novel instrument for the evaluation of the pleural space: an experience in 34 patients". *Chest* 122.5 (2002): 1530-1534.
3. Wilsher ML and Veale AG. "Medical thoracoscopy in the diagnosis of unexplained pleural effusion". *Respirology* 3.2 (1998): 77-80.
4. Diacon AH, *et al.* "Diagnostic tools in tuberculous pleurisy: a direct comparative study". *European Respiratory Journal* 22.4 (2003): 589-591.
5. Maskell NA and Butland RJ. "BTS guidelines for the investigation of a unilateral pleural effusion". *Thorax* 58.2 (2003): ii8-ii17.

6. Renshaw AA., *et al.* "The role of cytological evaluation of pleural fluid in the diagnosis of pleural mesothelioma". *Chest* 111.1 (1997): 106-109.
7. Blanc FX., *et al.* "Diagnostic value of medical thoracoscopy in pleural disease: a 6-year retrospective study". *Chest* 121.5 (2002): 1677-1683.
8. Boutin C and Rey F. "Thoracoscopy in pleural malignant mesothelioma: a prospective study of 188 consecutive patients. Part 1: Diagnosis". *Cancer* 72.2 (1993): 389-393.
9. Harris RJ., *et al.* "The impact of thoracoscopy on the management of pleural disease". *Chest* 107.3 (1995): 845-852.
10. Dresler CM., *et al.* "Phase III intergroup study of talc poudrage vs talc slurry sclerosis for malignant pleural effusion". *Chest* 127.3 (2005): 909-915.
11. Tschopp JM., *et al.* "Talc poudrage by medical thoracoscopy for primary spontaneous pneumothorax is more cost-effective than drainage: a randomised study". *European Respiratory Journal* 20.4 (2002): 1003-1009.
12. Heffner JE and Huggins JT. "Management of secondary spontaneous pneumothorax: there's confusion in the air". *Chest* 125.4 (2004): 1190-1192.
13. Brutsche MH., *et al.* "Treatment of sonographically stratified multiloculated thoracic empyema by medical thoracoscopy". *Chest* 128.5 (2005): 3303-3309.
14. Soler M., *et al.* "Treatment of early parapneumonic empyema by "medical" thoracoscopy". *Schweizerische Medizinische Wochenschrift* 127.42 (1997): 1748-1753.
15. Vansteenkiste J., *et al.* "Medical thoracoscopic lung biopsy in interstitial lung disease: a prospective study of biopsy quality". *European Respiratory Journal* 14.3 (1999): 585-590.

**Volume 3 Issue 2 March 2017**

**© All rights are reserved by Vikas Maurya., *et al.***