

Our Experience in Providing Anesthesia During Surgical Interventions for Necrotizing Enterocolitis

Rahimova KHS, Mahammadov VA, Mustafayeva GI and Nasibova EM*

Azerbaijan Medical University, Azerbaijan

*Corresponding Author: Nasibova EM, Department of Pediatric Surgery, Azerbaijan Medical University, Azerbaijan.

Received: September 10, 2024; Published: September 20, 2024

Abstract

Introduction: Necrotizing enterocolitis (NEC) is one of the most common serious acquired diseases of the gastrointestinal tract, both in full-term and premature infants, and is associated with a high risk of complications and high mortality. Anesthetic management for necrotizing enterocolitis in newborns during surgery is a complex task and is still relevant, since the future fate of the patient depends on adequately administered anesthesia.

Purpose of the Study: Optimization of anesthesia during surgery in newborns for necrotizing enterocolitis.

Material and Research Methods: The study was conducted in surgical clinics of the Azerbaijan Medical University. The paper presents the results of treatment of 96 patients based on the assessment of clinical indicators of preoperative preparation, anesthesiological care, and the study of central hemodynamics in newborns operated on for necrotizing enterocolitis. Newborns were divided into 2 groups depending on the method of anesthesia used: group I with general anesthesia and group II with general anesthesia using caudal anesthesia.

Results: The results of this study showed that effective interruption of nociceptive impulses from the surgical site through caudal blockade and sufficient sedation can prevent pronounced activation of the body's neurohumoral reactions to surgical stress under conditions of balanced regional anesthesia, and it was also revealed that the modern muscle relaxant rocuronium bromide allows the concept of multicomponent anesthesia to be implemented, causing complete relaxation of the striated muscles during surgery, which helps to effectively block pathological reactions in response to surgical stress.

Keywords: Newborns; Necrotizing Enterocolitis; Caudal Anesthesia

Background

Necrotizing enterocolitis (NEC) is one of the most common serious acquired diseases of the gastrointestinal tract, both in full-term and premature infants. Studies show that the incidence of NEC among newborns is 2.4 per 1000 children. It was found that NEC in premature newborns occurs 12 times more often than in full-term patients [1]. During the neonatal period, NEC occurs in 2 - 16% of cases, depending on gestational age, about 80% of which occur in premature infants with low birth weight [2-5]. In premature infants, NEC occurs in 15 - 30% of cases [3,6,7]. The incidence of NEC in newborns, according to various researchers, ranges from 0.3 to 5 per 1000 children. Risk factors for the development of NEC include prematurity, hypoxia (asphyxia), congenital malformations, hypothyroidism, Down syndrome, etc. [1,3,5,9,14]. 50% of newborns have a perinatal history complicated by infection [4,7,13]. Children are cultured for *E. coli*, *Staphylococcus*, *Chlamydia*, and *Enterobacteria*. Necrotizing enterocolitis is a common disease of newborns that requires emergency care [1,2,4,6]. Over the last decade, there has been a trend towards a decrease in mortality from NEC (17% in developed countries, 42% in countries with low

and middle levels of economy) [2,3,5,6]. The success of treatment of children with NEC depends on many factors, especially on timely diagnosis of the transition of the disease from the therapeutic to the surgical stage. The absolute indications for surgical intervention are peritonitis, pneumoperitoneum, deterioration of general condition (stage III according to the Bell classification) [1-3,5]. Mortality rates depend on the degree of maturity, stage and extent of the process. Mortality due to perforation and peritonitis reaches 63% or more [1,2,6,8,11,14].

The mortality rate is significantly higher in the group of premature newborns, among children with intrauterine growth retardation syndrome and ranges from 28 to 54% [8-10], and after surgical interventions - 60%, despite the development of modern technologies for the care and treatment of newborns, as well as on the intensive joint efforts of neonatologists, pediatric surgeons, and anesthesiologists and resuscitators. In countries where the rate of premature births is low (Japan, Switzerland), NEC is less common - with a frequency of 2.1% among all children admitted to neonatal intensive care units [4,8]. Approximately 10% of patients with NEC are full-term newborns with polycythemia, cyanotic heart defects, or obstructive gastrointestinal malformation. NEC usually occurs in the first 2 weeks of the child's life, but in children weighing less than 1000g, its onset can be delayed up to 3 months. The lower the birth weight, the more often, but later, NEC can develop.

Preoperative preparation is aimed at stabilizing the vital functions of the body, usually lasts no more than 2.5 - 3 hours and includes [5,9,12]:

- With the development of respiratory failure, selection of adequate ventilation parameters that ensure normal gas exchange under conditions of increasing intra-abdominal pressure.
- Correction of hemodynamic disorders, stabilization of blood pressure.
- Correction of water-electrolyte balance and indicators of acid-base status on the basis.
- Correction of hypovolemia, restoration or maintenance of diuresis at a level of at least 1.5 - 2.0 ml/kg/hour.
- If necessary, transfusion of blood transfusion solutions.
- Administration of broad-spectrum antibiotics and gamma globulin intravenously.
- Warming the child and maintaining body temperature at a normal level by placing him in an incubator with a temperature of 37°C and a humidity of about 100%.

The patient's readiness for surgery is judged by stabilization of hemodynamics and gas exchange, normalization of diuresis, elimination of electrolyte disturbances and metabolic acidosis. And if the child's condition and the degree of disruption of homeostasis are such that 2 - 3 hours of preparation does not give the desired result, it must be extended. When treating children with NEC who are in extremely severe or terminal condition, the use of a surgical method using laparocentesis is indicated. Laparocentesis with drainage of the abdominal cavity can reduce intra-abdominal pressure, alleviate the child's condition and prepare him for laparotomy. Laparocentesis can be performed in the intensive care unit: under local anesthesia S. Procaini 0.25% - 5.0 ml through a point 1.5 cm below the umbilical fossa, a drainage tube is inserted into the abdominal cavity, through which air and intestinal contents accumulated in the abdominal cavity are discharged. Then intensive preoperative preparation is carried out aimed at stabilizing the vital functions of the body, such as mechanical ventilation, infusion therapy, inotropic support, broad-spectrum antibiotics, etc.) [13]. Anesthetic management for necrotizing enterocolitis in newborns during surgery is a complex task and is still relevant, since the future fate of the patient depends on adequately administered anesthesia. Our analysis of the numerous literature has shown that today there is virtually no data regarding specific issues of anesthesia in newborns and premature infants suffering from necrotizing enterocolitis. The question of the types and doses of anesthetics used, the advisability of using muscle relaxants remains debatable, and issues regarding the volume and composition of infusion therapy in the perioperative period have also not been resolved. Data from numerous studies indicating a high mortality rate among operated newborns (18 - 40%) once again confirm the relevance of the problem we are studying [12-14].

Thus, the relevance of the problem of NEC is determined by the high frequency of this pathology, the lack of a common understanding of the time and volume allocated for preoperative preparation and the choice of anesthesia method.

Purpose of the Study

Optimization of anesthetic management during surgery in newborns for NEC.

Materials and Methods of Research

The study was conducted in surgical clinics of the Azerbaijan Medical University. The paper presents the results of treatment of 96 patients based on the assessment of clinical indicators of preoperative preparation, anesthesiological care, and the study of central hemodynamics in newborns operated on for NEC. Newborns were divided into 2 groups depending on the anesthesia method used:

1. Group I (48 children): Multicomponent anesthesia was performed using inhalation anesthetics. Depending on the type of inhalational anesthetic used, this group was randomized into 2 subgroups:
 - IA subgroup (24 children): Anesthesia was performed using the inhalation anesthetic halothane, fentanyl and the muscle relaxant rocuronium bromide;
 - Subgroup IB (24 children): Anesthesia was performed using the inhalation anesthetic sevoflurane, fentanyl and the muscle relaxant rocuronium bromide.
2. Group II (48 children): Multicomponent anesthesia was performed using non-inhalational anesthetics and caudal blockade. This group was also divided into 2 subgroups depending on the type of non-inhalational anesthetic and caudal anesthesia used:
 - IIA subgroup (24 children): Anesthesia was performed using the non-inhalation anesthetic propofol and a caudal block;
 - Subgroup IIB (24 children): Anesthesia was performed using dormicum, fentanyl and rocuronium bromide.

The compared groups were comparable in weight and age of newborn children. The characteristics of the patient group are presented in table 1.

| Indicators | Quantity |
|----------------------------|--------------|
| Total number of patients | 96 |
| Gender of patients: | |
| -Boys | 56 |
| -Girls | 40 |
| Birth weight (g) | 2430,3 ± 850 |
| Gestational age (weeks) | 35,7 ± 0.3 |
| Age at admission (days) | 5,1 ± 0,15 |

Table 1: General characteristics of the examined newborns.

Necrotizing enterocolitis develops more often in newborns in the first week of life. Surgical treatment predominates in children older than the 7th day of life.

Studies were carried out in each patient at the following stages of anesthesia and surgery:

- Stage I - 1 hour before surgery;
- Stage II - Start of the operation;
- Stage III - Traumatic moment of the operation;
- Stage IV - Awakening of the patient.

To assess the degree of risk of surgical treatment, we used a modified map for assessing the degree of risk of surgery and anesthesia, proposed by T.V. Krasovskaya. It scored certain indicators of the premorbid background of the newborn: 1) Apgar score, 2) birth weight, 3) degree of cerebral circulatory insufficiency, 4) the presence of concomitant malformations, 5) the presence of pneumonia, respiratory distress syndrome.

Since only premorbid background indicators were assessed, all newborns were divided into three risk levels. The total scores of children classified as the first degree of risk ranged from 0 to 20 points. This group included children with disorders of adaptive functions with a burdened premorbid background, mainly due to low birth weight. They had a minimal risk of anesthesia and surgery and a favorable treatment prognosis. Children with the second degree of risk had disorders of adaptive functions due to the premorbid background, mainly due to cerebral circulation disorders with unstable adaptation of the body. They required longer preparation and symptomatic treatment before surgery. Their prognosis is favorable. The third degree included children who had serious violations of adaptation mechanisms due to premorbid background indicators, combined malformations of vital organs and severe intracranial trauma. The prognosis for treatment in this group of patients is unfavorable.

Scheme of general anesthesia

Induction of anesthesia: Induction in groups with inhalational anesthetics was carried out using an endotracheal method: a gas-narcotic mixture. After the onset of narcotic sleep, fentanyl 0.005% was injected intravenously at a rate of 3 mcg/kg, and then after 40 - 60 seconds the muscle relaxant under study, rocuronium bromide, was administered at a dosage of 0.5 mg/kg.

In groups without the use of inhalational anesthetics, induction was carried out with intravenous administration of relanium at a rate of 0.2 mg/kg and fentanyl at a rate of 3 mcg/kg, as well as propofol at a rate of -2.5 mg/kg. Next, preoxygenation was carried out in manual ventilation mode. Orotracheal intubation of the trachea was carried out when a sufficient level of myoplegia was achieved (decrease in T1 to < 10%). After tracheal intubation, a caudal blockade was performed with the local analgesic lidocaine at a dose of 6 mg/kg. Hardware mechanical ventilation was carried out with ventilation parameters maintaining $ETCO_2$ at the level of 35 - 45 mm Hg. Art.

Maintaining anesthesia: Anesthesia was maintained in group 1 with inhalational anesthetics and narcotic analgesics. In the second group, non-inhalational anesthetics. Neuromuscular block was maintained with repeated bolus injections of the study muscle relaxant; 1/2 of the initial dose of the drug. The introduction of each subsequent dose of the drug was carried out when the T1 indicator was > 25%.

All patients received infusion therapy during surgery. Transfusions of single-group red blood cells were carried out strictly according to indications when the Hb value was less than 100 g/l.

Coming out of anesthesia: At the end of the operation, all inhalational and non-inhalational anesthetics were stopped. Tracheal extubation was carried out after restoration of adequate spontaneous breathing, muscle tone and reflexes, and according to the neuromuscular conduction monitor (T1 recovery > 90%, TOF > 75%).

Method of performing caudal blockade

There are three main approaches: The prone position, the side position, and an intermediate position between the stomach and side. In children, the lateral position is usually used because anatomical landmarks are easier to detect in them than in adults. Puncture of

the caudal epidural space was carried out with the patient positioned on the left side with the hips and knees adducted to the chest. The caudal blockade technique involves reaching the epidural space through the sacrococcygeal membrane, i.e. significantly below the level at which the spinal cord and dura mater terminate. The cutaneous projection of the hiatus sacralis corresponds to the vertex of an equilateral triangle, the remaining vertices of which are the cutaneous projections of the right and left posterior iliac spine. Guidelines for choosing a puncture site are: the sacrococcygeal joint (base of the coccyx), cornu sacralis, median crest of the sacral bone. These landmarks were determined by palpation. The sacrococcygeal membrane is localized in a triangular space bounded by the cornu sacralis on the sides and the sacrococcygeal joint below. On palpation, the site of the sacrococcygeal membrane is felt like a pit with an elastic bottom. The puncture site is a point located at the intersection mutually perpendicular to the line connecting the cornu sacralis and the line passing through the canalis sacralis and the sacrococcygeal joint (the center of the sacrococcygeal ligament). We performed a puncture higher between the cornu sacralis due to the greater thickness of the membrane at this level, which made it possible to more clearly feel the “loss of resistance” when passing through it with a needle. Because there is significant anatomical variation, identification of bony landmarks is the key to success. The needle can perforate various structures, giving sensations of penetration into the sacral canal. It is very important to establish the midline of the sacrum, since the variability of the horns of the sacrum can lead to problems with careless puncture of the sacral foramen.

All necessary materials, syringes and solutions of local anesthetics must be prepared in advance, on a sterile table covered with a sterile diaper. This allows you to reduce the blockade execution time to a minimum. The skin over the area of the sacrum and coccyx and adjacent areas are carefully treated first with 5% Betadinom, then with 96% alcohol, and the puncture site is delimited by sterile sheets to prevent contamination from the anal area. We consider it mandatory to use sterile surgical gloves when performing a caudal block. When performing caudal anesthesia in newborns, it is recommended to use special 19-21G needles intended for epidural anesthesia. It is also possible to use a simple sterile disposable injection needle. The sufficient internal diameter of these needles allows you to quickly see the reflux of blood or cerebrospinal fluid into the needle pavilion when it enters the lumen of a vessel or punctures the dural sac. On the other hand, a sufficient outer diameter makes these needles rigid and allows the passage of the needle through the membrane to be clearly felt. The length of the needle should not exceed 3 - 4 centimeters, since the distance from the surface of the skin to the caudal space does not exceed 20 millimeters. The needle was inserted at an angle of 60 degrees to the surface of the skin until the sacrococcygeal ligament was pierced, which in most cases was accompanied by a sensation of “loss of resistance” or a “clicking” sensation. After this, the needle pavilion approached the skin and the needle carefully moved forward another 2 - 3 mm, in the cranial direction, at an angle of 30-40 degrees to the surface of the skin. This additional advancement of the needle ensures that its entire bevel will be located under the sacrococcygeal membrane and the entire volume of local anesthetic enters the sacral space. Also, it must be remembered that the tip of the needle should not be advanced cranially to a great depth due to the fairly large variability in the level of location of the dural sac. Also, it must be remembered that you do not need to insert the needle too far, since the dura mater in children ends at the S2 level or even lower. At birth, the level of the newborn’s dural sac is at S3-S4; it rises to level S2 only when the child reaches two years of age, without changing its level over the subsequent years of life. Due to the low location of the dural sac in infants, the risk of subarachnoid puncture during caudal anesthesia in this category of patients increases significantly. Based on the above, primary importance when performing a caudal block in newborns should be given to technical components. The caudal space is located in the lowest portion of the epidural space. According to its anatomical structure, the sacrum is represented by a triangle consisting of five cruciate vertebrae fused together (S1-S5). The sacrum in children of the younger age group is a cartilaginous structure that finally ossifies by the age of 25. When the vertebral arches are not fused in the sacral area, the risk of dural puncture during caudal blockade increases significantly. On the contrary, with complete fusion, the absence of the sacral foramen makes the caudal block impossible.

The caudal foramen is located on the lower part of the posterior wall of the sacrum and is formed by the plates S5 and S4. There are various options for the anatomical structure of the sacral canal, which is a continuation of the lumbar region and ends in the sacral foramen.

The structure of the sacral canal is presented as:

- 1) Terminal part of the dura mater (level S1-S3);
- 2) Five sacral nerves and coccygeal nerves;
- 3) The terminal part of the spinal cord, which does not contain nerves;
- 4) Epidural fiber, the consistency of which varies from soft to fibrous depending on the age of the person.

Free communication between the caudal space and the perineural space of the spinal nerves during caudal blockade allows for adequate analgesia, including the lower extremities.

After inserting the needle into the caudal space, it is necessary to carefully examine the needle pavilion for a short time (10 - 15 seconds) for free flow of blood or cerebrospinal fluid. If blood appears in the needle pavilion, it is removed, after which another attempt is made using a new needle. Then the needle is intercepted by the fingers of the left hand and, using the support created by the base of the palm on the surface of the sacrum, it is precisely fixed in its position for the entire period of insertion. Using the second hand, the syringe is connected, the first aspiration test is performed, after which the local anesthetic solution is administered. The recommended duration of anesthetic administration should be 60-90 seconds, because very rapid injection can increase intracranial pressure, slow injection can cause lateralization of the block. It should be taken into account that children under 3 years of age are characterized by a relatively lower latency of local anesthetics compared to children of older age groups.

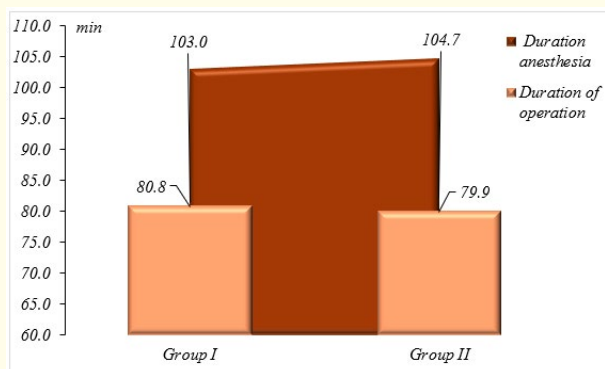
After administration of the local anesthetic is completed, the needle is removed, the newborn is placed on his back, and the child's head is slightly elevated for optimal distribution of the local anesthetic. Intraoperative standard monitoring of blood pressure, ECG, pulse oximetry is required.

Research Results and Discussion

To assess the characteristics of anesthesia, 96 newborns with stage III NEC were examined. Depending on the type of anesthesia used, patients were divided into 2 groups and 4 subgroups. The distribution of newborns by age, duration of anesthesia and surgery is presented in table 2 and graph 1.

| Group | Age at the time of surgery | Duration of anesthesia (min) | Operation duration (min) |
|-------------------|----------------------------|------------------------------|--------------------------|
| Newborns with NEC | 9,7 ± 0,6 days | 103,7 ± 1,8 | 80,4 ± 1,8 |

Table 2: Values of indicators of age, duration of anesthesia and surgery in examined newborns (M ± m).



Graph 1: Duration of anesthesia and surgery in groups of newborns with NEC.

As can be seen from graph 1, the duration of anesthesia and surgery in both groups did not differ significantly and amounted to an average of 103.7 ± 1.8 minutes for all examined newborns with NEC, respectively. and 80.4 ± 1.8 min (Table 2).

The ideal inhalational anesthetic for pediatric surgery should cause rapid and smooth induction, provide intraoperative analgesia and amnesia, and rapid awakening with a minimum of side effects. These requirements are best met by the “third generation” inhalational anesthetics - sevoflurane, desflurane and xenon, the most widely used of which in our clinic in children is sevoflurane. The main requirements for the use of an inhalational anesthetic in pediatric anesthesiology are: absence of a pungent odor and irritating effect on the upper respiratory tract, low flammability, safety, low toxicity, rapid onset and end of action, low MAC, high anesthetic activity, good fat solubility, minimal cardiodepressive effect. action and respiratory depression, good analgesic effect, dose-dependent muscle relaxation. Among modern inhalational anesthetics, sevoflurane is the closest to the requirements. The extremely low solubility of sevoflurane in the blood provides rapid induction comparable to intravenous induction with propofol, and the low fat/blood partition coefficient provides the same rapid awakening. The low level of biotransformation of sevoflurane creates the prerequisites for reducing side effects to a minimum. Also, the use of low-soluble anesthetics, along with the use of instrumental control methods, creates conditions for high controllability of the depth of anesthesia. During the study, we used and studied various options for inducing anesthesia with sevoflurane in newborns operated on for NEC.

At the beginning of the work, we determined the features of step-by-step induction of anesthesia with sevoflurane with oxygen without first filling the breathing circuit. This anesthesia technique consisted of the following sequence of actions:

1. Turn on oxygen with a flow of 6 l/min;
2. Place a mask on the patient's face;
3. Set the sevoflurane evaporator to 2 - 3 vol%, then every 3 - 4 patient breaths, increase the sevoflurane concentration on the evaporator by 1 vol% until a maximum value of 5 - 6 vol% is reached.
4. Continue induction against the background of calm, preserved breathing of the patient until signs of the development of the surgical stage of anesthesia appear (central location of the pupils, calm, even breathing, absence of motor response during venipuncture and catheterization of a peripheral vein).

During the application of this technique, we identified the following negative aspects of this technique:

- Slower technique;
- Prolongs the excitation phase;
- Higher level of cough and agitation compared to other methods.

Also, during the study, induction anesthesia was studied with preliminary filling of the breathing circuit of the anesthesia machine with a mixture containing 5-6 vol% sevoflurane, which is called “bolus”.

The main feature of the “bolus” induction method with sevoflurane, which ultimately determines the speed, safety, frequency of complications and cost of induction anesthesia, is that already with the first breath at the induction stage the patient receives a mixture containing sevoflurane in high concentration. To do this, you must first fill the breathing circuit of the anesthesia machine with this mixture. When performing induction using this method, one of the main points is the correct filling of the breathing circuit with inhalational anesthetic. According to the screen of the gas analyzer installed on the anesthesia machine, when the sevoflurane concentration on the evaporator was initially set to 6 vol% and the gas flow on the rotameters was 6 l/min after 1 min. the concentration of anesthetic in the

circuit increased quickly and amounted to 3.1 vol%, after 2 minutes 4.9%, then the process slows down and by the end of 3 minutes the concentration of sevoflurane in the circuit increases to 5.4%, and after 4 minutes it is 6.0%. The slowdown in the process of saturation of the circuit with anesthetic over time is exponential in nature, since the filling rate is a derivative of the pressure gradient between the evaporator and the circuit.

However, there was no clinical difference in the rate of induction of anesthesia with a sevoflurane concentration in the circuit of 4.9% (2 minutes from the start of filling) or 6.0% (4 minutes from the start of filling). But filling the circuit with a gas mixture containing lower concentrations of sevoflurane or reducing the gas flow when filling the circuit led to a significant increase in the saturation time of the circuit and increased consumption of sevoflurane. Also, it should be noted that this technique of induction of anesthesia with preliminary “bolus” filling of the breathing circuit to high concentrations of sevoflurane (6 vol%), induction with maintaining a high concentration for 2 - 4 minutes, using a high flow of fresh gas (4 - 6 l/min) and a slight positive end-expiratory pressure in the breathing circuit (5 cm H₂O) is called the “over-pressure” method. This technique reflects the desire to accelerate the process of saturation of the alveolar space, blood and tissues with an anesthetic and, therefore, helps to accelerate the loss of consciousness and the development of anesthesia. This is an advantage of this technique both for the patient, who sometimes does not even have time to remember the smell of the drug - psychological comfort, and for the anesthesiologist (fast induction, comparable in speed to intravenous anesthesia with propofol). If, at the time of the start of induction, the child, on command, can take a deep breath from a circuit filled with a high concentration of inhalational anesthetic and hold his breath at the height of inspiration for several seconds, while loss of consciousness occurs by the end of 2 - 4 breaths of the gas-narcotic mixture from the breathing circuit. This method is also called “bolus” induction, which is used specifically in the case of induction of anesthesia with sevoflurane, where the term “bolus” reflects the rapid saturation of the body with the drug, especially the rapid increase in the concentration of sevoflurane in the brain tissue when the anesthetic enters the alveolar space in high concentrations. With this technique, induction of anesthesia lasts 2 - 5 minutes. After 2 minutes, venipuncture and catheterization are performed, if this is not done in the ward. Next, the concentration of sevoflurane is reduced to 0.5 - 1.0 vol% and fentanyl is administered at a dose of 1 - 3 mcg/kg. The maintenance concentration of sevoflurane is 1 - 1.3 MAC. On the rotameters of the anesthesia machine, a high fresh gas flow of 4 - 6 l/min is maintained for 2 minutes after the “bolus” induction of anesthesia. After 2 minutes, the oxygen supply is reduced to 1 l/min and the skin incision begins.

This technique is simpler than the previous one, since it does not require the participation of the patient and is convenient especially when performing anesthesia in young children. The rate of redistribution of gases between different spaces (respiratory circuit, alveolar space, blood, brain) is directly dependent on their partial pressure in them. Consequently, the higher the concentration of anesthetic in one space, the faster it will increase in an effort to equalize in another space. In practice, when carrying out inhalational induction of anesthesia, with an increase in the concentration of anesthetic in the respiratory circuit and, accordingly, in the alveolar space, the concentration in the blood and brain will increase. Due to the physicochemical properties of sevoflurane (low blood/gas partition coefficient), the concentration of anesthetic in brain tissue will increase very quickly during bolus induction of anesthesia. After the induction period of anesthesia, the concentration of sevoflurane in the breathing circuit, alveolar space and brain tissue remains very high. Maintaining a high gas flow for 2 minutes after completion of induction and transition to maintenance of anesthesia with sevoflurane is necessary to quickly reduce the concentration of anesthetic in the respiratory circuit and alveolar space. Failure to comply with this recommendation may result in an overdose of the anesthetic and the development of toxic effects of sevoflurane, such as arterial hypotension, arrhythmia as a result of continued redistribution of high concentrations of sevoflurane from the alveolar space into the blood and brain tissue along a concentration gradient with a decrease in gas flow and slower leaching of the anesthetic from the respiratory circuit.

Inhalation induction of anesthesia with sevoflurane will be fast and safe for the patient and medical personnel if the algorithm for its implementation is correctly followed: 1) correct filling of the breathing circuit, maintaining gas flow parameters and sevoflurane concentration indicators on the evaporator and in the breathing circuit of the device; 2) careful tightness of the “patient-anesthesia

machine” system; 3) maintaining a high gas flow in the breathing circuit for another 1 minute after completion of induction of anesthesia and transition to the maintenance concentration of anesthetic.

Anesthesia with sevoflurane was assessed in 25 newborns with NEC using rapid “bolus” inhalation induction. The technique was carried out by inhaling high-concentration sevoflurane vapor (bringing the anesthetic concentration to 4% was carried out within 1 minute from the moment of applying the face mask at a gas flow of 4-5 l/min). After the patient was rendered unconscious and he lost motor activity, the concentration of the drug was reduced to 1.5 - 2.0 vol%. Induction was characterized by a rapid loss of consciousness within 2'12" ± 18.5". All patients had no psychomotor agitation and irritation of the respiratory tract in the form of hiccups, breath holding, hypersalivation, laryngospasm, bronchospasm. The studies were carried out four times for each patient at the following stages:

- Stage I - Before anesthesia;
- Stage II - After induction of anesthesia;
- Stage III - Traumatic moment of the operation;
- Stage IV - End of the operation.

After falling asleep, fentanyl was administered at a dose of 2 - 3 mcg/kg intravenously. Intubation was performed after administration of 0.5 mg/kg rocuronium bromide. During induction of anesthesia, an increase in respiratory rate was noted with SpO₂ 99 - 100%. Anesthesia was maintained with oxygen and sevoflurane at a concentration of 1.5 - 2% (MAC 0.7-0.9), depending on the traumatic nature of each stage of the operation and the patient's hemodynamic response. At the last stage of the operation (layer-by-layer suturing of the wound), the concentration of the anesthetic was reduced to 0.8 vol%; when sutures were placed on the skin, the supply of the gas-narcotic mixture was stopped and the inhalation of pure oxygen was switched to.

After stopping the supply of the gas-narcotic mixture, all parameters of hemodynamics and external respiration were quickly restored to their original values. The awakening happened quickly. Immediately after applying the last skin sutures, muscle tone was restored, and a clearly expressed motor reaction to a painful stimulus appeared. Restoration of consciousness occurred approximately 10 minutes after the end of the operation. 10 patients required prolonged mechanical ventilation, the rest, breathing spontaneously, were transferred to the intensive care unit.

Thus, a comparative assessment of the clinical course of various methods of anesthesia with sevoflurane in newborns operated on for NEC made it possible to determine the time of onset of the surgical stage of anesthesia, characterized by the central location of the pupils and the lack of response to weak painful stimuli (vein puncture), with “bolus” induction of anesthesia significantly less than with the “step-by-step” (“step-by-step”) method. The frequency and severity of manifestations of agitation in children who underwent “step-by-step” induction of anesthesia with sevoflurane were significantly greater than with the “bolus” method. The method of “step-by-step” induction with sevoflurane was significantly inferior in speed and comfort to rapid inhalation anesthesia. Therefore, we considered it more appropriate to use the “bolus” induction technique with sevoflurane during surgical interventions for NEC in newborns.

A study of central hemodynamic parameters relative to the first stage during multicomponent anesthesia with sevoflurane is presented in table 3. Induction of anesthesia was accompanied by a slight increase in stroke volume (SV) by 2.1%, minute volume of blood circulation (MCV) by 2.6%, and a decrease in OPSS by 2.8%, and no statistically significant changes were observed in heart rate (0.1% increase) and mean arterial pressure (0.4% increase). At the traumatic stage and at the last stage of the study, we found a decrease in heart rate by 5.7% (p < 0.01) and 6.2% (p < 0.001), an increase in mean arterial pressure by 6.8% (p < 0.01) and 7.8% (p < 0.01), respectively. TPR increased in the third and fourth stages of the study by 12.1% and 14.5%, respectively. The slight change in mean arterial pressure values indicated that this was likely due to the milder hemodynamic effect of sevoflurane. The study of CBS and electrolytes did not reveal statistically significant deviations from the initial values.

| Stages | Stroke volume, ml | Total peripheral vascular resistance dyn s cm ⁵ | Minute volume of blood circulation, l/min | Heart rate | Systolic blood pressure mmHg | Diastolic blood pressure, mmHg | Mean arterial pressure mmHg |
|--------|-------------------|------------------------------------------------------------|-------------------------------------------|-------------------------|------------------------------|--------------------------------|-----------------------------|
| I | 8,9 ± 0,08 | 642,3 ± 32,5 | 1,28 ± 0,02 | 144,6 ± 1,9 | 72,2 ± 1,3 | 36,0 ± 0,8 | 53,3 ± 0,9 |
| II | 9,08 ± 0,1 | 624,1 ± 30,0 | 1,31 ± 0,02 | 144,8 ± 1,5 | 73,9 ± 1,6 | 35,1 ± 0,9 | 53,5 ± 1,1 |
| III | 9,1 ± 0,14 | 719,8 ± 36,7 p<0,01* | 1,24 ± 0,02 | 136,4 ± 1,4 p<0,01* | 78,6 ± 1,8 p<0,01* | 37,2 ± 0,8 | 56,9 ± 0,9 p<0,01* |
| IV | 9,03 ± 0,12 | 735,4 ± 33,4 p<0,001* | 1,22 ± 0,02 p<0,05* | 135,6 ± 1,7 p<0,001* | 79,3 ± 2,0 p<0,01* | 37,9 ± 0,7 | 57,4 ± 1,0 p<0,01* |

Table 3: Dynamics of changes in hemodynamic parameters in newborns with NEC when using sevoflurane.

Note: *Statistical significance of the difference in the indicator relative to the value at stage I.

The clinical course of anesthesia with caudal blockade and non-inhalational anesthetics was performed in 29 patients operated on for NEC. Premedication in children of this group was carried out using Dormicum at a rate of 0.1 mg/kg on the operating table. Atropine was not administered to patients in this group, since we chose dormicum as the induction drug. Induction of anesthesia in patients in this group was carried out using dormicum at a rate of 0.1 mg/kg. In all patients, tracheal intubation was performed after intravenous administration of 2 mcg/kg fentanyl and the non-depolarizing muscle relaxant rocuronium bromide at a rate of 0.5 mg/kg. If the effect of the caudal block was successful, anesthesia was maintained in patients in this group using fluorothane 0.2-0.4 vol%. When an effective caudal block was obtained, there was no need to support myoplegia with the administration of muscle relaxants.

All patients operated on for NEC underwent volume-controlled artificial ventilation in the IPPV mode using a Fabius Drager device along a semi-closed circuit, with ventilation parameters ensuring maintenance of ETCO₂ within 35 - 40 mmHg. Puncture of the caudal space was carried out in a position on the left side with the lower limbs bent at an angle of 90° at the hip and knee joints. To calculate the dose of lidocaine, we used the titration method. Using the titration method, we determined the optimal dose of lidocaine 6 mg/kg for surgical intervention for NEC in newborns. Once the local anesthetic injection was completed, the needle was removed and the child was placed in a supine position. The time from the moment of drug administration into the caudal space to the start of the operation (latent period) was at least 10 - 15 minutes.

The fundamental point of the technique we use is the preventive nature of performing a caudal blockade of afferent nociceptive pathways before the start of surgery, which makes it possible to more effectively prevent the activation of pain receptors and the development of hypersensitivity of dorsal horn neurons in response to tissue damage.

Assessing the effectiveness of analgesia

The effectiveness of intra- and postoperative analgesia achieved in connection with combined general anesthesia with caudal blockade was assessed based on hemodynamic parameters, as the most dynamic in terms of the body's nociceptive reactions. Nociceptive stimuli cause reflex activation of the sympathetic nervous system, which is considered part of the body's overall defense response to stress. Sympathetic activity increases: ventricular contractility (causing an increase in systolic pressure in the left ventricle), the rate of increase in intraventricular pressure, mean arterial and pulse pressure, coronary blood flow, myocardial oxygen consumption. In connection with the above, to assess the effectiveness of intra- and postoperative analgesia, the above hemodynamic indicators were used, which were recorded at the following stages:

- Stage I - Before anesthesia;
- Stage II - After induction of anesthesia;

- Stage III - Traumatic moment of the operation;
- Stage IV - End of the operation, stroke volume and minute volume of blood.

With the restoration of consciousness in the postoperative period, a “pain scale” was used to assess the effectiveness of pain relief. To assess postoperative pain in adult patients, various modifications of the “visual analogue pain scale” are used, which include the patient’s subjective sensations. To date, numerous versions of the “pain scale” have been proposed for children of different age groups, based on an objective analysis of changes in the patient’s behavior and registration of individual physiological indicators. In our study, the effectiveness of the caudal block, after restoration of consciousness, was assessed based on the “pain scale” proposed by Hannallah R.S., Broadman L.M., *et al* (1987). The authors used this pain scale to comparatively evaluate the effectiveness of pain relief during caudal anesthesia and n.n. blockade, ilioinguinalis (iliohypogastricus/iliohypogastricus in children (Table 4). Dynamic assessment of caudal analgesia using a selected pain scale was carried out from the moment the patient was transferred to the recovery room and during the 2-hour postoperative period, with an interval of 30 minutes, or when changes in the patient’s condition occurred.

| Indicators | Criteria | Number of points |
|-------------------|--------------------------------------------|------------------|
| Arterial pressure | +10% from preoperative level | 0 |
| | >20% of preoperative level | 1 |
| | >30% of preoperative level | 2 |
| Scream | Lack of screaming | 0 |
| | Screams, but reacts to touch question | 1 |
| | Screams, no reaction | 2 |
| Movements | The body is relaxed, does not move | 0 |
| | Muscle rigidity, forced position | 1 |
| | Restless chaotic movements | 2 |
| Excitation | The patient is sleeping or in a calm state | 0 |
| | Mild degree of excitement | 1 |
| | Pronounced excitement | 2 |
| Verbal response | Sleeping or not complaining of pain | 0 |
| | Non-localized pain | 1 |
| | Localized pain | 2 |
| Total points | | 10 |

Table 4: Pain scale for assessing the effectiveness of caudal epidural anesthesia in the postoperative period (Hannallah-Broadman).

The adequacy of pain relief using a pain scale was assessed by an anesthesiologist or a trained ward nurse. A total score of less than 4 was considered satisfactory analgesia.

Thus, the results of this study showed that effective interruption of nociceptive impulses from the surgical site through caudal blockade and sufficient sedation can prevent pronounced activation of the body’s neurohumoral reactions to surgical stress under conditions of balanced regional anesthesia, and it was also revealed that the modern muscle relaxant rocuronium bromide allows for the concept of multicomponent anesthesia, causing complete relaxation of the striated muscles during surgery, which helps to effectively block pathological reactions in response to surgical stress.

Conclusion:

1. Having compared the outcomes of surgical treatment, it was determined that the caudal block as part of general anesthesia is the optimal method of anesthetic protection in newborns with NEC.
2. A decrease in cortisol levels at stage 3 of the study by 10% ($p < 0.05$) from the initial level, a decrease in heart rate by 9.2%, a decrease in IOC by 10.4% when using a caudal block, indicates the adequacy of the anesthesia used.

Bibliography

1. Aukes DI, et al. "Pain management in neonatal intensive care: evaluation of the compliance with guidelines". *Clinical Journal of Pain* 31.9 (2015): 830-835.
2. Allin BSR, et al. "One-year outcomes following surgery for necrotising enterocolitis: a UK-wide cohort study". *Archives of Disease in Childhood. Fetal and Neonatal Edition* 103.5 (2018): F461-F466.
3. Alsaied A, et al. "Global incidence of necrotizing enterocolitis: a systematic review and meta-analysis". *BMC Pediatrics* 20.1 (2020): 344.
4. De Bernardo G, et al. "Management of NEC: Surgical treatment and role of traditional x-ray versus ultrasound imaging, experience of a single centre". *Current Pediatric Reviews* 15.2 (2019): 125-130.
5. Carr B D and Gadepalli S K. "Does surgical management alter outcome in necrotizing enterocolitis?". *Clinics in Perinatology* 46.1 (2019): 89-100.
6. Cai X, et al. "A review of the diagnosis and treatment of necrotizing enterocolitis". *Current Pediatric Reviews* 19.3 (2023): 285-295.
7. Group E B M. "Clinical guidelines for the diagnosis and treatment of neonatal necrotizing enterocolitis (2020)". *Zhongguo Dang dai er ke za zhi Chinese Journal of Contemporary Pediatrics* 23.1 (2021): 1-11.
8. Jones IH and Hall NJ. "Contemporary outcomes for infants with necrotizing enterocolitis-a systematic review". *Journal of Pediatric* 220 (2020): 86-92.
9. Kuik SJ, et al. "Predicting intestinal recovery after necrotizing enterocolitis in preterm infants". *Pediatric Research* 87.5 (2020): 903-909.
10. Meesters NJ, et al. "Infants operated on for necrotizing enterocolitis: towards evidence-based pain guidelines". *Neonatology* 110.3 (2016): 190-197.
11. Miller A G, et al. "High-frequency jet ventilation in neonatal and pediatric subjects: a narrative review". *Respiratory Care* 66.5 (2021): 845-856.
12. Wendy HY, et al. "Incidence and timing of presentation of necrotizing enterocolitis in preterm infants". *Pediatrics* 129.2 (2012): 298-304.
13. Van Heesewijk A E, et al. "Agreement between study designs: a systematic review comparing observational studies and randomized trials of surgical treatments for necrotizing enterocolitis". *The Journal of Maternal-Fetal and Neonatal Medicine* 33.12 (2020): 1965-1973.
14. Valpacos M, et al. "Diagnosis and management of necrotizing enterocolitis: an international survey of neonatologists and pediatric surgeons". *Neonatology* 113.2 (2018): 170-176.

Volume 13 Issue 10 October 2024

©All rights reserved by Nasibova EM., et al.