

## Severe Diabetic Ketoacidosis with an Acute Mediastinitis Complicating a Fungal Bronchopneumonia: A Pediatric Case

Salma Bellaftouh\*, Anas Erragh, Amine Afif, Karima Amenzoui, Kaoutar ElFakhr, Ouissal Aissaoui, Samira Kalouch and Abdelaziz Chlilek

*Pediatric Intensive Care Unit, Anaesthesiology-Intensive Care Medicine Department, Abderrahim El Harrouchi Hospital, CHU Ibn Rochd, Casablanca, Morocco*

**\*Corresponding Author:** Salma Bellaftouh, Pediatric Intensive Care Unit, Anaesthesiology-Intensive Care Medicine Department, Abderrahim El Harrouchi Hospital, CHU Ibn Rochd, Casablanca, Morocco.

**Received:** April 10, 2023; **Published:** April 28, 2023

### Abstract

**Introduction:** Type 1 diabetes mellitus (T1DM) is the most common metabolic disorder occurring in childhood with significant morbimortality. Uncontrolled diabetic patients are exposed to fatal hyperglycemic emergencies such as Diabetic ketoacidosis (DKA) characterized by hyperglycemia, acidosis, and ketosis. Although infections remain the predominant precipitating factors for (DKA), its association with mediastinitis is, to date, a rare situation. The objective of this study was to bring the importance of diagnosing the underlying etiological precipitants during DKA to enhance the management of this complication and reduce its mortality.

**Case Description:** The authors report during this article the case of a 7-year-old male patient, known type 1 diabetic on insulin therapy for 3 years, admitted to the pediatric intensive care unit in Abderrahim Harrouchi hospital in Casablanca for severe diabetic ketoacidosis with febrile respiratory distress and whom the non-improvement of the symptomatology leads us to diagnose an acute mediastinitis complicating its fungal bronchopneumonia.

**Discussion:** This report will review the precipitant factors, relayed by literature, associated with acute metabolic decompensation of diabetes in pediatric patients and the incidence of fungal lung infection in the diabetic population.

The authors also highlight the lack of scientific data concerning the mediastinitis complicating pulmonary infections, especially in the pediatric population.

**Conclusion:** Acute mediastinitis is a serious medical condition, commonly misdiagnosed due to the polymorphic and unspecific clinical presentation that can be related to the bronchopneumonia itself. This fatal complication being an etiological factor of a DKA considerably increases its mortality.

**Keywords:** *Diabetic Ketoacidosis; Mediastinitis; Candida Pneumonia; Case Report*

### Abbreviations

DKA: Diabetic Ketoacidosis; T1DM: Type 1 Diabetes Mellitus

### Introduction

Diabetic ketoacidosis (DKA) is one of the hyperglycemic emergencies that may occur during the progression of diabetes, it's considered as the leading cause of morbidity and mortality of T1DM in children and adolescents.

---

**Citation:** Salma Bellaftouh, *et al.* "Severe Diabetic Ketoacidosis with an Acute Mediastinitis Complicating a Fungal Bronchopneumonia: A Pediatric Case". *EC Paediatrics* 12.5 (2023): 61-66.

Currently, the diagnosis of DKA is established according to the guidelines of the international society for pediatric and adolescent diabetes (ISPAD) allowing to diagnose and define the severity of the DKA based on biochemical criteria. So, we define a severe DKA by a pH < 7,1, bicarbonate < 5 mmol/L, blood sugar > 11 mmol/L (200 mg/dL) and presence of ketones in the blood or urine [1].

Despite the pulmonary infections being one of the most common diabetes decompensating factors, the incrimination of fungal agents is clearly less frequent than bacterial ones.

On the other hand, the extension of the latter to the mediastinum remains an exceptional situation, rarely reported by literature, making the prognosis even more severe.

We believe that the present case is one of the rare cases of *Candida* bronchopneumonia that evolved to mediastinitis allowing to highlight, first, the importance of considering fungal infections in diabetic patients, then, the possibility of extension of bronchopneumonia to the mediastinum which is an often-forgotten complication.

### Case Presentation

Our patient is a 7-year-old male child, with a past medical history of uncontrolled type 1 diabetes mellitus, discovered following an inaugural diabetic ketoacidosis that occurred 3 years ago, and managed with basal-bolus insulin therapy.

The patient reported, 4 days before his admission, respiratory symptoms including dry cough, purulent rhinorrhea, and increasing dyspnea with a fever complicated 3 days later with generalized abdominal pain and 4 episodes of vomiting with the installation, few hours before admission, of a consciousness disorder.

The initial examination finds an obtunded patient with a Glasgow Coma Scale estimated at 12/15, symmetrical and reactive pupils with no other neurological impairment, at the respiratory level we reported a kussmaul breathing with polypnea at 50 cpm, pulse oximetry shows saturation at 90/ on room air, pulmonary auscultation finds diffuse bilateral rales with intercostal retraction and nasal flaring.

Initially, the patient was hemodynamically stable with a normal heart rate of 98 ppm and blood pressure of 10/06 cmHg.

The patient was febrile at 38.9, we also note the presence of oral candidiasis.

Capillary blood glucose was at 350 mg/dL with ketonuria at 3+ on urine sticks.

The arterial gasometry shows severe metabolic acidosis with a pH of 7,08, bicarbonate < 5 mmol/L with hypoxia and hypocapnia.

Laboratory investigations revealed leukocytosis with neutrophilia and lymphopenia, high levels of C-reactive protein at 228,4 mg/L, procalcitonin level at 0,5 ng/ml.

Initial chest x-ray showed a diffuse alveolar opacity extended to the entire right lung parenchyma with left basal interstitial opacities (Figure 1).

The brain CT scan had no particularities.

After conditioning, the patient initially received high-concentration mask oxygen therapy at 8 l/min, probabilistic antibiotic therapy was initiated, with rehydration, continuous insulin therapy, and glycemic monitoring.

The evolution was initially favorable with an improvement in the neurological condition of the patient and normalization of the pH, alkaline reserves, and glycemic levels. The patient was then transferred, two days later, to the pediatric department.

However, he was readmitted the next day due to the worsening of his respiratory symptoms, evolving hours later to severe acute respiratory distress syndrome (ARDS) with PaO<sub>2</sub>/FiO<sub>2</sub> ratio at 86.

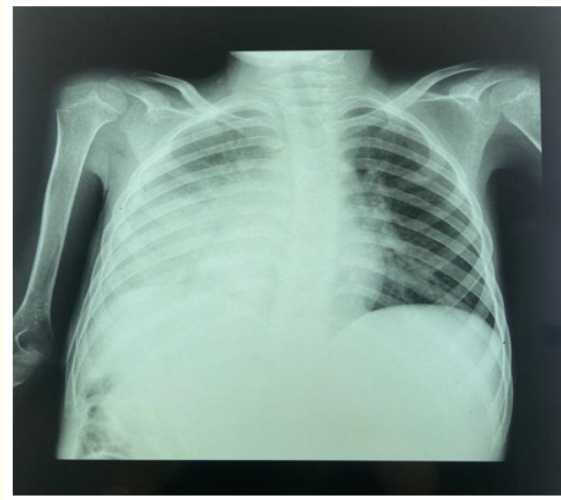


Figure 1

An orotracheal intubation had been performed, the patient was put under mechanical ventilation with continuous sedation.

The thoracic CT scan (Figure 2 and 3) objectified a bilateral parenchymal condensation foci extending to the mediastinum with diffused mediastinal fat infiltration. We noticed the presence of ground glass and bronchiectasis areas with mucoid impaction, all suggesting an infectious bronchopneumonia complicated with a mediastinitis. We also reported a diverticulum of the posterior wall of proximal portion of the left bronchial stump (Figure 4).

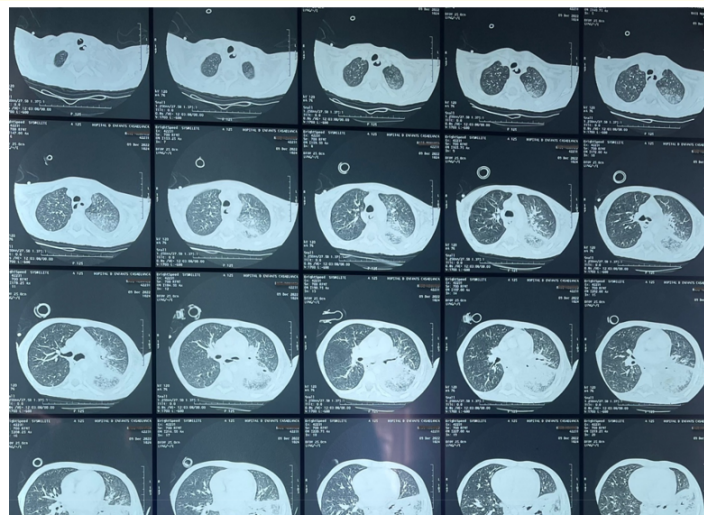


Figure 2

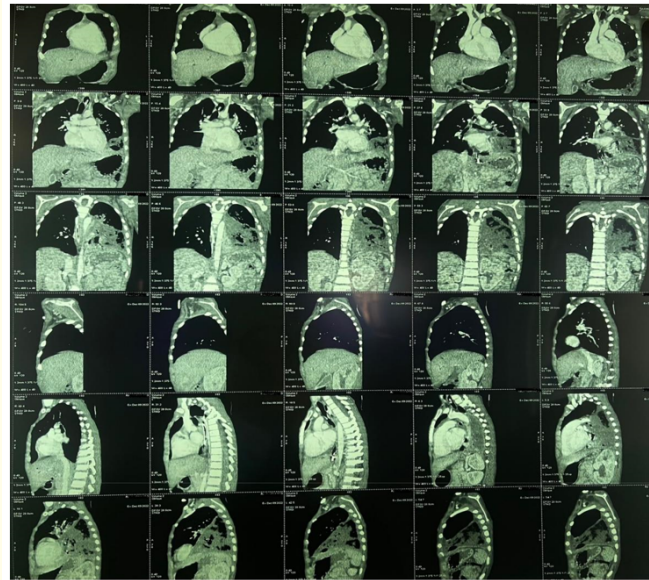


Figure 3

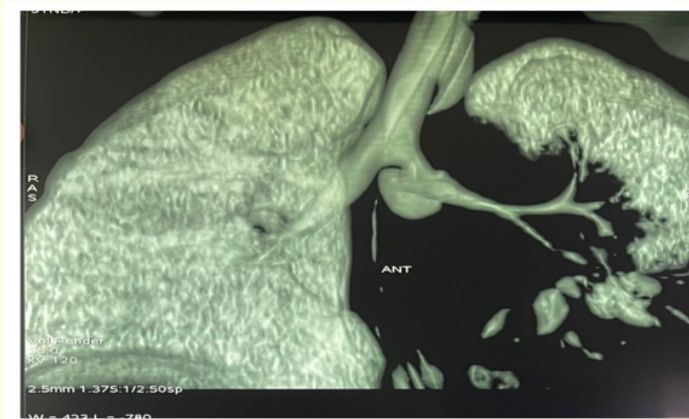

Figure 4

Two of the three distal bronchial samples performed had isolated a *Candida albicans*. Meanwhile, one of the blood fungal cultures realized isolated the same germ.

Urine culture was sterile.

Viral serologies were also performed and came back negative.

The biopsy could not be done.

The patient was then put under an antifungal treatment (voriconazole), however the evolution was followed by the progression to septic shock which evolved, days later, into multi-visceral failure leading to death.

### Discussion

Diabetic ketoacidosis (DKA) is considered as the most common hyperglycemic emergency in patients with diabetes mellitus [2]. The risk of DKA in known diabetes increased in patients with younger age (< 5 years), infection, insulin omission, lower socioeconomic status, and lower parental education [3].

Infection is considered, worldwide, as the most common precipitating factor for DKA in both children and adults (30 - 50%). Urinary tract infection and pneumonia account for the majority of the infections [2], which justifies the systematic search for an infectious site during DKA. This search is complicated by the similarity between symptoms of infection and those of DKA [4].

It's known that infections in the respiratory tract have the potential of causing respiratory failure in patients with DKA [4], these infections include pneumonia secondary to bacterial agents but also fungal ones such as pulmonary zygomycosis [5], mucormycosis [6] and candidiasis [7].

We also remind that diabetes mellitus (DM) patients have an increased susceptibility to *Candida* sp. infections which aggravates in the cases of uncontrolled hyperglycemia [8], which represent the case of our patient who presented a high HbA1c at 10% indicating a poor glycemic control due to lack of medication adherence.

*Candida* pneumonia is associated with high mortality [10], histopathological examination of tissue specimens is considered as the gold standard to diagnose these infections [11].

Unfortunately, for our case, we did not have any histologic evidence of *Candida* pneumonia, initially a bacterial infection was suspected, however the clinical evolution of the patient under antibiotic therapy and the results of the bronchial samples and blood cultures leads us to consider a fungal infection.

On the other hand, mediastinitis is known as a life-threatening condition, referring to inflammation or infection that involves the mediastinum [9].

It can be caused by various pathologies that breach the integrity of the mediastinal structures, including iatrogenic, traumatic, or infectious causes.

The common cause of mediastinitis is tracheal or esophageal rupture, however, other causes can be associated such as the spread of pulmonary infection, although it remains quite rare [9].

In our case, we didn't notice any bronchial perforation, the mediastinitis was mainly explained by the diffusion of the pneumonia.

### Conclusion

In conclusion, this case remains a unique case with several learning points, first of them is considering the spread of a pulmonary infection as a possible etiology of medical acute mediastinitis, it also bring back the importance of the precipitant factor during the management of DKA that can be represented by a fungal infection rarely considered in the first place.

### Acknowledgements

No financial or non-financial benefits have been received or will be received from any party related directly or indirectly to the subject of this article.

### Authors Contribution

The case series was written by Anass Erragh and Salma Bellaftouh. References were provided by Salma Bellaftouh, Anas Erragh, Amine Afif first reviewed by professor Kaoutar ElFakhr, approved by Professor Ouissal Aissaoui, Professor Samira Kalouch and Professor Abdelaziz Chlilek. All the authors have read and agreed to the final manuscript.

### Conflict of Interest

No conflict of interest was declared by the authors.

### Bibliography

1. Mayer-Davis EJ, *et al.* "ISPAD Clinical Practice Consensus Guidelines 2018: Definition, epidemiology, and classification of diabetes in children and adolescents". *Pediatric Diabetes* 19.27 (2018): 7-19.
2. Umpierrez GE and Kitabchi AE. "Diabetic ketoacidosis: risk factors and management strategies". *Endocrinology Treatments* 2.2 (2003): 95-108.
3. Usher-Smith JA, *et al.* "Factors associated with the presence of diabetic ketoacidosis at diagnosis of diabetes in children and young" (2017).
4. Konstantinov NK, *et al.* "Respiratory failure in diabetic ketoacidosis". *World Journal of Diabetes* 6.8 (2015): 1009-1023.
5. Hansen LA, *et al.* "Pulmonary complications in diabetes mellitus". *Mayo Clinic Proceedings* 64 (1989): 791-799.
6. Case records of the Massachusetts General Hospital. Weekly clinicopathological exercises. "Case 36-1987. A 14-year-old girl with diabetic ketoacidosis and pneumonitis with cavitation". *The New England Journal of Medicine* 317 (1987): 614-623.
7. Passi GR, *et al.* "Recovery from pulmonary mucormycosis and candidiasis in diabetic ketoacidosis". *Indian Pediatrics* 33 (1996): 1047-1050.
8. Rodrigues CF, *et al.* "*Candida* sp. Infections in Patients with Diabetes Mellitus". *Journal of Clinical Medicine* 8.1 (2019): 76.
9. Kappus S and King O. "Mediastinitis". In: Stat Pearls Treasure Island (FL): Stat Pearls Publishing (2022).
10. Mohsenifar Z, *et al.* "*Candida* pneumonia: experience with 20 patients". *Western Journal of Medicine* 131.3 (1979): 196-200.
11. Vélez L, *et al.* "Diagnostic accuracy of bronchoalveolar lavage samples in immunosuppressed patients with suspected pneumonia: analysis of a protocol". *Respiratory Medicine* 101.10 (2007): 2160-2167.

Volume 12 Issue 5 May 2023

© All rights reserved by Salma Bellaftouh., *et al.*