

Empyema Necessitans Secondary to Methicillin Resistant *Staphylococcus aureus*, a Rare Complication of Empyema

Ayaz Ur Rehman¹, Rozina Iqbal², Ariba Siddiqui³, Salman Khan⁴, Waris Ahmad⁵ and Naveed Ur Rehman Siddiqui^{6*}

¹Resident, Pediatric Medicine, Department of Pediatrics, Aga Khan University, Pakistan

²Resident, Pediatric Medicine, Department of Pediatrics, Aga Khan University, Pakistan

³Resident, Pediatric Medicine, Department of Pediatrics, Aga Khan University, Pakistan

⁴Resident, Pediatric Medicine, Department of Pediatrics, Aga Khan University, Pakistan

⁵Clinical Assistant Professor, Department of cardiothoracic surgery, Aga Khan University Hospital

⁶Assistant Professor, Pediatric medicine Critical care unit, Aga Khan University, Pakistan

***Corresponding Author:** Naveed Ur Rehman Siddiqui, Assistant Professor Pediatric medicine critical care unit, Aga Khan University, naveed.rehman@aku.edu.com.

Received: March 10, 2023; **Published:** March 25, 2023

DOI: 10.31080/ecpe.2023.12.01291

Abstract

Empyema necessitans is a rare complication of pneumonia. The most common organisms associated with empyema necessitans are *Mycobacterium tuberculosis* and *Actinomyces israelii*, and rare organisms include *Staphylococcus aureus*. This case report presents a previously healthy 1.5 year old child with empyema necessitans secondary to methicillin-resistant *Staphylococcus aureus*. This report highlights the importance of timely diagnosis and management of empyema necessitans. Our case also focuses on whether any child who presents with fever and chest wall mass and does not respond to antibiotics should be investigated properly with chest computed tomography, as they might need urgent intervention.

Keywords: *Empyema Necessitans; Methicillin Resistant Staphylococcus aureus; Empyema; Complicated Pneumonia*

Abbreviations

EN: Empyema Necessitans; IV: Intravenous; MRSA: Methicillin Resistant *Staphylococcus aureus*; CT Chest: Computed Tomography of Chest

Introduction

Empyema necessitans (EN) is the extravasation of empyema from the pleural space into the extra pleural space involving the chest wall [1]. It is more common in adult as compare to pediatric population. The incidence has decreased owing to the appropriate use of antibiotics. The most common organisms causing empyema necessitans are *Mycobacterium tuberculosis*, *Actinomyces* followed by methicillin-resistant *Staphylococcus aureus* [2]. The exact guidelines for the management of EN have not yet been established due to the limited literature on this rare complication. Treatment options include surgical interventions and antibiotics. We report the case of 1.5 year old girl with empyema necessitans associated with methicillin-resistant *S. aureus*. In this case report, we discuss timely diagnosis and management of EN.

More studies are required regarding the duration of antibiotics in empyema necessitans.

Citation: Naveed Ur Rehman Siddiqui., *et al.* "Empyema Necessitans Secondary to Methicillin Resistant *Staphylococcus aureus*, a Rare Complication of Empyema". *EC Paediatrics* 12.4 (2023): 41-46.

Case Report

1.5 year old previously healthy patient was referred from tertiary care to us with complaints of fever and cough for one week and respiratory distress for two days. The patient was initially managed by a general physician with supportive treatment, but due to worsening of symptoms, the patient visited another tertiary care hospital where she was admitted; a baseline workup was performed, and oxygen was provided with a noninvasive high-low nasal cannula along with broad-spectrum antibiotics. The workup revealed pleural effusion; therefore, the patient was referred to us for further management, Examination findings were respiratory distress with swelling and erythema on the left side of the chest wall extending inferiorly from the xiphoid process to the midclavicular line and superiorly up to the subclavicular region with decreased air entry on the left side of the chest. Laboratory workup revealed leukocytosis with white blood count of 58.9 k/ μ L with a left shift 74% neutrophils, 0.1% eosinophil's, 6.1% monocytes, 19.7% lymphocytes, hemoglobin 9.9 g/dL, platelet count 703 K/ μ L, C-reactive protein 150.94 mg/L, procalcitonin 4.01 ng/mL and blood gas with pH 7.47, partial pressure of carbon dioxide 34.80 mm Hg, partial pressure of oxy-gen 185 mm Hg, bicarbonate 24.7 meq/L and base excess 1.5 meq/L. Chest X-ray findings were consistent with complete left hemithorax whiteout with a contralateral mediastinal shift, as obvious in figure 1. Computed tomography of the chest was performed, consistent with gross left-sided pleural effusion with an enhanced pleural margin suggestive of empyema, large collection with an enhancing margin in the left lateral chest wall, and smaller fluid collection in the paramediastinal location consistent with empyema necessitans (EN), as shown in figure 1b and 1c. The patient was admitted to the pediatric intensive care unit, intubated, and continued on mechanical ventilation for increased work of breathing. The broad-spectrum antibiotics ceftriaxone and vancomycin were continued. The cardiothoracic surgery team was taken onboard, and left posterolateral thoracotomy and decortication were performed under general anesthesia with more than 500 ml purulent fluid drained and two chest tubes placed. Post-procedure patient went into SIRS, which was managed with inotropes, fluid resuscitation, and adjustment of ventilatory support. Blood culture and Pleural fluid cultures revealed Methicillin resistant staphylococcus aureus(MRSA). Pleural fluid for the AFB smear and gene-xpert were negative. An echocardiogram, which was negative for vegetation, was performed. IV ceftriaxone was discontinued, and vancomycin was switched to intravenous linezolid. Post-procedure radiography showed resolution of the pleural effusion, as shown in figure 1d and 1e. Chest tubes were removed on 7th postoperative day. The patient was treated with one week of IV antibiotics (4 days of ceftriaxone and vancomycin and add 3 days of IV linezolid) followed by oral linezolid for 4 weeks. The patient's hospital course remained uneventful, and Patient was discharged in stable condition on oral antibiotics on postoperative day 9.

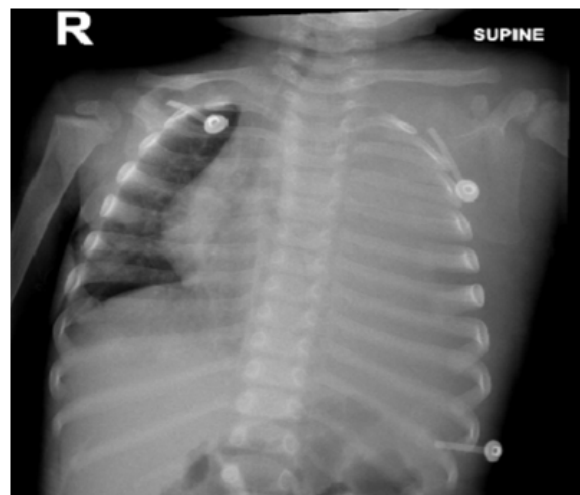

Figure 1a: Complete left hemi thorax white out with mediastinal shift suggestive of pleural effusion.

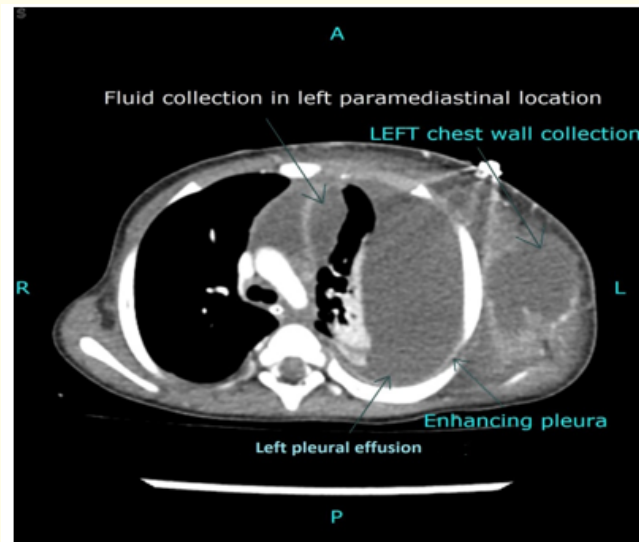


Figure 1b: Axial contrast enhanced CT chest showed gross left sided pleural effusion with enhancing pleural margin, suggesting empyema, laterally there is large collection with enhancing margin in left lateral chest wall. Medially, a smaller fluid collection is seen in paramediastinal location.

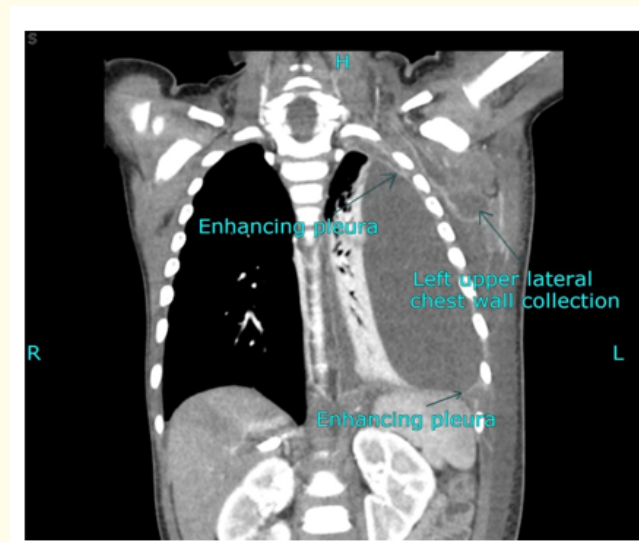


Figure 1c: Coronal contrast enhanced CT image which showed gross left sided pleural effusion with enhancing pleural margin. There is large collection with enhancing margin in left lateral chest wall.

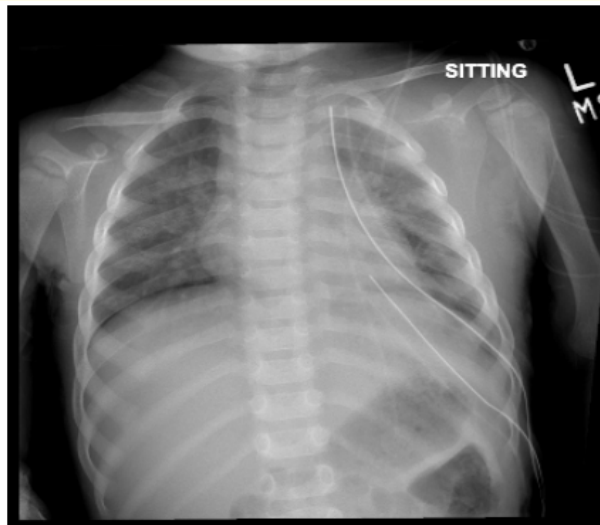


Figure 1d: Chest X ray AP view showed tracheal and mediastinal structure in normal position. Two chest tubes in placed one in apical and one in basal area. Resolution of pleural effusion in left side.

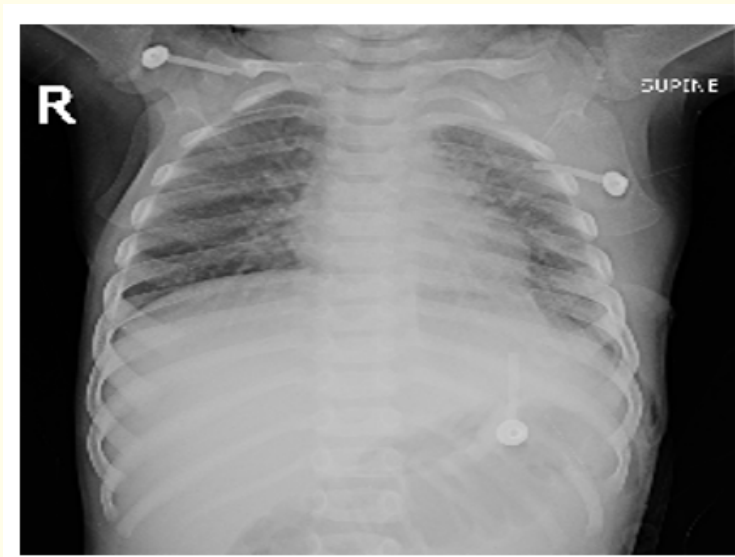


Figure 1e: Interval removal of chest tube on left sided.

Discussions

Empyema necessitans (EN) is the extravasation of empyema from the pleural cavity into the surrounding structure, involving the chest wall. It is one of the rare complications of complicated pneumonia, and the most common organisms that are usually associated with EN are *Mycobacterium tuberculosis* and *Actinomyces israelii*, whereas other rare organisms include *Staphylococcus aureus*, as in our case, *Pseudomonas*, and *Streptococcus*.

The diagnostic study of choice is contrast-enhanced chest CT, which shows the extension of fluids and involvement of the underlying structure [3,4]. Delay in diagnosis can lead to morbidity and mortality and involvement of other mediastinal structures, including the abdominal wall, paravertebral space, vertebrae, esophagus, bronchus, mediastinum, diaphragm, pericardium, flank, breast, and retro-peritoneum [5]. Treatment guidelines have not yet been established due to the limited literature available on this disease, but treatment options include both surgical drainage with decortication and antibiotic administration [6]. Further studies are required to determine the duration of antibiotic use in EN. As in our case report, we also managed empyema necessitans with surgical drainage, decortication, and antimicrobial administration. The first case of EN associated with MRSA was described by Stall, *et al.* (2005) in an 8 months old who was treated with simple chest tube placement and a total of 21 days of antibiotic treatment, which included 10 days of intravenous vancomycin [7]. Another case of EN associated with MRSA was reported by Moore, *et al.* (2006) in 3 months old infant who was treated by surgical drainage and tube thoracotomy and decortication with a total of 21 days of antibiotic treatment [8]. Preston reported 5-year-old child with MRSA who was treated with ultrasound-guided chest tube placement and 21 days of antibiotic therapy [9]. Compared to the above-mentioned case reports, we prescribed antibiotics for a total 4 weeks of duration to avoid relapse.

Conclusion

Empyema necessitans is a rare complication of pneumonia. Any child who presents in the emergency department with respiratory symptoms, chest wall mass, empyema necessitans should be considered as a differential diagnosis. Successful treatment options include surgical drainage with decortication, and a prolonged antibiotic course.

Ethical Approval and Consent to Participate

Informed Verbal consent was obtained from the parents of the patient for the case details to be used for any publication.

Consent to Publish

Written informed consent to publish was obtained from the parents of the patient for publication of this case report in a journal as well for other study purposes.

Availability of Data and Material

Case details are not publicly available because the data is patient medical records but are available from the corresponding author upon reasonable request.

Author's Contribution

RO, YT and AM were involved in the literature search of a topic, AR: Data Acquiring, Writing the manuscript and final revision of manuscript WA: final revision of manuscript NR: Concept and design, interpretation of data, final revision of manuscript. All authors have read and approved final manuscript.

Conflicts of Interest

None.

Funding Support

None.

Bibliography

1. Kono SA and Nauser TD. "Contemporary empyema necessitates". *The American Journal of Medicine* 120 (2007): 303-305.
2. Akgül AG., *et al.* "Approach to empyema necessitates". *World Journal of Surgery* 35 (2011): 981-984.
3. Gupta DK and Sharma S. "Management of empyema-Role of a surgeon". *The Journal of Indian Association Journal of Pediatric Surgery* 10 (2005): 3.
4. Chan W., *et al.* "Empyema thoracis in children: a 26-year review of the Montreal Children's Hospital experience". *Journal of Pediatric Surgery* 32 (1997): 870-872.
5. Reyes CV. "Cutaneous tumefaction in empyema necessitates". *International Journal of Dermatology* 46 (2007): 1294-1297.
6. Edaigbini SA., *et al.* "Open drainage for chronic empyema thoracis; clarifying misconceptions by report of two cases and review of literature". *Archives of International Surgery* 3 (2013): 161.
7. Stall worth J., *et al.* "Methicillin-resistant *Staphylococcus aureus* empyema necessitatis in an eight-month-old child". *Southern Medical* 98 (2005): 1130-1131.
8. Moore FO., *et al.* "Empyema necessitatis in an infant: a rare surgical disease". *The Journal of Pediatric Surgery* 41 (2006): 5-7.
9. Pugh CP. "Empyema Necessitans a Rare Complication of Methicillin-Resistant *Staphylococcus aureus* Empyema in a Child". *The Pediatric Infectious Disease Journal* 39 (2020): 256-257.

Volume 12 Issue 4 April 2023

© All rights reserved by Naveed Ur Rehman Siddiqui., *et al.*