

Ingestion of Magnets in Children: A Case Report and Review of Literature

Volkan Sarper Erikci*

Professor of Pediatric Surgery, Department of Pediatric Surgery, Izmir Faculty of Medicine, Sağlık Bilimleri University, Izmir Tepecik Health and Research Center, Izmir, Turkey

***Corresponding Author:** Volkan Sarper Erikci, Professor of Pediatric Surgery, Department of Pediatric Surgery, Izmir Faculty of Medicine, Sağlık Bilimleri University, Izmir Tepecik Health and Research Center, Izmir, Turkey.

Received: April 25, 2022; **Published:** June 28, 2022

Abstract

As a prevalent and preventible cause of gastrointestinal injury, magnet ingestion (MI) in children is a documented and sometimes fatal health hazard in children. During their development it is known that children can sometimes ingest foreign objects due to oral explorative habits they have. Although it is often stated that once foreign bodies travel beyond the esophagus, most traverse the gastrointestinal tract without complications, this concept can not be applicable in children with MI. It should be kept in mind that without appropriate management the whole gastrointestinal tract is at risk of perforation. In this article management of a 4-year-old boy with magnet ingestion is presented and it is also aimed to review management strategies in children with MI together with a brief review of epidemiology, pathophysiology under the light of relevant literature.

Keywords: Magnet Ingestion; Children; Surgical Treatment

Abbreviations

MI: Magnet Ingestion; G: Gravity

Introduction

Foreign body ingestion in children is a commonly diagnosed clinical entity. Various objects may be ingested by children while playing or exploring nearby structures. When swallowed, magnets pose a particularly serious sometimes life threatening health hazard due to their powerful attractive forces [1-4]. It has been stated that multiple magnet ingestion can produce a force of 1300 G attracting each other [5]. It is known that newly engineered magnets containing iron, boron and neodymium are 5 - 10 times stronger than plain iron magnets [6-8].

Case Report

A 4-year-old boy presented to the emergency room with a 3-day history of multiple magnet ingestion. He was hospitalized in an other medical center and followed for 3 days then after was referred to our hospital. Physical examination of the patient was normal with no abdominal pain or tenderness. Abdominal radiograph identified cylindrical shaped metal objects in the middle aspect of the abdomen, just

right of the midline (Figure 1). Repeat x-rays revealed the foreign bodies remained in the same position with no migration. Endoscopic removal of the magnets was planned. Upper gastrointestinal endoscopy was performed under general anesthesia and revealed multiple foreign objects located at prepyloric region of the stomach and the surrounding mucosa was eroded and hyperemic (Figure 2). Endoscopic removal of the foreign bodies was given a try but was not possible and a decision for explorative laparotomy was taken. At laparotomy, there were multiple magnets located at the prepyloric region of the stomach and second part of the duodenum attracting each other with the entrapment of bowel wall in between magnet pieces. After detachment of magnet pieces, perforations at prepyloric region and second part of the duodenum were detected (Figure 3). The magnets were removed and the perforation sites were repaired primarily (Figure 4). Postoperative period was uneventful and he was discharged on day 7.

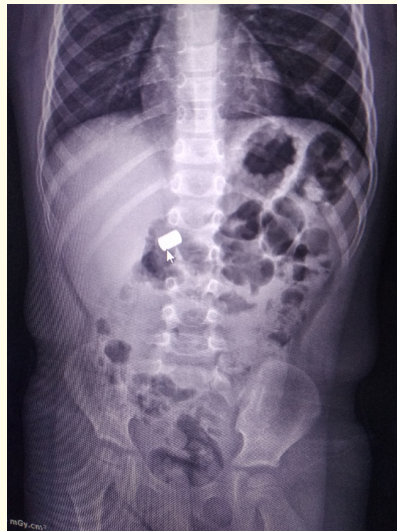

Figure 1: Abdominal radiograph showing metal objects in the abdomen, just right of the midline (Arrow: foreign object).

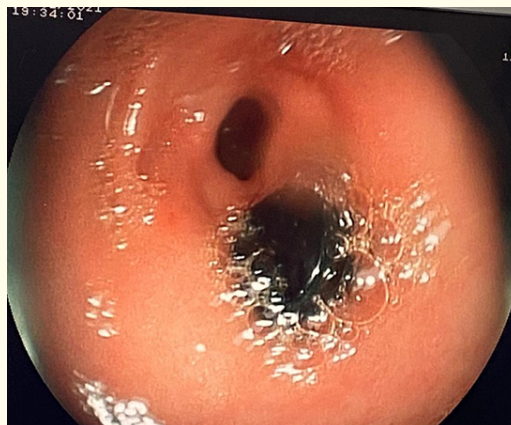

Figure 2: Endoscopic view of foreign objects at prepyloric region of the stomach.

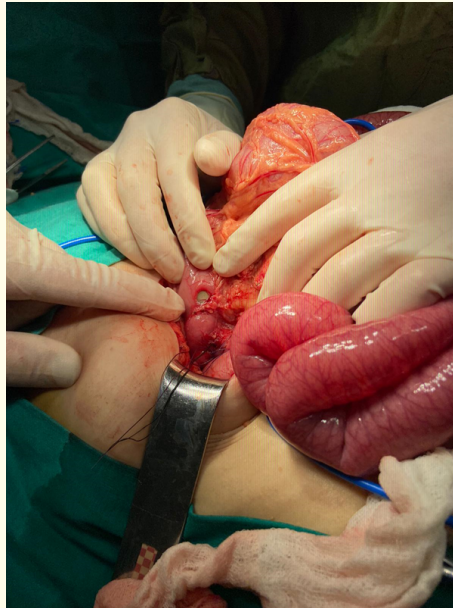


Figure 3: Laparotomy showing two separate perforations at prepyloric region of the stomach and second part of the duodenum.



Figure 4: Magnets after removal.

Discussion

Common postulated mechanism of magnet related intestinal injury is the entrapment of mucous membrane or the whole thickness of bowel wall in between magnet pieces. The multiple intestinal perforations in the presented case are suggested to occur due to this mechanism. The end results of this include necrosis due to pressure effect on bowel wall, perforation, intestinal obstruction, volvulus and fistula formation [9]. These pathophysiological mechanisms may also be observed in children with multiple magnet ingestion located in different anatomic locations in the gastrointestinal tract apart from each other which is the same in the presented case.

It has been reported that there have been more than 22,000 pediatric cases of ingested magnetic foreign bodies in the USA from 2002 to 2011 and during 3-year period and 1700 magnet related injuries have been observed between 2009 and 2011 [10]. The estimated incidence of annual pediatric emergency department visits for magnet ingestion in the USA is 3.75/100,000 children in 2011 [11]. After federal court decision of allowance of high-powered magnets to reenter the US markets in 2016, following banning of sales of high powered magnet sets in 2012 by the US Consumer Product Safety Commission, it has been reported that frequency of MI by children has increased each year with an estimated 4013 cases in 2019 alone [12]. These data clearly indicates that there is a significant increase of magnet ingestions by children.

It has been stated that proportion of older children (> 4 years) with MI is lower than that of younger children under the age of 3 years [12]. Older children have also been reported to ingest different type of magnets including magnetic piercings. Generally speaking, early childhood is linked to toddler related MI due to oral exploration similar to other foreign body ingestions like coins [13]. Time interval between the ingestion of magnet to the date of intervention varies according to literature from 1 day to 6 months but most of the cases were found to present in the first week of MI [14].

Single MI is rarely a problem and is expected to behave like other foreign bodies. It has been recommended that children with single magnet ingestion should be advised to avoid clothing with metallic buckles, zippers or studs until the magnet passes through the gastrointestinal tract [15]. On the other hand a single magnet coupled with one or more metallic objects should be regarded as multiple MI. Management of children with multiple magnet ingestion should include physical examination, serial imaging together with consultation with gastroenterologists and pediatric surgeons. After a careful history taking, the patient should be evaluated for abdominal complaints if there is a risk of MI. Abdominal pain, tenderness may not be observed in these patients and the child may seem quite healthy as in the presented case. In a previous report, strict conservative management with serial imaging daily for a few days has been recommended [14]. It has also been suggested that for ingested multiple magnets which are in the stomach endoscopic retrieval should be the first choice of removal. If it fails or there is a gap between magnets, lack of migration or clinical deterioration laparoscopic or open surgical intervention should be promptly performed. In our case our first choice of treatment was also endoscopic removal of the foreign objects but unfortunately was not possible then a decision of open surgery was taken.

Laparoscopy has the advantage of better view of the whole abdominal cavity including pelvis allowing better localization of the foreign bodies. If laparoscopic extraction is not feasible then comes the choice of surgical approach either with laparoscopy assistance or not. In a survey comprising of 354 pediatric gastroenterologists who were members of the North American Society for Pediatric Gastroenterology, Hepatology and Nutrition it was shown that of the cases requiring surgical intervention 16% resulted in bowel resection and 62% were for repair of perforation or fistula [16]. Our case is in accordance with the literature in that primary closure was found to be feasible with no morbidity.

Although propulsive force of peristalsis may result in detachment of the magnetic objects from each other it is paramount to avoid complications like intestinal necrosis, perforation or fistulae [14]. Usual surgical management is palpating the foreign object during

explorative laparotomy and retrieval of magnet by enterotomy and primary closure with absorbable suture materials if there is not full-thickness perforation. In cases with perforation it is mandatory to extract foreign body first and then after mechanical cleaning of the abdominal cavity, simple closure of perforation site is all that is needed.

Conclusion

In conclusion, accidental ingestion of magnetic foreign bodies is a common dangerous, potentially fatal health hazard in children. Due to availability of small magnets sold in magnet sets, there is an increasing number of cases with MI and first liners of medical providers need to be aware of the risk of this clinical entity. Caregivers of children with ingestion of magnets and their families should be informed about this unwanted entity. Besides legislative preventive measures and regulatory actions are needed to protect children. In children with magnet ingestion prompt evaluation, imaging and consultation with gastroenterology and pediatric surgery is highly recommended.

Conflicts of Interest

The author certifies that he has no affiliations with or involvement in any organization or entity with any financial interest, or non-financial interest in the subject matter or materials discussed in this manuscript.

Funding Support

During this study, no financial or spiritual support was received neither from any pharmaceutical company that has a direct connection with the research subject, nor from a company that provides or produces medical instruments and materials which may negatively affect the evaluation process of this study.

Author Contribution to the Manuscript

Idea/concept, design, control and processing, analysis and/or interpretation, literature review, writing the article, critical review, references and materials by Volkan Sarper Erikci.

Bibliography

1. Kadaba L. The attraction of Buckyballs (2020).
2. North American Society for Pediatric Gastroenterology, Hepatology and Nutrition. Warning labels ineffective at preventing high-powered magnet ingestions (2020).
3. Consumer Product Safety Commission. Federal Register (2020).
4. Agbo C., *et al.* "Magnet-related injury rates in children: a single hospital experience". *Journal of Pediatric Gastroenterology and Nutrition* 57 (2013): 14-17.
5. Honzumi M., *et al.* "An intestinal fistula in a 3 year old child caused by ingestion of magnets; report of a case". *Surgery Today* 25 (1995): 253-552.
6. Martin A. "For buckyballs toys, child safety is a growing issue". *New York Times* (2012).
7. United States Consumer Product Safety Commission. CPSC Sues Star Networks USA over Hazardous, High-powered Magnet Balls and Cubes (2012).

8. United States Consumer Product Safety Commission. Child's Death Prompts Replacement Program of Magnet Building Sets. News from CPSC (2006).
9. Schroepfer E., *et al.* "Small bowel perforation caused by magnetic toys". *Zentralblatt fur Chirurgie* 135.3 (2010): 270-272.
10. Silverman JA., *et al.* "Increase in pediatric magnet-related foreign bodies requiring emergency care". *Annals of Emergency Medicine* 62 (2013): 604-608.
11. Abbas MI., *et al.* "Magnet ingestions in children presenting to US emergency departments, 2002-2011". *Journal of Pediatric Gastroenterology and Nutrition* 57 (2013): 123-125.
12. Reeves PT., *et al.* "Trends of magnet ingestion in children, and ironic attraction". *Journal of Pediatric Gastroenterology and Nutrition* 66 (2018): e116-e121.
13. Garvey C Play and Cambridge MA. Harvard University Press (1990).
14. Naji H., *et al.* "Bowel injuries caused by ingestion of multiple magnets in children: a growing hazard". *Pediatric Surgery International* 28 (2012): 367-374.
15. Brown JC., *et al.* "Pediatric magnet ingestions: the dark side of the force". *The American Journal of Surgery* 207 (2014): 754-759.
16. North American Society for Pediatric Gastroenterology, Hepatology and Nutrition (NASPGHAN). Warning labels ineffective at preventing high-powered magnet ingestions: NASPGHAN Releases New Survey Findings. Flourtown, PA: Naspghan (2012).

Volume 11 Issue 7 July 2022

© All rights reserved by Volkan Sarper Erikci.