

“Postec-Inox Shidi/Hayek” Device for Safety in Posthetomy Procedures

Rasheed Abayomi Olusegun Shidi^{1*}, Abdul Kader El-Hayek² and Lisieux Eyer de Jesus³

¹Medical Doctor, Pediatrics and Pediatric Surgery, Researcher, CEO Clinica Medica 2 DE Julho at Rua Dois de Julho, Ribeirão Preto, SP and Pediatrician at Santa Marcelina Health Center, Brazil

²Medical Doctor, General Surgeon, CEO Hospital MogiMater at Rua Marechal Deodoro 83, Mogi Das Cruzes, SP, Brazil

³Medical Doctor, Pediatric and Urology Pediatrics, Editor of Revista CIPERJ editor_revista@ciperj.org, Titular Membership of CIPE and CBC, Member of the Technical Chamber of Pediatric Surgery - CREMERJ, Vice-president of CIPERJ, Universidade Federal Fluminense (UFF), Hospital Federal dos Servidores do Estado do Rio de Janeiro (HFSE), Brazil

***Corresponding Author:** Rasheed Abayomi Olusegun Shidi, Medical Doctor, Pediatrics and Pediatric Surgery, Researcher, CEO Clinica Medica 2 DE Julho at Rua Dois de Julho, Ribeirão Preto, SP and Pediatrician at Santa Marcelina Health Center, Brazil.

Received: January 20, 2021; **Published:** May 29, 2021

Abstract

Most early problems with the surgical techniques in circumcision dealt with hemorrhage, infection and injury to glands especially in newborns. Since 2010, after the implementation of POSTEC-INOX device, more than 20 patients both children below 2 months age and adults were all operated on under local anesthetic by Dorsal Pudendal nerve of penis block. Children above 2 months and teenage were all operated on under general anesthetic by Fentanyl at MogiMater Hospital. Patients were discharged after first urination, immediately after surgery the same day, and maintained with anti-inflammatory medication (acetylsalicylic acid 100 mg/kg for 5 days). All procedures lasted less than 30 minutes and patients stay nothing more than 2 hours in health center premises, to return for check-up appointment after 1 week without any complaint of bleeding and with good cicatrize of the preputial coronal suture.

Keywords: Postec-Inox Device; Posthetomy Procedures; Dorsal Pudendal Nerve

Introduction

Throughout the centuries, various surgical techniques and instruments have been used, from flint knives described in the bible to double-edged knives, known as “izmels”, to flat shields to protect the glands [1]. Nothing is new after the holy books of monotheism religions (Al-quran, torah and bible), so our device is not new but part of evolution and transformation to safety procedure. Most early problems with the surgical techniques in circumcision dealt with hemorrhage, infection and injury to glands, especially in newborns. A variety of clamp methods were devised to decrease these complications. The development of the gomco clamp in the 1930s and the plastbell in the 1960s helped to make the neonatal technique safer. These devices are now the most commonly used in newborn circumcision including our newly improved device ‘Postec-Inox shid/hayek’.

Surgical technical procedure of Postec-Inox

The baby is identified and restrained. The penis is prepared with an antiseptic solution.

An optional local anesthetic block may be administered.

The location of the coronal sulcus on the shaft skin is marked with a surgical marking pen.

The preputial ring is delated with a hemostat and the urethral meatus definitely identified.

The foreskin is grasped in 0.5 cm to 1cm bites with straight hemostats at 10 and 2 o'clock.

The foreskin is teased off the dorsal surface of the glands with a hemostat or a flexible probe.

The dorsal foreskin is clamped one third of the distance to the corona in the midline for 5 to 10 seconds.

The crushed area of the foreskin is divided with straight blunt-tipped scissors.

The foreskin is bluntly freed off the entire glans with a flexible probe and completely retracted to definitely identify the coronal sulcus.

The correct size 'Postec-Inox' is selected. The bottom edge of the ring should completely cover the corona.

The ring should slightly distend the foreskin when the foreskin is drawn over the 'Postec-Inox' and glands.

The foreskin is pulled over the 'Postec-Inox' until the previously marked level of the coronal sulcus lies over the groove in the 'Postec-Inox'.

A non-absorbable 2/0 (cotton) suture thread is tied as tight as possible over the groove in the 'Potec-Inox' using a surgeon's knot for the first throw.

The foreskin is excised with just past the outermost groove, taking care not to injure the glands.

A continuous or interrupted absorbable 4/0, 5/0 or 6/0 (catgut) sutures as suitable are placed in the quadrant.

Results and Conclusion

Since 2010, after the implementation of Postec-Inox device, more than 20 patients both children below 2 months age and adults were all operated on under local anesthetic by Dorsal Pudendal nerve of penis block. Children above 2 months and teenage were all operated on under general anesthetic by Fentanyl at MogiMater Hospital. Patients were discharged after first urination, immediately after surgery the same day, and maintained with anti-inflammatory medication (acetylsalicylic acid 100 mg/kg for 5 days). All procedures lasted less than 30 minutes and patients stay nothing more than 2 hours in health center premises, to return for check-up appointment after 1 week without any complaint of bleeding and with good cicatrize of the preputial coronal suture [1-3].

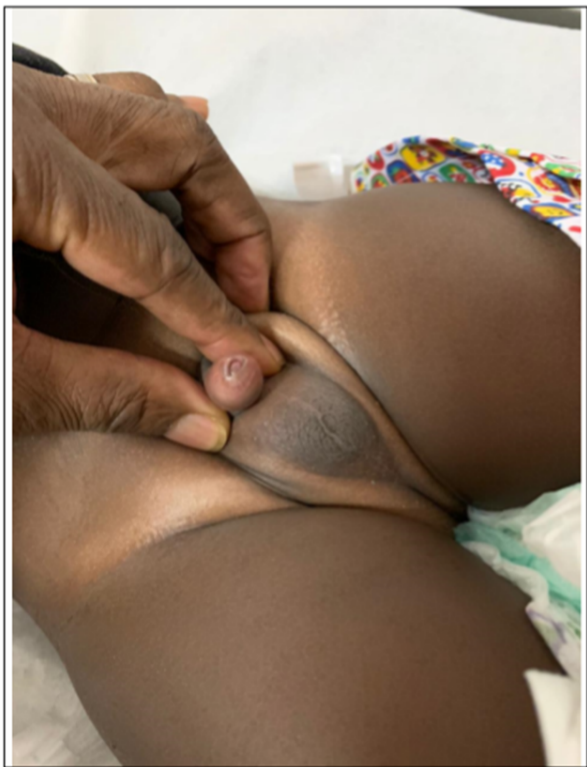


Figure 1: Showing MAOB at 1yr+ 10 months age, Pre-operation picture of penis with preputial adhesion and urethral orifice.

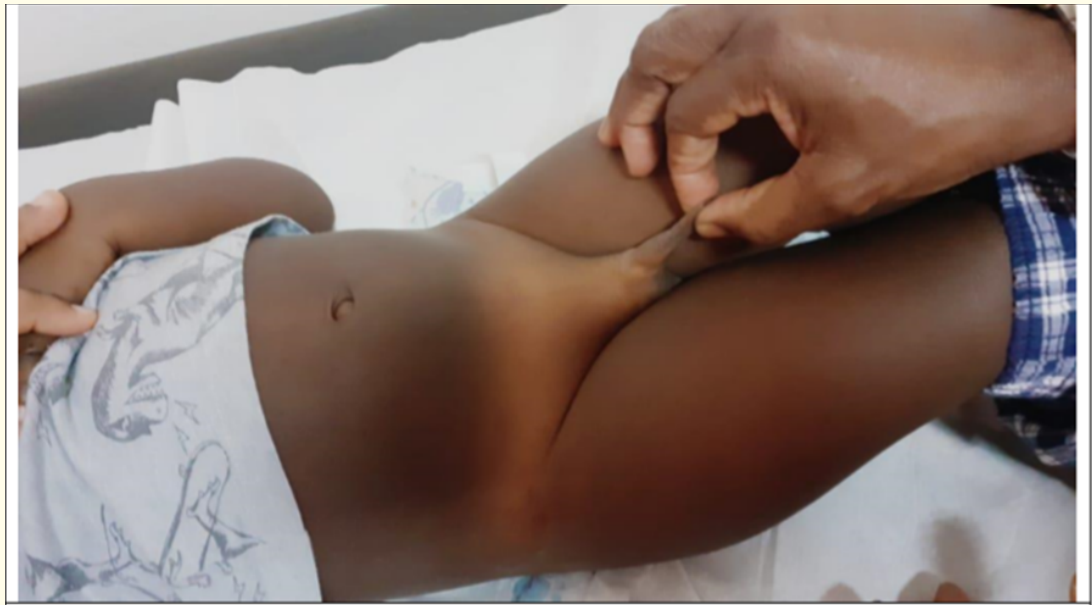

Figure 2: Showing MAOB at 1yr+ 10 months age, pre-operation picture of penis with prepuce stretched to cover urethral orifice.

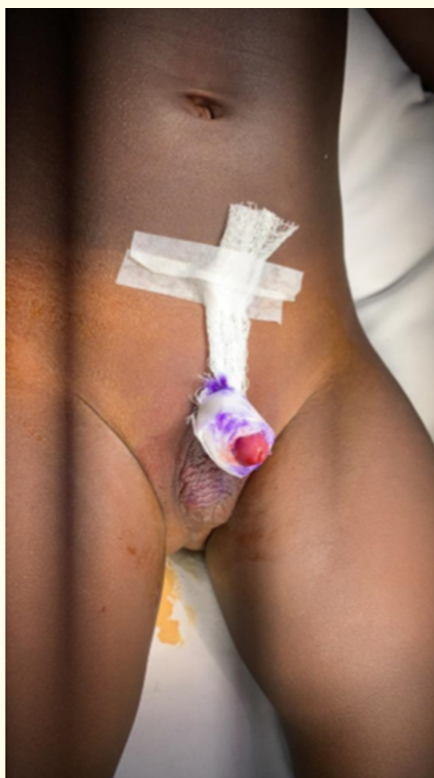

Figure 3: Showing at MAOB 1yr+ 10 months age, after Posthetomy procedure with “Postec-Inox” device at immediate Post-operation picture of penis dressed with Gentian Violet 1%, Micropore and exposed gland with Urethral orifice.

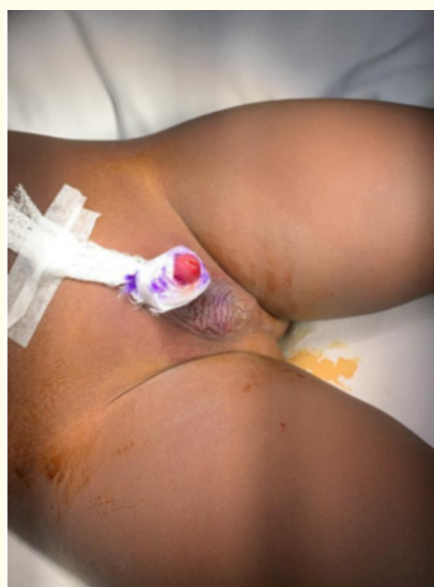

Figure 4: Showing MAOB at 1yr+ 10 months age, after Posthetomy procedure with “Postec-Inox” device at immediate Post-operation picture of penis dressed with Gentian Violet 1%, Micropore and exposed gland with Urethral orifice.

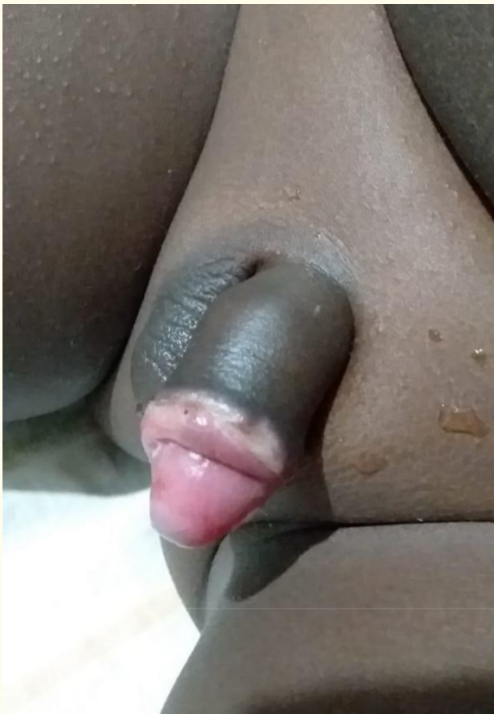

Figure 5: Showing MAOB at 1yr+ 10 months age, 1 week post-operation picture of penis and gland after Posthetomy procedure with “Postec-Inox” device.

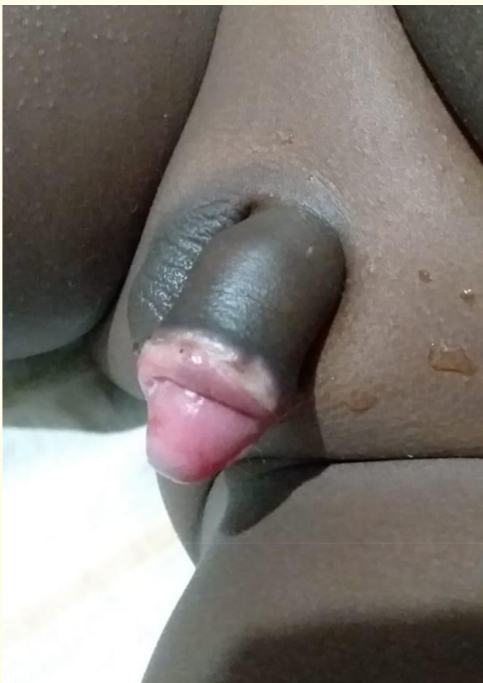

Figure 6: Showing MAOB at 1yr+ 10 months age, 1 week post-operation picture of penis and gland after posthetomy procedure with “Postec-Inox” device.



Figure 7: Showing MAOB at 1yr+ 10 months age, 2 weeks post-operation picture of penis and gland after Posthetomy procedure with “Postec-Inox” device.



Figure 8: Showing MAOB at 1yr+ 10 months age, 2 weeks post-operation picture of penis and gland after posthetomy procedure with “Postec-Inox” device.



Figure 9: Various sizes of Postec-Inox from 0,3 cm to 0,6 cm wide internal rings in horizontal view.




Figure 10: Below is larger Postec-Inox of 0,9 cm wide internal ring in horizontal view.



Figure 11: *Postec-Inox of 0,5 cm wide internal ring in horizontal view.*



Figure 12: *Postec-Inox of various sizes from 0,3 cm to 0,6 cm in vertical view.*

Bibliography

1. Grossman E and Posner NA. “Surgical circumcision of neonate; A history of its development”. *Obstetrics and Gynecology* 58 (1981): 241-246.
2. Anderson GF. “Circumcision”. *Pediatric Annals* 18 (1989): 205-210.
3. Hinman Jr F. “Atlas of Urologic Surgery”. WB Saunders, Philadelphia (1989): 77-81.

Volume 10 Issue 6 June 2021

© All rights reserved by Rasheed Abayomi Olusegun Shidi.