

Laparoscopic Lateral Ureterocalicostomy for Complicated Ureteropelvic Junction Obstruction in a Girl

Burgos L*, Ortiz R, Fernández B, Blanco L, Parente A and Angulo JM

Gregorio Marañón University Hospital, St/ O'Donnell, Madrid, Spain

***Corresponding Author:** Burgos L, Gregorio Marañón University Hospital, St/ O'Donnell, Madrid, Spain.

Received: February 25, 2021; **Published:** March 31, 2021

Abstract

Background: Terminal ureterocalicostomy has been performed as the first choice of treatment for ureteropelvic junction obstruction (UPJO) in patients with anatomic anomalies or as an alternative in case of recurrent UPJO. We report a pediatric case of laparoscopic lateral ureterocalicostomy as a surgical alternative in patients with complicated UPJO.

Case Presentation: A 13 year-old girl came to the emergency department due to abdominal and left lumbar pain. Ultrasound showed very dilated left pelvicaliceal structures and renogram proved an obstructive elimination curve. She underwent endoscopic balloon dilatation with double J placement without complications. Once double J was removed, clinical and ultrasound worsening occurred. Computed tomography demonstrated an intrarenal pelvis and very dilated lower pole calyx with parenchyma thinning. Laparoscopic lateral ureterocalicostomy was performed and postoperative course was uneventful. Two years later the patient remains asymptomatic and renogram shows good elimination curve and renal function preservation.

Conclusion: Laparoscopic lateral ureterocalicostomy is a safe and effective alternative in hampered UPJO. Preoperative exhaustive study is necessary in such cases to determine the surgical approach.

Keywords: *Laparoscopic; Lateral Anastomosis; Ureteropelvic Junction Obstruction; Pediatric; Ureterocalicostomy*

Background

Gold-standard treatment for ureteropelvic junction obstruction (UPJO) is Anderson-Hynes pyeloplasty. During the last decades the improvement in minimally invasive techniques has made possible laparoscopic pyeloplasty and retrograde endoscopic balloon dilatation with similar results, even for the treatment of recurrent UPJO.

However, there are patients in which a different procedure may be necessary to achieve the obstruction resolution, due to anatomic anomalies or persistent recurrences.

Open ureterocalicostomy was first described in 1947 as a treatment option in case of giant hydronephrosis, intrarenal pelvis or horse-shoe kidney [1]. Thereafter, several cases of terminal ureterocalicostomy in children, by open access or laparoscopically-assisted, have been published [1-4]. However, as far as we are concerned, this is the first reported case of a laparoscopic lateral ureterocalicostomy in a girl, for the treatment of recurrent UPJO.

Case Presentation

A 13 year-old girl came to the emergency department due to abdominal and left lumbar pain. She had no previous studies and refers worsening lumbar pain during the last 5 days. Ultrasound showed very dilated left pelvicaliceal structures with parenchyma thinning and no ureteral dilatation (Image 1).

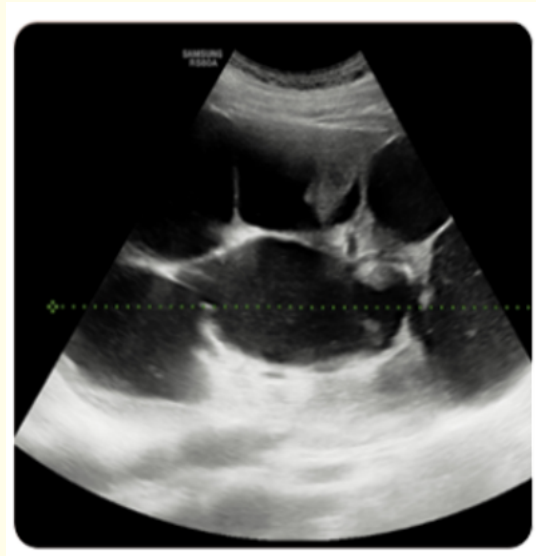

Image 1: Ultrasound showed very dilated left pelvicaliceal structures with parenchyma thinning and no ureteral dilatation.

Renogram with MAG-3 proved 40% differential renal function and obstructive elimination curve with retention of contrast in all caliceal structures. An angio-magnetic resonance (MR) was performed to rule out the presence of a polar vessel, verifying previous findings (Image 2).

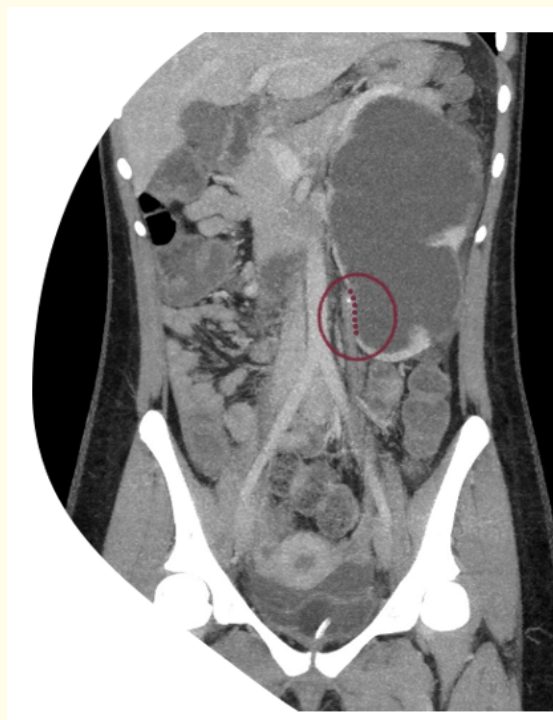

Image 2: Angio-magnetic resonance (MR) was performed to rule out the presence of a polar vessel, verifying previous findings.

According to our protocol, she underwent endoscopic retrograde balloon dilatation (6 Fr balloon) with double J placement without complications. Double J was removed 4 weeks later and the patient was discharged with good clinical condition. Short-term follow-up was fairly fine, the patient was asymptomatic except by some sporadic self-limited flank pain and ultrasound showed progressive dilatation resolution.

Nevertheless the patient came back to the emergency room 4 months later, referring severe lumbar pain, vomits and clinical deterioration. Ultrasound proved dilatation worsening and computed tomography demonstrated an intrarenal pelvis and very dilated lower pole calyx with severe parenchyma thinning.

A percutaneous nephrostomy was placed and after the patient recovery, a laparoscopic lateral ureterocalicostomy was performed. With the patient in right lateral flank position, a transperitoneal three-ports access was used: one 10 mm umbilical and two 5-mm in left iliac fosa and suprapubic position (Image 3). The left colon was dissected and medially displaced, getting access to the lower renal pole. Careful dissection was achieved, identifying the ureter that is widely dissected. Then the lower renal calyx is exposed and both structures were approximated with an extracorporeal stitch. The thinning portion of the lower pole calyx is identified and incised and a longitudinal incision is done in the proximal ureter. Afterwards a tension free anastomosis between both structures was done using a 4-0 unidirectional barbed suture. A double J catheter was left in place for 4 weeks and it was eventually removed by cystoscopy without incidences. Operation time was 196 minutes and hospital stay was 48 hours. Postoperative course was uneventful and 2 years later the patient remains asymptomatic. Ultrasound follow-up proved dilatation resolution and MAG-3 renogram shows good elimination curve and renal function preservation.

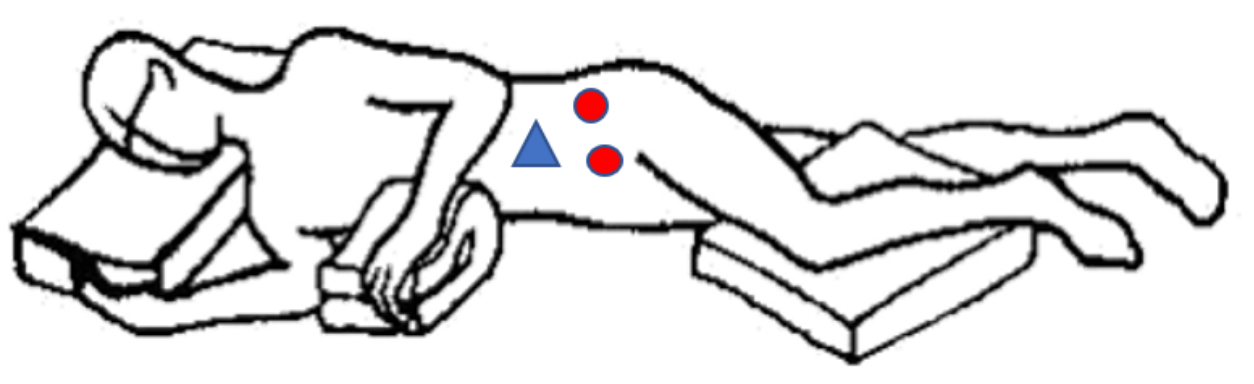


Image 3: The patient is placed in right lateral flank position and a transperitoneal three-ports access was used: one 10 mm umbilical and two 5-mm in left iliac fosa and suprapubic position.

Discussion and Conclusion

Terminal ureterocalicostomy was initially described as an alternative surgical approach for patients with giant hydronephrosis, intrarenal pelvis or horseshoe kidney. It has been widely used in adult patients and during last decades, several authors had published their experience with its use in pediatric patients. Radford, *et al.* reported a series of 13 children in which a terminal ureterocalicostomy was performed by open approach or laparoscopically assisted [4]. It was a primary procedure in 8 of them, due to anatomic anomalies such as horseshoe kidney, intrarenal pelvis, high insertion of the ureter or gross crossing vessels. They considered that in those situations con-

ventional pyeloplasty may not ensure adequate drainage. Other authors such as Mesrobian and Kelalis reported their experience with this technique for the treatment of recurrent UPJO, as a salvage procedure, with similar success rates [5].

Ureterocalicostomy technique classically involves ureter disconnection from the renal pelvis and a terminal anastomosis between the ureter and the lower pole calyx. In this technique, in order to avoid the risk of anastomotic stricture, the renal parenchyma surrounding the anastomosis must be excised, as it has been recorded by several groups [5-8].

In our patient, hydronephrosis was very severe and the thinning of the cortex in the lower pole was patent, therefore parenchyma excision was not necessary and lateral anastomosis was feasible.

Bleeding from the incised parenchyma has also been reported. In those patients in whom parenchyma thinning is not so evident, hilar occlusion is recommended during the cortex incision [9]. Neither of these 2 complications were presented in our patient and vascular occlusion was not necessary.

However, it is important to ensure continuity of the urothelial lining of the ureteral lumen and the calyx and to perform a tension free anastomosis, after careful dissection of both structures. In our patient, lower calyx was so dilated and adjacent to the ureter that lateral anastomosis became our choice, minimizing the need of dissection and ensuring no tension in the suture.

During postoperative follow-up, symptoms disappeared and ultrasound proved a patent anastomosis and dilatation improvement with no significant worsening of split renal function.

In conclusion, laparoscopic lateral ureterocalicostomy is a safe and effective alternative in hampered UPJO. Preoperative exhaustive study is necessary in such cases to determine the surgical approach.

Bibliography

1. Romao RL, *et al.* "Failed pyeloplasty in children: revisiting the unknown". *Urology* 82.5 (2013): 1145-1147.
2. Nishimura Y, *et al.* "Laparoscopic ureterocalicostomy for ureteropelvic junction obstruction in a 10-year-old female patient: a case report". *BMC Research Notes* 10.1 (2017): 247.
3. Agarwal MM, *et al.* "Laparoscopic ureterocalicostomy for salvage of giant hydronephrotic kidney: initial experience". *Urology* 70.3 (2007): 590e7-10.
4. Radford AR, *et al.* "Ureterocalicostomy in children: 12 years experience in a single centre". *BJU International* 108.3 (2011): 434-438.
5. Mesrobian HG and Kelalis PP. "Ureterocalicostomy: indications and results in 21 patients". *The Journal of Urology* 142.5 (1989): 1285-1287.
6. Mollard P and Braun P. "Primary ureterocalicostomy for severe hydronephrosis in children". *Journal of Pediatric Surgery* 15.1 (1980): 87-91.
7. Hawthorne NJ, *et al.* "Ureterocalicostomy: an alternative to nephrectomy". *The Journal of Urology* 115.5 (1976): 583-586.
8. Jameson SG, *et al.* "Ureterocalicostomy: a new surgical procedure for correction of ureteropelvic stricture associated with an intrarenal pelvis". *The Journal of Urology* 77.2 (1957): 135-143.
9. Gill IS, *et al.* "Laparoscopic ureterocalicostomy: initial experience". *The Journal of Urology* 171.3 (2004): 1227-30.

Volume 10 Issue 4 April 2021

©All rights reserved by Burgos L., *et al.*