

Handlebar Hernia in Children-A Case Report

Benmerzoug Hiba*

Mohamed Boudiaf Hospital, Oum El Bouaghi, Faculty of Medicine, Constantine 3 University, Algeria

***Corresponding Author:** Benmerzoug Hiba, Mohamed Boudiaf Hospital, Oum El Bouaghi, Faculty of Medicine, Constantine 3 University, Algeria.

Received: October 01, 2020; **Published:** October 19, 2020

Abstract

Traumatic abdominal wall hernias are rare in children. They are typically caused by bicycle handlebar trauma. We report a case of a right pararectal posttraumatic hernia.

A 10-year-old boy hospitalized in emergency for an isolated handlebar abdominal trauma.

Clinical condition and hemodynamic constants were stable. Abdominal examination shows a 10 cm painful right flank tumefaction. CT scan shows an external oblique muscle defect of 6 cm with intestinal herniation through, with a muscle contusion. The patient was operated 48 hours later, with hernia repair.

Handlebar hernia is a rare traumatic abdominal wall in children. All children who have this type of trauma should be explored for immediate or delayed hernia.

Keywords: *Handlebar Hernia; CT Scan; Abdominal Trauma*

Introduction

Handlebar hernia is a localized abdominal-wall hernia caused by a handlebar injury, which is too blunt to penetrate the skin but strong enough to disrupt muscular and fascial layers. Fewer than ten pediatric cases have been reported in the literature [1].

We report a case of a 9-year-old boy with a handlebar hernia where there was disruption of the entire abdominal wall, but the skin and intra-abdominal organs remained completely intact.

Case Report

A ten-year-old boy, without relevant antecedents, fell off his bicycle and hit the handlebar with the lower right quadrant of the abdomen. Physical examination revealed contusion and circular bruising, and 10 cm subcutaneous mass while standing up. And a facial defect palpable at the same site.

CT scan demonstrated an external oblique muscle defect of 6 cm with intestinal herniation through with a muscle contusion (Figure 1).

At surgery, a midline incision under umbilical revealed an 8 cm disruption of the fascial muscle layers, and peritoneum along the order of the rectus and external oblique muscles (Figure 2). Inspection showed no intestinal injury or blood collection in the peritoneal cavity. The abdominal wall was closed in layers.

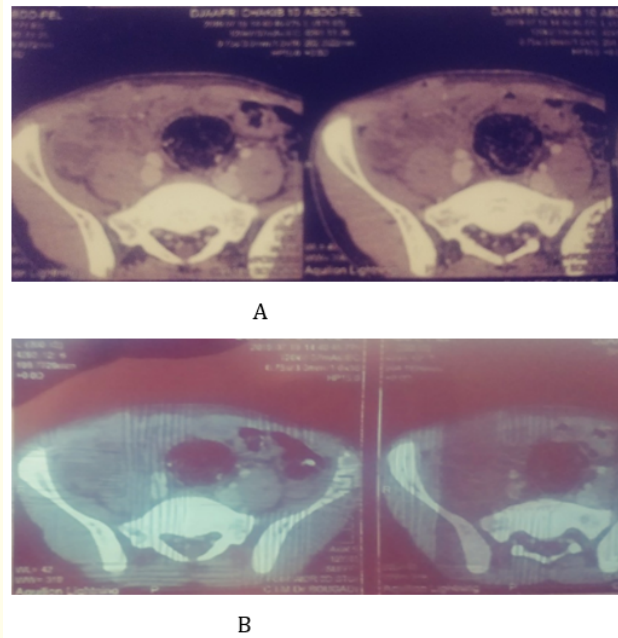


Figure 1: A and B, Abdominal CT demonstrating protrusion of bowel through defect in the abdominal wall into the subcutaneous space.

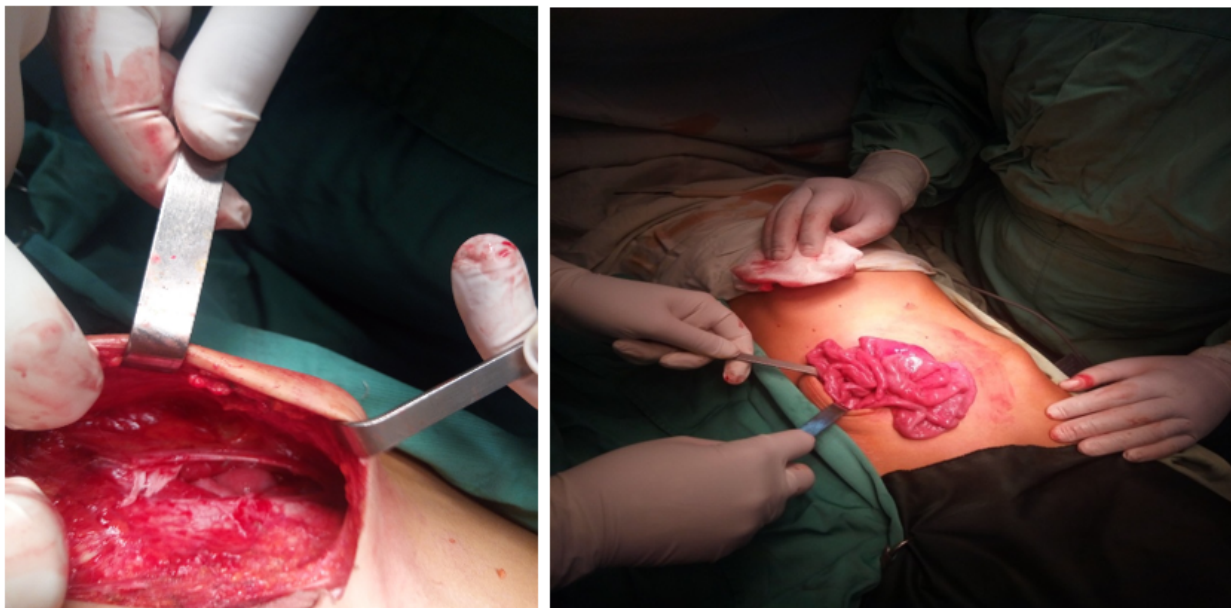


Figure 2: Disruption of all fascial and muscle layers and peritoneum along border of rectus and external oblique muscle revealed after skin-crease incision.

Discussion

The term of handlebar hernia was coined by Dimyan, *et al.* in 1980 [6]. Traumatic abdominal wall hernias are generally categorized into two major types: a smaller defect caused by localized trauma such as that from a bicycle handlebar and a larger defect caused by high energy transfers such as a motor-vehicle crash or a fall from a height.

The first case, due to the direct impact against the handle of a wheelbarrow, was reported by Selby in 1906 [2]. The first case due to the impact against the handlebars of a bicycle was reported by McWhorer in 1939 [3]. In the review of the English literature we have found 20 clear cases of handlebar hernia 12 of these in children [4]. Here we report a new case of handlebar hernia in children.

Ten pediatric cases of the localized traumatic abdominal wall hernia have been reported in the literature; seven of them were handlebar hernia. The ages ranged from 5 to 14 years; all seven were boys. An associated injury, a twisted wrist, was noted in one case; however, no major intra-abdominal injury was reported. In two cases only a minor hematoma of the omentum or mesocolon was found. The overlying skin was intact in three cases, an abrasion was noted in two, and a contusion and handlebar imprint were noted in one each.

Traumatic abdominal wall hernia is produced by the sudden application of blunt force that is insufficient to penetrate the skin but strong enough to disrupt the muscle and fascia [1,4,5]. This is possible because the skin is more elastic than the other layers of the abdominal wall. The force of impact creates a compression injury while intra-abdominal pressure is simultaneously elevated from bracing impact.

Laparoscopy has been used to identify injuries before conversion to open repair [5].

Laparoscopic repair has been described in adults, but no previous reports describing repair in children. All reported cases of handlebar hernia have been treated surgically except one case being successfully treated conservatively [7] in this case a cotton corset was used for abdominal compression. A CT scan 3 months later confirmed complete healing of the musculature. Although the diagnosis of handlebar hernia may be made by careful abdominal examination, CT scan is safe and can be very helpful [1].

Hernia recurrence is a potential issue with primary repair because the injured muscle and fascia may have associated ischemic damage. In our case the postoperative course was uneventful.

Conclusion

Although handlebar hernia is a rare entity, all children who have suffered abdominal trauma should be evaluated, not only for intra-abdominal lesions, but also for immediate or delayed onset hernia.

Diagnosis is generally reached during physical examination; however, CT scan may be useful, not only for detecting intra-abdominal lesions but also for detecting the hernia.

Bibliography

1. Yan J., *et al.* "Traumatic abdominal wall hernia-a case report and literature review". *Journal of Pediatric Surgery* 46.8 (2011): 1642-1645.
2. Selby CD. "Direct abdominal hernia of traumatic". *The Journal of the American Medical Association* (1906): 71485.
3. Mc Whoher. "GL. inguinal hernia due o direc raumas echnique of operation". *The American Journal of Surgery* 45 (1939): 316.
4. Iinuma Y., *et al.* "A case of a traumatic abdominal wall hernia that could not be identified until exploratory laparoscopy was performed". *Pediatric Surgery International* 21.1 (2005): 54-57.

5. Rowell EE and Chin AC. "Laparoscopic repair of traumatic abdominal wall hernia from handlebar injury". *Journal of Pediatric Surgery* 46.5 (2011): e9-e12.
6. Diman W., *et al.* "Handlebar hernia". *Journal of Trauma* 198.20: 812-813.
7. Litton K., *et al.* "Conservative management of a traumatic abdominal wall hernia after a bicycle handlebar injury (case report and literature review)". *Journal of Pediatric Surgery* 43.4 (2008): e3-e32.

Volume 9 Issue 11 November 2020

© All rights reserved by Benmerzoug Hiba.