

## Diffuse Lipoblastoma of Forearm in a Child. A Diagnostic Dilemma

Satish Kumar KV<sup>1\*</sup>, Naveen Thomas<sup>2</sup>, Nithya Manayath<sup>3</sup>, Bindu Vanguri<sup>4</sup>, Asha Thomas<sup>5</sup>, Balachandra<sup>6</sup> and Ravinder Reddy<sup>7</sup>

<sup>1</sup>Consultant Pediatric Surgeon, Department of Pediatric Surgery, Baptist Hospital, Bangalore, India

<sup>2</sup>CEO and Consultant Pediatric Surgeon, Baptist Hospital, Bangalore, India

<sup>3</sup>Surgical Oncologist, Department of General Surgery, Baptist Hospital, Bangalore, India

<sup>4</sup>Consultant Plastic Surgeon, Department of General Surgery, Baptist Hospital, Bangalore, India

<sup>5</sup>Consultant and Head, Department of Radiology, Baptist Hospital, Bangalore, India

<sup>6</sup>Consultant Pathologist, Department of Pathology, Baptist Hospital, Bangalore, India

<sup>7</sup>Surgical Resident, Department of General Surgery, Baptist Hospital, Bangalore, India

**\*Corresponding Author:** Satish Kumar KV, Consultant Pediatric Surgeon, Department of Pediatric Surgery, Baptist Hospital, Bangalore, India.

**Received:** September 09, 2020; **Published:** September 24, 2020

### Abstract

Lipoblastoma is a benign tumor occurring in infants and children, mostly localised to trunk and extremities and can cause compression symptoms. Imaging studies are complementary but definitive diagnosis is by histology.

A young boy presented with a large painless swelling over the right forearm for past 3 years, with recent rapid growth. A diffuse mass over flexor region of right forearm was noted with no neurological deficits. CT scan and MRI Scans suggested soft tissue lesion with fat, likely liposarcoma or lipoblastomatosis.

An incisional biopsy with frozen section showed benign lesion and a complete excision of the lesion was done. The final report was benign adipocytic tumor.

**Keywords:** Benign Adipocytic Tumor; Lipoma in Children; Lipoblastoma; Lipoblastomatosis; Lipomatous Tumors

### Introduction

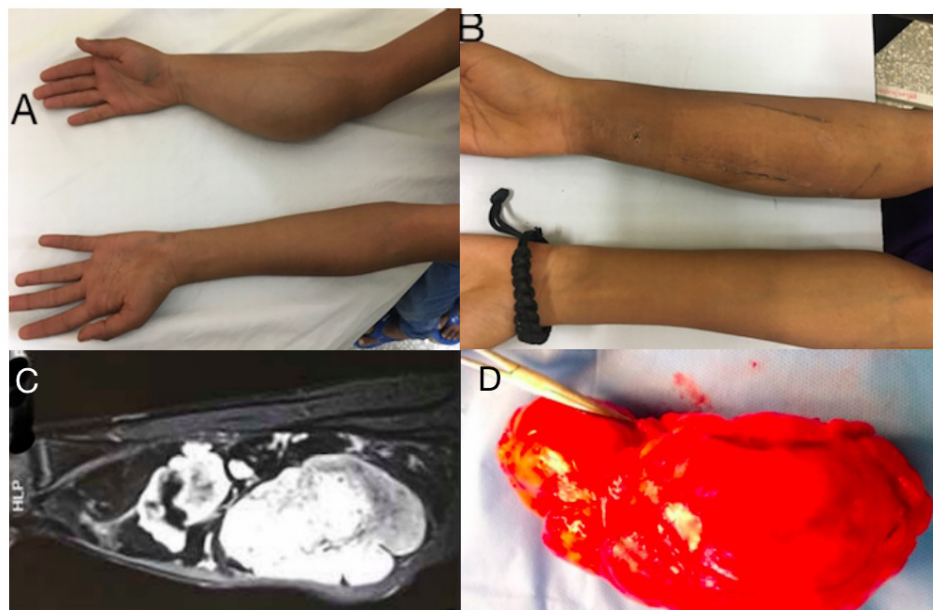
Soft tissue tumors in the extremities in children may be benign or malignant. While Lipomas are most common benign soft tissue tumors in adults they are uncommon in children. Lipoblastoma and lipoblastomatosis are variants of lipoma and are extremely rare benign tumors unique to children, which needs to be differentiated from its malignant counterpart. Imaging studies help in anatomical evaluation; but histological diagnosis is essential. Complete resection with preservation of vital structures is vital in order to prevent an otherwise high rate of recurrence.

### Case Report

A 10-year-old boy presented with 2 years' history of diffuse painless swelling over the right forearm (Figure 1A). The swelling, which gradually increased in size, had been growing rapidly for the past 2 months. Clinically the right forearm was diffusely enlarged with an ill-defined swelling limited to the flexor aspect. It was non-tender, firm in consistency, lobulated in places and appeared to be in the muscular

plane. There was full range of movement at elbow and wrist joints and the radial and ulnar pulsations were felt normally at right wrist. The neurological examination showed no sensory or motor deficit and the child had no restriction in using the arm.

Soft tissue ultrasound was suspicious of lipomatous tumor, and a malignancy could not be ruled out. A CT Angiogram of right forearm was not conclusive and suggested a differential diagnosis of liposarcoma or lipoblastomatosis. A core needle biopsy was reported as fibroadipose tissue with myxoid foci, with no atypia or malignancy. A MRI scan was obtained, which showed features suggestive of liposarcoma (Figure 1C). The child underwent incision biopsy and frozen section under general anesthesia. As the frozen section suggested benign lipomatous tumor with no suspicion of malignancy, it was decided to proceed for excision under same anesthesia. The biopsy incision was extended longitudinally and the mass was evaluated. It was a well encapsulated mass deep to the flexor muscle compartment with splaying and flattening of flexor muscles. The tumor reached upto the intact interosseous membrane; and the space between radius and ulna was widened. The mass was completely excised (Figure 1D) sparing the major vessels and nerves. Only a few smaller, insignificant arterial branches had to be ligated once the tourniquet was released. The wound was closed in layers with placement of a 12 fr. suction drain. The child was discharged the next day after removal of drain. On follow up, the recovery of limb function was complete with no neurovascular deficits. The child was last seen 2 years after surgery and has no recurrence. He could demonstrate a full range of elbow and wrist movements (Figure 1B).



**Figure 1:** A. Painless swelling over flexor aspect of right forearm. B. Post-operative picture 1 month after complete resection. C. MRI Scan - smooth marginated heterogenous mass involving forearm muscles- suspicious of Liposarcoma. D. Completely Resected tumor with no gross residue.

## Discussion

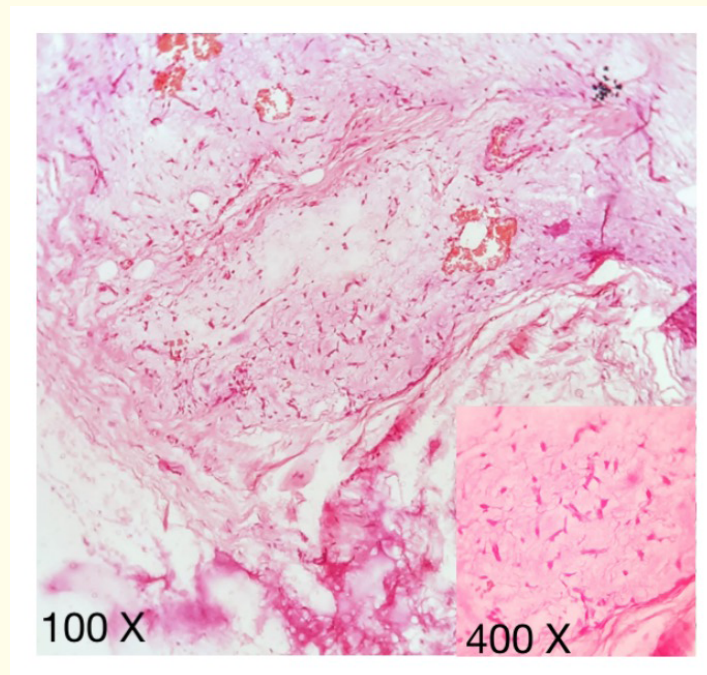
Lipomatous tumors comprise of lipoma and its variants including its malignant counterpart. Lipomas are tumors composed of mature fat cells and are very rare in first 2 decades of life. Variants of lipoma differ from ordinary lipoma by characteristic microscopic picture

and specific clinical setting. These include angioliipoma, myolipoma, myelolipoma, chondroid lipoma, spindle cell (pleomorphic) lipoma, hibernoma, and lipoblastoma/lipoblastomatosis [1].

Lipoblastoma and lipoblastomatosis refer to circumscribed and diffuse forms of these tumors, which occur almost exclusively in infants and children below 3 years (88%) [2]. The term lipoblastoma was coined by Jaffe (1926) and in the year 1958, Vellios, *et al.* coined the term lipoblastomatosis [3]. Histologically they are composed of immature adipocytes with relatively well defined septae, frequent lipoblasts, a fine vascular network with a myxoid stroma [4].

The most common sites of occurrence are the upper and lower extremities [2] (46 - 70%), although the head, neck, trunk and retroperitoneum may also be affected. The clinical presentation is that of a rapidly growing painless mass and should be differentiated from benign lipoma, liposarcoma and myxoliposarcoma [5]. As there are no specific diagnostic features of lipoblastomas on CT and MRI Scans, their main use would be for surgical planning and postoperative surveillance [3]. In our index patient, though CT scan suggested lipoblastomatosis as a possible diagnosis, we could not rule out liposarcoma. MRI showed some features suggestive of a liposarcoma (Figure 1C). MRI provides excellent anatomical details in extremity tumors, but cannot conclusively differentiate lipoblastoma from liposarcoma [6,7]. Needle biopsy has been suggested to be diagnostic when supplemented with immunohistochemistry.

Core needle biopsy done in our patient suggested a benign pathology; however, because of the rapid growth of the lesion and the radiological features, an intraoperative frozen section was planned. An incision biopsy under general anesthesia was performed. Frozen section confirmed lipoblastoma with no evidence of malignancy. The incision was extended longitudinally and the tumor was completely resected under the same anesthesia. The final histopathology confirmed diffuse Lipoblastoma (Figure 2).



**Figure 2:** Histopathology - Low power field (100X), hypocellular lobules of adipocytes separated by septae in a myxoid stroma, with plexiform cells and stellate cells. High power field in Inset (400X). Various stages of Lipoblastoma maturation with multivacuolated lipoblast.

Few genetic abnormalities have been identified in lipoblastoma. These include chromosomal rearrangements involving the 8q11.13 region and rearrangement of the pleomorphic adenoma gene 1 (PLAG1) on chromosome 8 [8]. Incomplete resection can lead to recurrence. Coffins, *et al.* noted a recurrence rate of 46% among 59 cases of Lipoblastoma [9], which occurred more commonly in the diffuse type. Even though high rate of recurrence has been reported, there is no role for radical surgery, as transformation to malignancy has not been reported. Our patient has been followed up for 2 years after surgery with no recurrence. He has been asked to return for further follow up. A minimum follow-up period of 3 years has been suggested after resection, as recurrences are unlikely after this period [3].

**Salient points on planning incision biopsy in extremity soft tissue tumors**

1. The incision should be of adequate length; enough to take a sufficient sample (For frozen section, definitive histopathology and immunohistochemistry).
2. Should be placed longitudinally along the extremity. This will ensure that the incision can be extended for future resection if required and can also be included in the field for local radiotherapy in case it is indicated.
3. Minimise raising of flaps. This minimises spread of the tumour cells into skin and subcutaneous tissue.
4. Avoid drains; if necessary, suction drains should be placed closer to the incision. This ensures minimising excess skin loss if future resection is needed.

**Conclusion**

Lipoblastomas are benign encapsulated tumors of embryonic fat cells with tendency for local tissue invasion. Clinical judgement and judicious use of incision biopsy is helpful in planning definitive surgery as there are no specific diagnostic features found on imaging. As they are localised, complete resection should be attempted as recurrence rates are high if there is any residual tumour.

**Bibliography**

1. Goldblum JR., *et al.* "Benign Lipomatous Tumors". Enzinger and Weiss's Soft Tissue Tumors. 7<sup>th</sup> edition (2020): 476-519.
2. Chena CW., *et al.* "MRI features of lipoblastoma: differentiating from other palpable lipomatous tumor in pediatric patients". *Clinical Imaging* 34 (2010): 453-457.
3. Speera AL., *et al.* "Contemporary management of lipoblastoma". *Journal of Pediatric Surgery* 43 (2008): 1295-1300.
4. Hicks J., *et al.* "Lipoblastoma and lipoblastomatosis in infancy and childhood: histopathologic, ultrastructural, and cytogenetic features". *Ultrastructural Pathology* 25.4 (2001): 321-333.
5. Stringel G., *et al.* "Lipoblastoma in infants and children". *Journal of Pediatric Surgery* 17.3 (1982): 277-280.
6. Kransdorf MJ., *et al.* "Fat-containing soft-tissue masses of extremities". *Radio Graphics* 11 (1991): 81-106.
7. Ha TV., *et al.* "MR imaging of benign fatty tumors in children: report of 4 cases and review of literature". *Skeletal Radiology* 23 (1994): 361-367.
8. Putraa J and Ibraheemi AA. "Adipocytic tumors in Children: A contemporary review". *Seminars in Diagnostic Pathology* 36.2 (2019): 95-104.
9. Coffin CM., *et al.* "Lipoblastoma (LPB): a clinicopathologic and immunohistochemical analysis of 59 cases". *The American Journal of Surgical Pathology* 33 (2009): 1705-1712.

**Volume 9 Issue 10 October 2020****© All rights reserved by Satish Kumar KV, *et al.***