

## Paediatric Oesophageal Foreign Bodies, A Retrospective Review of 1558 Cases

**Abdelaziz Raji, Maha Hakimi\*, Hadid Fatima Zahra, Youssef Rochdi, Hassan Nouri and Elfakiri Mehdi**

*ENT - Neck and Head Surgery Department, University Medical Center Mohammed VI Marrakech, Morocco*

**\*Corresponding Author:** Maha Hakimi, ENT - Neck and Head Surgery Department, University Medical Center Mohammed VI Marrakech, Morocco.

**Received:** August 12, 2020; **Published:** September 30, 2020

### Abstract

Oesophageal foreign bodies are a frequent and common incurrence in the ENT practice, primarily seen in the paediatric population specifically between 6 months and 3 years of age. The eating habits as well as the age of the patients determine the nature of the foreign body.

In this context, the main goal of this study was to share the ENT department experience in the university Hospital Mohamed VI in Marrakesh by describing the clinical, paraclinical and therapeutical characteristics of foreign bodies trapped in the oesophagus, review the literature and to come up with a unifying management policy to insure an optimal care for patients. On a period spreading over 10 years: we collected a total of 1558 cases of paediatric oesophageal foreign bodies ingestion; with an average age of 2.3 years old; a large majority of patients were younger than 3 years old (51.3%); The most common symptom was odynophagia (40,5%); followed by drooling of saliva (35%). The large majority of foreign body was coins (1033 cases), then bones in 223 cases; we also had 13 cases of disc battery. The extraction was in 100% of cases under general anaesthesia; in the operating room using a rigid esophagoscopy and the Foreign Body was then removed using grasping pliers. The esophagoscopy was then reintroduced to check for retained FB and apparent lesions.

Foreign body ingestions are most often part of domestic accidents. Each year, more than 20,000 children between the ages of 1 and 14 suffer accidental ingestion of Foreign bodies in developed countries. Any object that can be picked up by a child is likely to be carried away then willingly put in the mouth and naturally be ingested. Thus, globally, coins dominate most of the Foreign bodies in children. Therapeutically, the need to reduce mortality and morbidity rates should encourage our practitioners to improve the methods of extraction, including endoscopical resources. The education of parents but also the awareness of the general public of the dangers caused by the ingestion of foreign bodies, allows to prevent those incidents and reduce astronomically their Morbi-mortality.

**Keywords:** *Oesophagus; Foreign Body; Esophagoscopy; Disc Battery; Mediastinitis*

### Introduction

Oesophageal foreign objects are a frequent and common incurrence in the ENT practice, though primarily seen in the paediatric population specifically between 6 months and 3 years of age, it can also, in various percentage, be seen in adults. It is also important to note that although the development of endoscopy has made it possible to considerably reduce mortality, ingested foreign bodies remain a source of morbidity especially in third world countries probably due to the often-inaccessible equipment and longer time lapses between ingestion

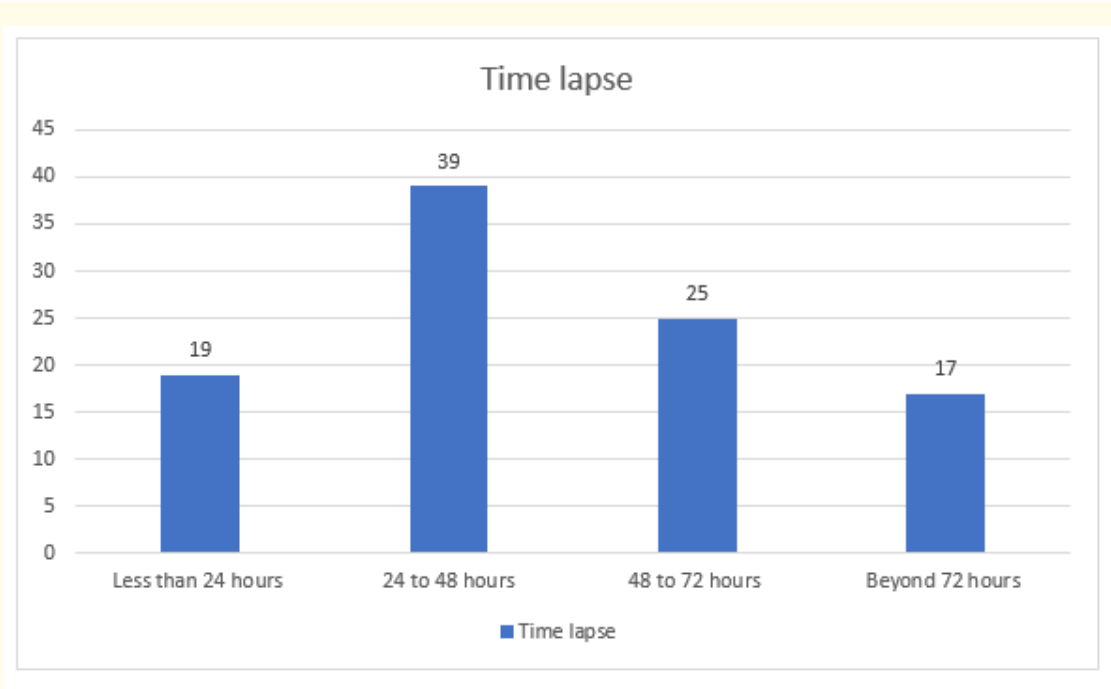
and seeking medical attention. Most swallowed foreign objects will pass harmlessly through the gastrointestinal tract (80 - 90% of cases), but some may become lodged and/or traumatise the mucosa or cause caustic burn injuries or even gastrointestinal perforation; requiring an endoscopic or surgical removal. The eating habits as well as the age of the patients determine the nature of the foreign body. In this context, the main goal of this study was to share the ENT department experience in the university Hospital Mohamed VI in Marrakesh by describing the clinical, paraclinical and therapeutical characteristics of foreign bodies trapped in the oesophagus, review the literature and to come up with a unifying management policy to insure an optimal care for patients.

### Methods

This is a retrospective descriptive study, spread over a period of 10 years from January 2010 to January 2020; where we reviewed the records of all children; up to the age of 14 years old; who were admitted to Mohamed VI university Hospital of Marrakech, Morocco; with a final diagnosis of oesophageal foreign body ingestion and excluding other localisations into the gastro-intestinal tract. The data collected included the demographics, the time lapses since ingestion, presenting symptoms, management, complications and outcomes. A cervical and chest X-Ray was performed in all patients.

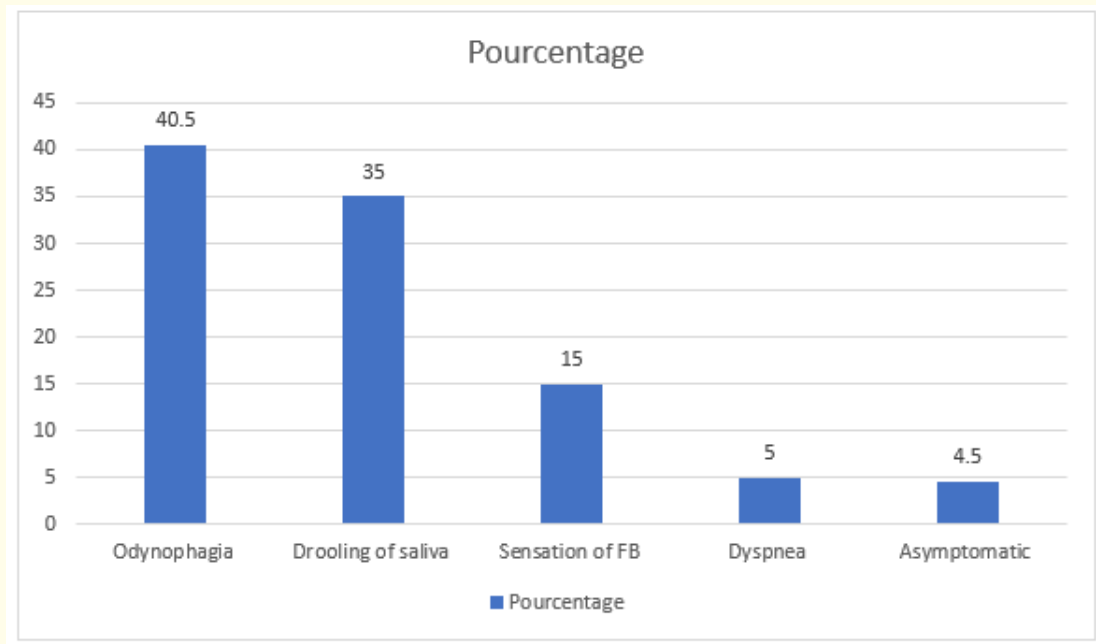
### Results

On a period spreading over 10 years: a total of 1558 cases of paediatric oesophageal foreign bodies ingestion; with an average age of 2.3 years old; a large majority of patients were younger than 3 years old (51.3%) and only 12% were older than 10 years old; The youngest patient was 5 months old and the oldest 13 years old. The male: female ratio was 1.5; noting a predominantly male population. The time lapse between the ingestion and medical consultation was between 24 and 48 hours in 39% of cases (Graph 1).



Graph 1

The most common symptom was odynophagia (40,5%); followed by drooling of saliva (35%) (Graph 2).



Graph 2

The large majority of foreign body was coins (1033 cases) (Figure 1), then bones in 223 cases; we also had 13 cases of disc battery (Figure 2), which were extreme emergencies (Table 1).

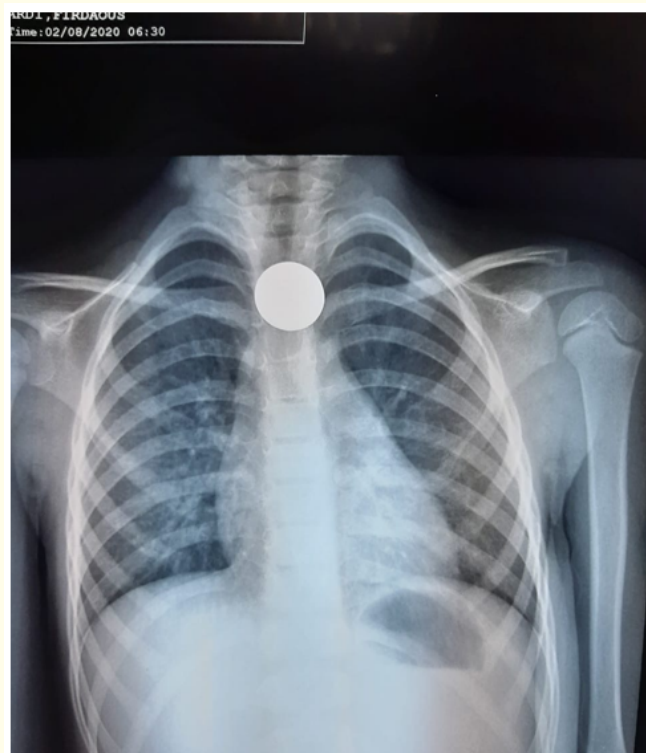
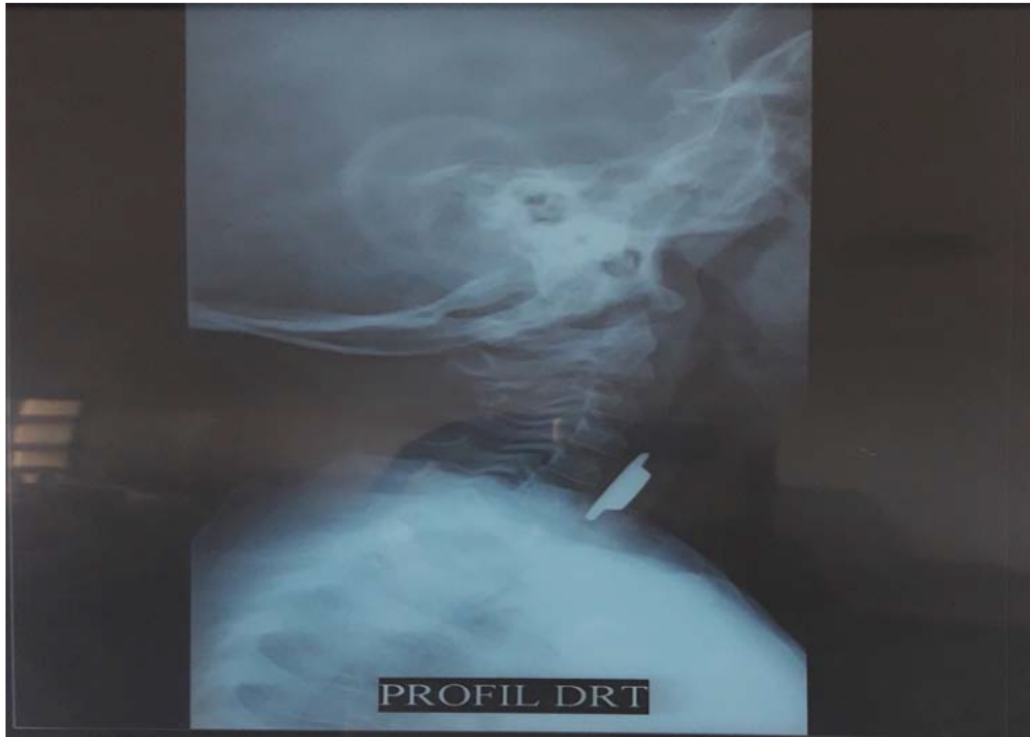

Figure 1: Radiography of a foreign body (coin) of an 8-year-old.



**Figure 2:** Radiography of a foreign body (Disc battery) in 15 months old.

Nature of the Foreign object	Numbers	Percentage
Coins	1033	66.3
Bone	223	14.04
Fish Bone	178	11.42
Meat	50	3.2
Plastic Materials	28	1.79
Metals	12	0.77
Rocks	18	1.15
Disc Battery	13	0.83
Leach (Figure 4)	03	0.19
Total	1558	100

Cervical and Chest X-ray was performed in all the patients despite the nature of the foreign object; and the Foreign Body was detected in 81.94% of cases.

The extraction was in 100% of cases under general anaesthesia in 80% without endotracheal intubation; in the operating room using an esophagoscopy (Rigid esophagoscopy) and the Foreign Body was then removed using grasping pliers. The esophagoscopy was then reintroduced to check for retained Foreign Bodies and apparent lesions.

The average hospitalisation length was 2.3 days, ranging from 24 hours to 6 days at most. The large majority was hospitalized for 24 hours (86%). Mortality rate was of 0.12% secondary to two cases of mediastinitis due to a Disc battery foreign object in one case and a piece of chicken bone in the other, both cases were neglected foreign body ingestion, with a diagnostic delay of 5 days in the first case and 6 days in the other one, both cases were hospitalized in the paediatric intensive care unit but died within an average of 7 days due in both cases to septic shock. 3 other patients presented with complications secondary to Foreign Body ingestion. The first one presented a limited lesion of the posterior wall of the oesophagus secondary to a chicken bone; the FB was removed, and the patient was put on parenteral antibiotics for 15 days [consisting of Amoxicillin/clavulanic (80 mg/kg/day) associated with metronidazole (40 mg/kg/day and an aminoglycoside (2 mg/kg/day)] and gastric rest for 48 hours. The lesion healed nicely, and no other complications was noted in this patient including no oesophagus stenosis; the surveillance of this patient, as of all the other complicated cases consisted of a thorough clinical examination and a systematic rigid esophagoscopy within a 3 months period. The two other patients presented due to ingestion of disc battery which lodged into the mouth of the oesophagus for 48 hours for the first one and 5 days for the other one ; because of the important delay in consultation, even though the FB was extracted in both cases; the patients presented a perforation of the oesophagus which needed a strict gastric rest and placement of a nasogastric tube and large spectre antibiotics [consisting of Amoxicillin/clavulanic (80 mg/kg/day) associated with metronidazole (40 mg/kg/day and an aminoglycoside (2 mg/kg/day)] (for an average of 4 weeks); the perforations healed spontaneously (as noted through the rigid esophagoscopy) and with a 1 year follow-up, we noted no new complains including no sign of oesophagus stenosis.

**Discussion**

Foreign body ingestions are most often part of domestic accidents. These are, according to the World Health Organization (WHO), defined as accidents that occur at home or in its immediate surroundings [1]. It is also a very common situation in pediatric population (Table 2); all children ingest foreign bodies; regardless of their age, however it is more common in younger patients as they explore and interact with the world. Ingestion of Foreign bodies occurs mostly at the two extreme ages of life. It is estimated at 70% in children under 6 years old and 15 - 20% in edentulous old patients [2]. International data is scarce, but in pediatrics population the ingestion of foreign bodies remains a global problem [3]. Despite its high frequency and severity, this phenomenon is scarcely documented in developing countries, particularly in sub-Saharan Africa where the concern remains primarily infectious diseases and malnutrition [4]. Yet the number of years of life lost and disability due to domestic accidents have a much higher prevalence there, than in industrialized countries [3,4].

Country	Frequency
USA [5]	93500 cases in 2011
France [6]	1,2 million children per year
Algeria [7]	381 cases in 2000
Tunisia [8]	1800 cases per year
Senegal [9]	381 children in years
Morocco (our study)	1558 children in 10 year

**Table 2:** Frequency of FB ingestions observed in different countries.

Each year, more than 20,000 children between the ages of 1 and 14 suffer accidental ingestion of Foreign bodies in developed countries. In Spain, these accidents constitute the third cause of death among children under the age of 15 [10]. The 2011 Annual Report of the American Association for National Data on poisons reported that more than 110,000 FB ingestion was reported in the United States that year, with over 85% in the pediatric population [11]. In France, it is estimated that 1.2 million children per year are victims of domestic accidents of this nature [12]. Our study identified 1558 cases of accidental ingestion of foreign bodies in children under the age of 15 over a period of 10 years. This sample cannot, obviously, allow a complete analysis of the epidemiological aspects of Foreign body ingestion in terms of national data, as the majority of patients came from the Marrakech region and surroundings. However, this data could be tremendously useful to establish a first inventory of esophageal foreign bodies in children and thus help raise the alarm bell. Generally speaking; Foreign body ingestion can occur at any age, but there is nevertheless a clear predominance in the pediatric population; as summarized in table 3.

Study	Average age
Delpont [13]	3 years old
M. Belarbi, <i>et al.</i> [14]	3,5 years old
M. Lakhdar-Idrissi [15]	4 years old
M. Wai Pak [16]	5 years old
Our study	2,3 years old

**Table 3:** Comparison of the average age of patient in our series with other series in the literature.


The male predominance observed in the majority of the series, as was the case in our study; finds no satisfactory hypothesis. Some authors explain it by the audacity and the nature of the games of young boys [15].

Once the ingestion of foreign bodies is suspected by the family; our role as doctors is a methodical and well-conducted questioning as the first step of the clinical study. When the accident takes place in the presence of a witness, the diagnosis and management are generally accelerated and are less problematic in the paediatric population. However, when the ingestion of FB is unrecognized, it may lead to a long-time lapse between the ingestion and medical consultation and symptoms may even, unfortunately, mimic other conditions. Thus, it is vital to try to glean as much information as possible from the child or the entourage as to the time of ingestion; the nature of the FB, its size; the possible multiple number of FBs; time of last meal; a possible history of esophageal disease, dysphagia, food blockage or motor handicap. The questioning also helps to determine the circumstances of the accident. An uncertain ingestion story may be the only clinical data, but it never should be neglected. Symptoms are sometimes delayed from a few minutes to several hours, or even do not appear until complications arise. Various risk factors must be sought such as: esophageal anatomical abnormalities, mental retardation, hyperactivity, neglect or abuse, family instability, hearing aids [17].

A retrospective study done at the Medical University hospital of South Carolina from May 1980 to May 1995 regarding 118 children showed that 60% of patients consulted within 24 hours of the ingestion [18]. When the ingestion is unrecognized or asymptomatic, this period can range from a few weeks to even several months [19]. There is obviously a correlation between the severity of complications and the time lapse between the ingestion and admission time. In the study of 122 cases of FB of the esophagus made by LASCOMBE, with an ingestion-admission delay varying from a few hours to several weeks, 16 patients presented symptoms indicating the seriousness of their condition as soon as arrival at the hospital both clinically and Para clinically, often with esophageal lesions [20]. In our series, patients consulted for FB ingestion within the first 24 hours in only 19% of cases and within 24 to 48 hours in 39% of cases. This can easily be explained by the following factors: the under-medicalization and the low socio-economic standing which characterize our country 's social development; Lack of knowledge of the ingestion, especially in cases where the incident was not seen by an adult; the fearful nature

of children and parents with regard to health structures, neglect of the entourage increased by the installation of a period of tolerance of the foreign object.

Any object that can be picked up by a child is likely to be carried away then willingly put in the mouth and naturally be ingested. Thus, in industrialized countries (in the United States as in Europe), globally, coins dominate most of the FB in children [21]. In developing countries, the relaxation of parental attention is often blamed in the occurrence of this incident. Therefore, the nature of the ingested FB is variable from one study to another, but mostly variable according to the age of the patients. In short, the type of ingested FBs differs among countries according to feeding habits, cultural features and sociocultural characteristics (Figure 3). Several studies found that coins are the most common FB to be ingested regardless of the stature of the country [22]. In Asian populations, for example, the second most common FB remains fish bones, accordingly to their most common food supply [23].



**Figure 3:** A collection a different oesophageal foreign body extracted in children.



The clinical aspects of esophageal FB are variable but the practitioner is often brought to make the diagnosis in three main circumstances:

- In the immediate aftermath of the accident, these are the cases where the symptoms of the initial episode are clear, disturbing, and require urgent management.
- In the course of the initial episode even though the urgency is relative, these are the cases seen in the deceptive lull phase or free interval phase (the child is tonic, which falsely reassures parents).
- Finally several days or even weeks after the accident, when the so-called “Indwelling syndrome” is underway and frequently on the occasion of complications.

In general, symptoms secondary to ingested FB depend on the patient’s age, medical and surgical history, the size, nature and location of the FB or the occurrence of complications. In children, the symptoms are more misleading and are usually revealed by those closest to them. When a FB is swallowed, it passes 5 times more often through the digestive tract than through the airways [2]. Ingestion of FB may be revealed by retro sternal pain, odynophagia, dysphagia, hyper sialorrhea, epigastralgia, digestive hemorrhages and sometimes vomiting for large obstructive objects [24]. In all cases of suspected FB ingestion, it is essential to take a thorough radiological stock of all suspected cases. Standard x-rays are classic investigative tools, though upper gastrointestinal series may be performed if the FB is X-ray transparent [25] and computed tomography if a complication is suspected [26]. The large majority of ingested FB are radiopaque, visible on a cervical spine x-ray which make it the recommended first-line examination by all the authors and ideally produced in five forms (Anterior-posterior view (AP) and lateral cervical spine radiography, AP and lateral chest radiography, and plain abdominal X-ray) [27]. For most radiopaque FBs, it confirms the diagnosis, it outlines their seat, nature, number and size.

At the level of the oesophagus, the lateral imaging confirms if necessary, the posterior position of the FB compared to the anterior clarities of the larynx and trachea [28]. It can also be used to distinguish coins from disc batteries (Figure 4) [29]. For bones that are not very radiopaque, the profile image allows them to be distinguished from cervical vertebrae. FB should, obviously, be differentiated from other cervical opacities, especially calcifications of the thyroid, cartilage, salivary glands or lymph nodes [29]. The computed tomography remains the ideal exam to show transparent X-ray FBs not detected by standard radiography and permits, especially, to assess any eventual complications [29]. However, it should not be prescribed as a first-line exam. Most studies have showed a sensitivity of 100% and a specificity of 70 to 93.7% in using computed tomography [29]. Finally, the ultimate and most important exam remains the rigid esophagoscopy, essential for both diagnostical and therapeutical reasons. Indeed, it constitutes the last element of the etiological investigation and the first stage of the treatment of FB whether radiopaque or radiotransparent. Thus, Rigid esophagoscopy; makes it possible to carry out a morphological and lesion assessment and constitutes therefore the superior method for the recovery of esophageal FB, with a rate of success approaching 100% [30]. The introduction of the esophagoscopy is a delicate moment due to the extreme sensitivity of the oropharyngeal crossroads. This exam can visualize the FB and therefore confirm the diagnosis and check the condition of the digestive mucosa [26]. The duration of this act; performed by an experienced operator is 3 to 5 minutes at most. Therefore, rigid esophagoscopy is the gold standard in the management of esophageal FB. This method requires deep general anesthesia in order to obtain sufficient muscle relaxation (prevents spasm of the esophageal mouth when going through the esophagus). Fasting for six hours is preferable, though it should not delay treatment in the event of an emergency extraction. Close cooperation between the surgeon and anesthesiologist is therefore essential to avoid any laryngospasm. The equipment consists of a rigid esophagoscope with cold light, and a rigid or flexible suction. The main tools used for the extraction of FB are: claw forceps, double spoon forceps, trident forceps, biopsy forceps, forceps crocodiles, magnetic clips, traps, extraction baskets.





**Figure 4:** A leech found in the oesophagus of a 10-year-old (after he drunk from a well).

Oesophageal FB can cause mechanical or infectious complications, local or remote. These complications may be acute, but also chronic and progressive [31]. The overall rate of complications is generally estimated to be between 1 and 4% of cases. They are therefore quite rare, but particularly serious when they occur [30]. Perforation is, by far, the most common complication and the severity of which should not be underestimated. It can occur at any age. Disc batteries present a significant risk, as they quickly necrose the Esophageal wall by several synergistic mechanisms [30]. The diagnosis of perforations of the esophagus by FB is difficult because it is usually extremely delayed in about a quarter of cases. CT and esophagoscopy are essential for the diagnosis and treatment of esophageal perforations by FB. The diagnosis of perforation is a clinical emergency for which the therapeutic sanction is surgical. Mortality from ingestion of FB has decreased significantly since the improvement of new support techniques. It was 57% a century ago, 5% in the 1960s and less than 1% since 1995 [32]. In general, the prognosis depends on the type of body ingested, its aggressiveness and the passing time between the ingestion and the diagnosis. Ingestion of FB in children is a frequent domestic accident with the obvious solution being prevention. Growing up involves many risks for children. It's up to the parents to reduce those risks as much as possible by close monitoring, which at an early age should be constant. A number of precautions make it possible to rule out the vast majority of foreseeable risks, and with time and attention the child will then master those precautions through progressive education.

## Conclusion

Esophageal Foreign bodies represent a major accident firstly because of their frequency and secondly because of their possible severity. The clinical symptoms are very rich and vary according to the location and sometimes the nature of the foreign body. A complete

clinical examination and a thorough interrogation are the building stones of the diagnosis. The radiological examination can usually confirm the diagnosis by visualizing the foreign body if it is radiopaque, or by visualizing eventual complications. Rigid esophagoscopy is the essential treatment tool to visualize and later on extract the foreign body. Through this work we have found that the ingestion of FB in children is a universal accident, quite frequent, that can also be serious and even sometimes fatal, which make it extremely relevant. Thus, it seems important for us medical practitioners to preach a prevention tactic in order to decrease the frequency of oesophageal foreign bodies and their sometimes-substantial complications.

### Conflict of Interest

The authors declare no conflict of interest.

### Consent

Oral consent of the parents of the children has been obtained for the publication of these cases.

### Authors Contribution

All the authors contributed equally to this work.

### Bibliography

1. Baudet M., *et al.* "Intoxications accidentelles domestiques". *EMC Toxicologie Pathologie* 1.2 (2004) :29-34.
2. Monat S., *et al.* "Prise en charge des corps étrangers du tractus digestif supérieur". *Hépatogastro-Entérologie* 8.3 (2001): 179-187.
3. Kobusingye O., *et al.* "Injury patterns in rural and urban Uganda". *Injury Prevention* 7 (2001): 46-50.
4. Organisation Mondiale De La Santé Rapport sur la santé dans le monde en 2000. Genève (2001): 182.
5. Wright Cc and Closson Ft. "Updates in pediatric gastrointestinal foreign bodies". *Pediatric Clinics of North America* 60 (2013): 1221-1396.
6. Felix M and Tursz A. "Les accidents domestiques de l'enfant: un problème majeur de santé public". Paris: Edition. Syros-alternatives (1991): 101-108
7. Ministère De La Santé Publique Et De La Réforme Hospitalière. Coopération Internationale De Prévention Des Traumatismes: Une Approche Globale Des Stratégies Locales. Vie Séminaire International De Prévention Des Traumatismes Et De La Promotion De Sécurité. Annaba, Algérie (2005).
8. Rekik A., *et al.* "Profil épidémiologique des accidents de l'enfant en Tunisie". *Pédiatrie* 44 (1989): 721-724.
9. Ka AS., *et al.* "Épidémiologie et pronostic des accidents chez l'enfant à Dakar (Sénégal)". *Medicina Tropical* 63 (2003): 533-538.
10. Ana Lobeiras., *et al.* "Emergency department consultations due to foreign body ingestion Epidemiology of foreign body ingestion".
11. Wright Cc and Closson Ft. "Updates in pediatric gastrointestinal foreign bodies". *Pediatric Clinics of North America* 60 (2013): 1221-1396.
12. Felix M and Tursz A. "Les accidents domestiques de l'enfant: un problème majeur de santé public". Paris: Edition. Syros-alternatives (1991): 101-108.

13. CD Delpont, *et al.* "Investigation and management of foreign body ingestion in children at a major paediatric trauma unit in South Africa". *African Journal of Emergency Medicine* 5.4 (2015): 176-180.
14. M Belarbi, *et al.* "Chu Med Vi Marrakech, Marrakech, Morocco L'ingestion de corps étranger chez l'enfant: étude rétrospective de 116".
15. M Lakdhar-Idrissi and M Hida. "Foreign body ingestion in children: 105 case reports". *Archives de Pédiatrie* 18 (2011): 856-862.
16. M Wai Pak, *et al.* "A prospective study of foreign-body ingestion in 311 children". *International Journal of Pediatric Otorhinolaryngology* 58 (2001): 37-45.
17. Giordano A., *et al.* "Current management of esophageal foreign bodies". *Archives of Otolaryngology* 107 (1981): 249-251.
18. RI Macpherson, *et al.* "Esophageal foreign bodies in children: diagnosis, treatment and complications". *AJR* 166 (1996): 919-924.
19. Singh B., *et al.* "Complications associated with 327 foreign bodies of the pharynx, larynx, and esophagus". *Annals of Otolaryngology, Rhinology, and Laryngology* 106 (1997): 301-304.
20. Aanoun N. "Les corps étrangers de l'oesophage: A propos de 8 cas". Thèse De Médecine (2004): 292.
21. A Haennig, *et al.* "Conduite à tenir devant une ingestion de corps étrangers". *Hépatogastro* 18 (2011): 249-257.
22. DC Little, *et al.* "Esophageal foreign bodies in the pediatric population: our first 500 cases". *Journal of Pediatric Surgery* 41 (2006): 914-918.
23. M Wai Pak, *et al.* "A prospective study of FB ingestion in 311 children". *International Journal of Pediatric Otorhinolaryngology* 58 (2011): 37-45.
24. JC Letard, *et al.* "Les corps étrangers ingérés". Recommandations de la société française d'endoscopie digestive. Septembre Paris: IPSEN, (2004): 6.
25. Aanoun N. "Les corps étrangers de l'oesophage: A propos de 8 cas". Thèse De Médecine (2004): 292.
26. Mlle Saloua Lahlou. "Ingestions de corps étrangers". Thèse doctorat médecine, Marrakech (2008): 22.
27. Mlle Fadoua El. "Farssani Prise en charge des corps étrangers des voies aéro-digestives en ORL". Thèse doctorat médecine, Marrakech (2016): 147.
28. L. Michaud and M Bellaïche JP. "Olives Ingestion de corps étrangers chez l'enfant". Recommandations du Groupe francophone, d'hépatologie, gastroentérologie et nutrition pédiatriques *Archives de Pédiatrie* 16 (2009): 54-61.
29. P Lheureux, *et al.* "Ingestion de corps étranger: Attitude pratique". *Réan Urg* 5 (1996): 637-653.
30. Webs WA. "Management of foreign bodies of the upper gastrointestinal track: update". *Gastrointestinal Endoscopy* 41.1 (1995): 39-51.
31. Antoine Lamblin, *et al.* "Pierre-François Wey Prise en charge des corps étrangers du tiers supérieur de l'oesophage sans endoscope: un défi pour le médecin en situation isolée?" *Pan African Medical Journal* 30 (2018): 42.
32. Zhao-Shen L, *et al.* "Endoscopic management of foreign bodies in the upper-GI tract: experience with 1088 cases in China". *Gastrointestinal Endoscopy* 64.4 (2006): 485-492.

**Volume 9 Issue 10 October 2020**

©All rights reserved by Maha Hakimi, *et al.*