

## Infant Cystic Duct Cyst - Case Report and Literature Review

Cassiana Pessoa Kotzias<sup>1</sup>, Diana Delgado Lindeman<sup>1</sup>, Ricardo Patino Baptista<sup>1\*</sup>, Marcus Laks<sup>1,2</sup>, Ana Claudia Pereira Cardoso Ribeiro<sup>1,2</sup> and Mauricio Giusti Calderon<sup>1,3,4</sup>

<sup>1</sup>Pediatric Surgery Department, Conjunto Hospitalar do Mandaqui, Sao Paulo, SP, Brazil

<sup>2</sup>Pediatric Surgery Professor, College of Medicine, University Nine of July, Sao Paulo, SP, Brazil

<sup>3</sup>General Surgery Professor, College of Medicine, University Nine of July, Sa Bernardo do Campo, SP, Brazil

<sup>4</sup>Pediatric Surgery Department, Hospital Santa Catarina, Sao Paulo, SP, Brazil

**\*Corresponding Author:** Ricardo Patiño Batista, Pediatric Surgery Department, Conjunto Hospitalar do Mandaqui, R: Voluntários da Pátria, 4301 - Santana, São Paulo - SP, Brazil. CEP: 02401-400.

**Received:** June 24, 2020; **Published:** July 28, 2020

**DOI:** 10.31080/ecpe.2020.09.00764

### Abstract

The cystic malformation of the cystic duct is a rare disease and was first reported by Bode and Aust in 1983. There were several different nomenclatures since then, including cyst of the cystic duct. Rarely diagnosed in adult life, this case occurred in infants and evolved with perforation of the common hepatic duct. This malformation manifests as abdominal pain, jaundice, cholangitis, choledocholithiasis, and pancreatitis. Retrograde cholangiopancreatography is the gold standard for diagnosis; however, it is not uncommon to be an intra-operative finding. The treatment is surgical with excellent results. In this case, we highlight the importance of imaging exams in the evaluation, describing an infant with a cystic malformation of the cystic duct with perforation of the common bile duct.

**Keywords:** Children; Congenital Biliary Dilatation; Cystic Duct; Bile Duct Diseases; Case Report

### Abbreviations

CT: Computerized Tomography; MR: Magnetic Resonance; US: Ultrasound

### Introduction

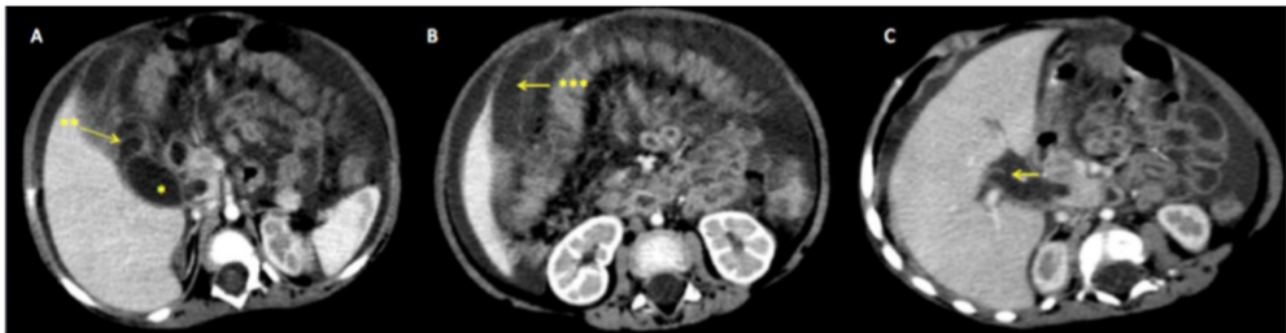Brode and Aust described the first case report of a cystic duct cyst alone in 1983, in a seven years old child [1]. In 1987, Champetier, *et al.* reported two cases [2] and only in 1991, Serrena, *et al.* described one case and suggested that anatomic variation should be included in Todani's classification as type VI [3]. Loke, *et al.* proposed that this lesion would be a type II variant [4]. The choledochal cysts are congenital abnormalities with intra and/or extrahepatic bile ducts dilatations, with a prevalence between 1:100,000 to 1:150,000 live births in the western countries, with a female predisposition in a proportion of 3 to 4:1 and usually diagnosed in the first years of life [5]. The cystic duct cyst alone is extremely rare, and there are few cases reported in the literature [6]. Some authors propose to include on Todani's classification as type VI and others as a variant of type II [7]. The most accepted theory is that it is a result of the combination of a biliopancreatic junction anomaly, with an acute angulation, and a large implantation orifice of the cystic duct in the hepatic duct. Other factors also reported as possible causes of the dilatation of the cystic duct are a congenital stenosis or an aganglionic segment of the bile duct with a proximal dilatation [8].

## Materials and Methods

We retrospectively collected data of one patient from the clinical records between 2018 and 2019 at Conjunto Hospitalar do Mandaqui, Sao Paulo, Brazil. Ethics committee approval by Secretaria de Saude do Estado de Sa o Paulo (Plataforma Brasil no 30619220.0.0000.5551). We obtained the informed consent from both patient’s parents and followed the SCARE guideline in this report [9].

## Case Report and Discussion

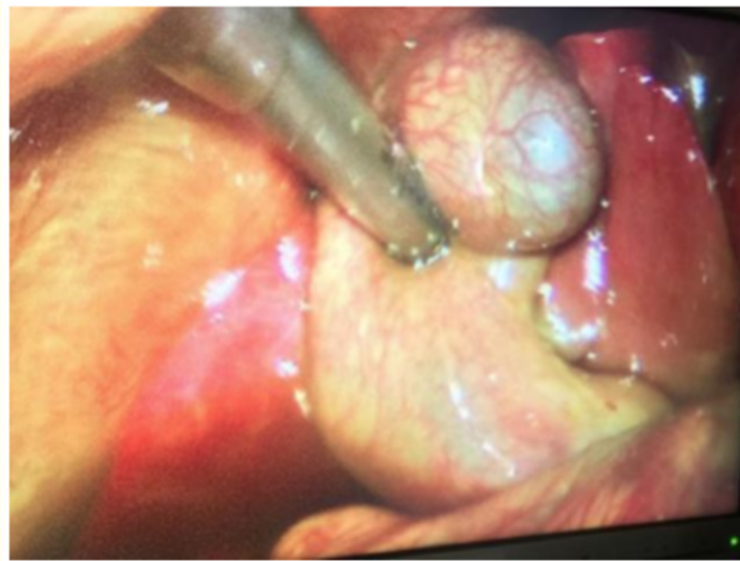A female infant, eight months old, white, started with vomiting for seven days, mainly after eating. After three days, she started with liquid diarrhea. She had no previous episode. She was in non-exclusive breastfeeding. She was born at term without pregnancy complications, no similar family history. In physical examination, she was in regular general condition, anicteric, afebrile, active, and reactive, weighting 8 Kg heart rate of 100 beats per minute, 20 breaths per minute, 98% oxygen saturation. Abdomen without collateral circulation, without scars, without bulging, normotympanic, normal bowel sounds, with diffuse pain but no peritoneal reactiveness, no palpable masses, but positive fluid wave test. At admission the laboratory exams were: hemoglobin - 9,6 g/dL, amylase 59 U/L, direct (conjugated) bilirubin - 1,7 mg/dL and indirect bilirubin - 0,53 mg/dL, alkaline phosphatase - 589 U/l e  $\gamma$ -gt - 1220 U/L; abdomen US showing dilation of intrahepatic bile ducts, with an anechoic cystic image with well-defined limits over the portal vein and below the gallbladder, measuring 1,1 cm x 1,2 cm and moderate quantity of ascites. During the investigation, the patient evolved with a better general condition, without new episodes of vomiting, diarrhea, or abdominal pain, but started with progressive jaundice, with an increase of conjugated bilirubin. CT with intravenous contrast of the abdomen showed a considerable amount of free liquid in the abdominal cavity and a distended gallbladder with no well-defined limits at the infundibular site, highlighting a cystic formation between the gallbladder and the common bile duct, reaching near 3,3 cm (Figure 1).



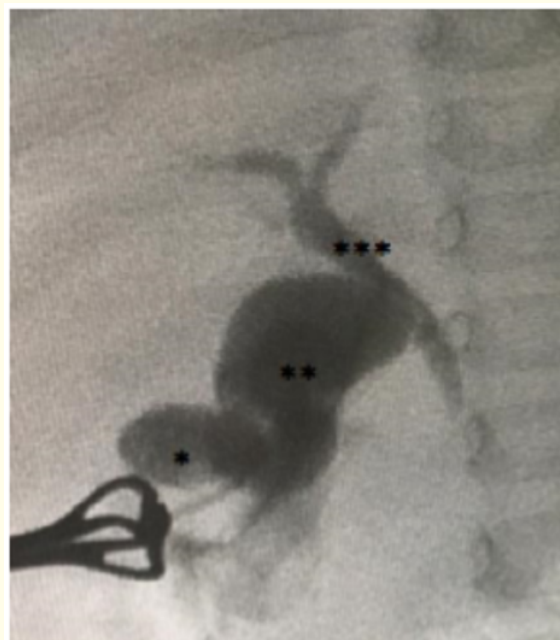**Figure 1:** A: CT scan with cystic duct cyst (\*) and cystic duct (\*\*); B: gallbladder (\*\*\*) ; C: common duct perforation (arrow sign).

We perform a diagnostic video laparoscopy and found a considerable quantity of free bile in the cavity, fibrin near the choledochus and an extensive inflammatory process over the bile ducts (Figure 2), opted for conversion to open laparotomy. We found a cystic duct cyst and perform an intra-operative cholangiography (Figure 3).

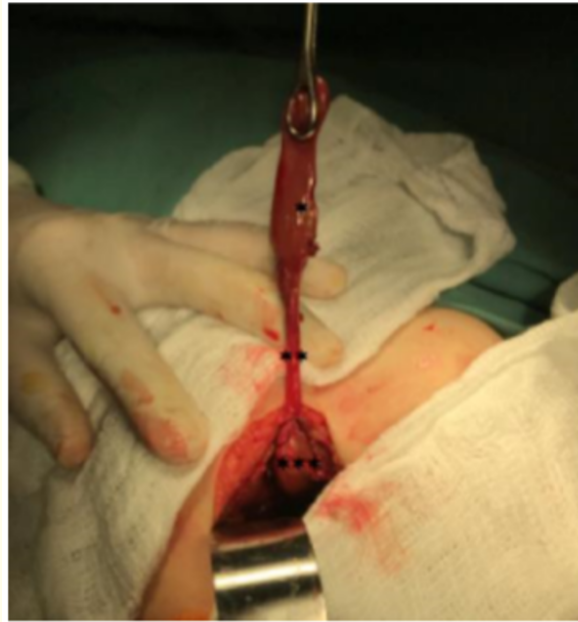During the dissection of the gallbladder, it was observed a dilated cystic formation anteriorly to the choledochus, confirmed by another cholangiography, that showed that was a segment of the cystic duct after this dilation, with usual caliber, connected to choledochus. It was also evident contrast overflow to the abdominal cavity from the proximal common hepatic duct (Figure 4 and 5).



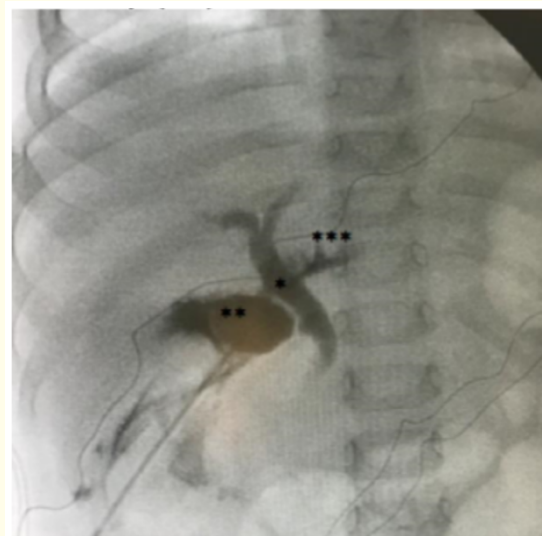
**Figure 2:** Video laparoscopy, with a large amount of fibrin on the bile duct.



**Figure 3:** Intraoperative cholangiography showing the gallbladder (\*), the cystic duct cyst (\*\*), and the bile duct.

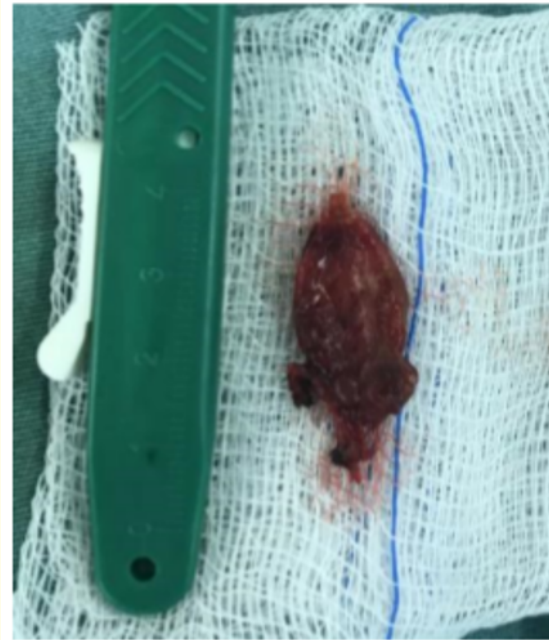

**Figure 4:** Deep cystic gallbladder dissection (\*) with long cystic duct (\*\*) and the appearance of cystic formation inside the cavity (\*\*\*).



**Figure 5:** Cholangiography after gallbladder removal with an image of the main bile duct (\*), the cystic duct cyst (\*\*) and leakage of contrast into the cavity through the perforation of the common hepatic duct (\*\*\*).

A cholecystectomy, including the cystic duct cyst, was performed (Figure 6) with the closure of common hepatic duct perforation. We drain the abdominal cavity with a tubule-laminar drain, and a Kehr drain in the choledochal duct. The post-operative was uneventful, with hospital discharge on the 10<sup>th</sup> postoperative day with the Kehr drain closed. At follow-up, we withdrew the Kehr drain at the 24<sup>th</sup> postoperative day, with the patient asymptomatic.



**Figure 6:** Cystic duct cyst.

The classic triad of biliary cysts is jaundice, pain, and a palpable mass in the right hypochondrium, present in 6 - 38% of cases. In children, it is possible to find biliary ascites due to spontaneous or traumatic perforation of these cysts, and at long term follow up, we can find about 2,5 to 39,4% of biliary carcinoma [10]. At this time, in medical

literature, there are few cases reports in infants that presented with cystic duct cyst. In our search, we achieved the following papers (Table 1). In this case report, we noted that, differently than other cases described in infants, there was ascites at first presentation, justified by the intraoperative finding of a common hepatic duct perforation in the medial position, 0.5 cm from the insertion of the cystic duct, the which again surprises us, because in the literature the most common perforation described is in the cyst wall [11].

In most cases, the cause of perforation of the common hepatic duct remains unknown. Theoretically, the etiology of this perforation includes a bile duct with intrinsic flaccidity (aganglionosis), ischemia on perforation site due to congenital vascular anomaly [12], anomalous biliopancreatic junction [13] and distal biliary obstruction due to biliary or biliopancreatic malformation [14]. The most usual site, of the biliary tree perforations, is in the junction of the cystic duct with the common hepatic duct. It makes us believe that due to the position of the cystic duct, in this case, it compressed the common hepatic duct, leading to increased pressure inside it and associated with ischemia by extrinsic compression, led to a perforation.

Author	Age	Clinical condition	Image	Subtype and Associations	Treatment
Maheshwari [12]	6 days	Jaundice, vomiting, bloating	Ultrasound and magnetic resonance cholangiography	Fusiform expansion; associated gastric perforation	Not specified
	4 months	Not specified	Ultrasound and magnetic resonance cholangiography	Fusiform expansion	Not specified
Youn., <i>et al.</i> [13]	4 months	Abdominal pain, vomiting	Ultrasound and magnetic resonance cholangiography	Fusiform expansion and anomalous junction of the pancreatic duct	Video laparoscopic cholecystectomy converted
Kotzias C., <i>et al.</i>	8 months	Abdominal pain, vomiting, jaundice, and ascites	Ultrasound and Computerized Tomography	Fusiform expansion; Perforation of common hepatic duct	Video laparoscopic cholecystectomy converted and raffia of perforation of the common hepatic duct with biliary drainage

**Table 1:** Literature review: Infant cases of cystic duct cyst.

Imaging exams assist in the diagnosis and surgical planning, and it is crucial to know the location and size of the cystic duct. At the beginning of the investigation, the abdominal US can suggest the presence of a cystic mass between the cystic duct and the gallbladder, also is capable of showing cholelithiasis and dilation of the intra and extrahepatic bile ducts [15]. The MR cholangiography is indicated for better evaluation of the dimensions of the bile ducts and differential diagnoses [15]. The difficulty of doing this exam in infants is the time to accomplish and the necessity of sedation. The retrograde cholangiopancreatography is considered the gold standard for diagnosis [15] but is not used routinely due to its invasive approach, and in the pediatric population, another difficulty is the appropriate size of the necessary material for the exam.

The cystic duct, in the adult, has a maximum diameter of 5 mm and its dilations can be saccular or fusiform, the latter being the more common variation [8]. In infants, we cannot define the standard size of the cystic duct. The treatment for this lesion is surgical excision, which not only will relieve the symptoms, but also decrease the future malignization risk [11]. Cholecystectomy with cystic duct cyst resection is the recommended procedure, but if the lesion is too close to the common hepatic duct, Ray S., *et al.* suggest, perform a biliodigestive reconstruction, for complete resection [6]. After surgery, follow-up is required because there is a risk of malignant transformation of 0,5 to 6% due to a residual lesion or subclinical neoplasm [14].

**Conclusion**

The cystic duct cyst is a rare anatomic abnormality, with difficult diagnoses, although symptomatic and relevant due to the risk of future malignancy. We believe it represents the same features of choledochal cysts and advocates a simple resection as the treatment of choice as an open or laparoscopically assisted cholecystectomy. If this malformation compromises the junction of the cystic duct with the common hepatic duct, we believe the best option would be a Roux-en-Y hepaticojejunostomy. The diagnoses can be clinically suspected, even in infants, and defined by images, despite the inherent difficulties of the patient size. We should not delay the treatment after the diagnosis and must do a close follow-up.

**Conflict of Interest**

The authors state that there is no conflict of interest related to this case report.

## Bibliography

1. Bode WE and Aust JB. "Isolated cystic dilatation of the cystic duct". *The American Journal of Surgery* 145.6 (1983): 828-829.
2. Champetier P, et al. "Cystic malformations of the cystic duct". *Surgical and Radiologic Anatomy* (1987): 287-291.
3. Serena Serradel AF, et al. "Cystic dilatation of the cystic duct: A new type of biliary cyst". *Surgery* 109 (1991): 320-322.
4. Loke TK, et al. "Choledochal cyst: an unusual type of cystic dilatation of the cystic duct". *American Journal of Roentgenology* (1999): 619-620.
5. Yamaguchi M. "Congenital choledochal cyst: Analysis of 1,433 patients in the Japanese literature". *The American Journal of Surgery* 140.5 (1980): 653-657.
6. Ray S, et al. "Isolated dilatation of the cystic duct-Type VI choledochal cyst: a rare case presentation and review of the literature". *Journal of Surgical Case Reports* 4 (2017).
7. Youn JK, et al. "Isolated cystic duct cyst with associated stones in a 4-month-old boy". *Annals of Surgical Treatment and Research* (2016).
8. Upreti L, et al. "Choledochal cyst of the cystic duct: Report of imaging findings in three cases and review of literature". *Indian Journal of Radiology and Imaging* (2015): 315-320.
9. Agha Riaz A, et al. "The SCARE Statement: Consensus-based surgical case report guidelines". *International Journal of Surgery* 34 (2016): 180-186.
10. Amarjothi JM V, et al. "Type VI Choledochal Cysts-Case Report and Review of Literature". *Surgery Journal* 05.03 (2019): e82-e86.
11. Yoon JH. "Magnetic resonance cholangiopancreatography diagnosis of choledochal cyst involving the cystic duct: Report of three cases". *The British Journal of Radiology* (2011): e018-e022.
12. Talini C, et al. "Choledochal cyst in the pediatric population: Experience of 13 laparoscopic procedures in two years at a single institution". *Revista do Colegio Brasileiro de Cirurgioes* 45.3 (2018): 1-6.
13. Maheshwari P. "Cystic malformation of cystic duct: 10 cases and review of literature". *World Journal of Radiology* 4.9 (2012): 413.
14. CJoong Kee Youn, et al. "Isolated cystic duct cyst with associated stones in a 4month-old boy". *Annals of Surgical Treatment and Research* (2016): 350-352.
15. Goya C, et al. "A Rare Anomaly of Biliary System: MRCP Evidence of a Cystic Duct Cyst". *Radiology Case Reports* (2014): 291071.

**Volume 9 Issue 8 August 2020**

**©All rights reserved by Ricardo Patino Baptista, et al.**