

Plastic Bronchitis in Children: A Review Article

Volkan Sarper Erikci*

Department of Pediatric Surgery, Sağlık Bilimleri University, Tepecik Training Hospital, Izmir, Turkey

***Corresponding Author:** Volkan Sarper Erikci, Department of Pediatric Surgery, Sağlık Bilimleri University, Tepecik Training Hospital, Izmir, Turkey.

Received: May 05, 2020; **Published:** July 29, 2020

Abstract

Plastic bronchitis (PB) is a rare disease characterized by the presence of mucofibrinous plugs which may occlude and conform the shape of tracheobronchial tree. These casts are extremely cohesive. Most common presenting symptoms include cough, fever and dyspnea and if the cohesive casts occlude the airway totally life-threatening complications and even death may occur. The aim of treatment is to remove the casts and address the symptoms. It is aimed to review the clinical and radiographic features and choices of treatment in this disease.

Keywords: Plastic Bronchitis; Children; Bronchoscopy

Introduction

Plastic bronchitis (PB) or cast bronchitis is an uncommon and often underdiagnosed entity characterized by the presence of mucofibrinous plugs which may partially or completely occlude the airways [1,2]. These casts are extremely cohesive and conform to the shape of tracheobronchial tree partially or totally (Figure 1). Cough, fever and dyspnea are the usual presenting symptoms in PB. However, if the cohesive casts occlude the significant portion of tracheobronchial tree life-threatening complications and even death may occur. The etiology of PB has not been fully clarified and the aim of treatment is to remove the casts and address the symptoms [3]. In this study it is aimed to review the clinical and radiographic features and choices of treatment in this rather rare entity under the light of relevant literature.

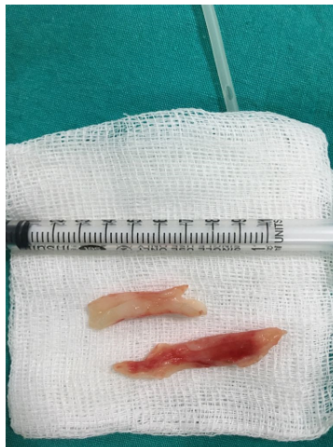


Figure 1: Macroscopic appearances of the bronchial casts removed from tracheobronchial tree.

Plastic bronchitis is a severe respiratory disorder which is characterized by the formation of extensive gelatinous bronchial casts. Sometimes these casts conform the shape of the tracheobronchial tree [2]. There is wide spectrum of presentation types including mild symptoms in one hand or life threatening disease with a mortality rate up to 60% especially in children with cardiopathies on the other [4-7].

Description of this entity was documented as early as Galen in 131-200 A.D. [8,9]. First reports of PB dates back to the early 20th century and were associated with suppurative lung infections [10,11]. It was reported that 72 patients with PB were reported before 1989 [12]. There are various classifications for casts reported in the literature. Seear, *et al.* classified bronchial casts into two histopathologic groups [13]. Type-1 casts were considered inflammatory comprising of dense fibrin structure and eosinophilia. Type-2 cases showed acellular histopathologic finding containing mucin and these cases had commonly congenital heart disease. Later Brogan, *et al.* reclassified casts depending on the disease states of asthma, cardiac and idiopathic [14]. In another further classification suggestion, the cases were categorized and expanded to cardiac, lymphatic, asthmatic and sickle-cell-related disease states [15].

The exact pathophysiology of PB is unknown. Increased pulmonary venous pressure, as seen in patients undergoing surgical intervention for Fontan procedure, may lead to abnormal response of respiratory epithelium producing excessive tenacious mucus may play a role [16,17]. Lymphatic dysfunction including elevated intrathoracic lymphatic pressure, possible lymphobronchial fistula and eventual endobronchial lymph leakage is another proposed mechanism of this disease [18]. In another proposal, it has been suggested that inflammatory process as seen in activated asthma patients would cause dysregulation of formation of mucus resulting in tenacious casts which may obstruct tracheobronchial tree [15]. Whatever the inciting mechanism, the end result is obstruction of respiratory tract partially or totally.

The prevalence of PB is unknown but a female predominance of cases has been reported [3]. Clinical spectrum of disease varies greatly. Chronic cough, dyspnea and hemorrhage and/or hemoptysis are usually observed. Wheezing is the most common finding during physical examination. If the occluding cast obstructs the airway totally catastrophic situations such as suffocation and even sudden death may be observed.

Radiographic findings are nonspecific and include atelectasis secondary to airway obstruction, hyperinflation due to air trapping, unilateral opacification, bronchiectasis and lung infiltrates (Figure 2). It has been reported that HRCT may allow in some cases the visualization of bronchial casts in the airways of larger caliber [19]. However, the gold standard in diagnosing PB is bronchoscopy which reveals the airway obstruction by BC [3].

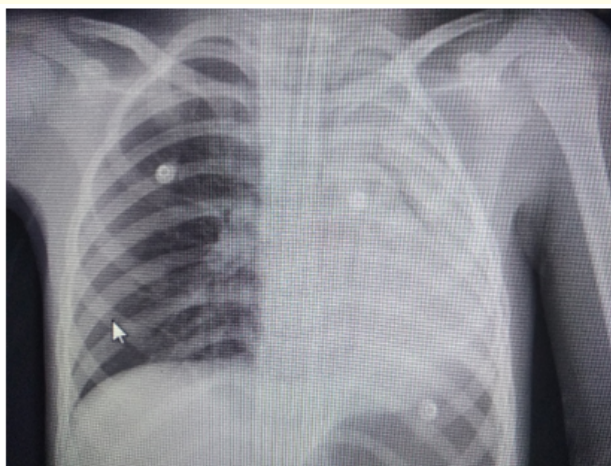

Figure 2: Chest radiograph showing left-sided opacification.

PB is usually a complication of an underlying disease and definitive therapy in these cases necessitates the treatment of this underlying condition in order to eliminate the formation of BC. Underlying diseases are depicted in table 1. It has been reported that PB is seen in children after 1 - 4% of Fontan surgery [20]. The aims of treatment in PB are to assist removal of BC from the respiratory tract of affected patients and measures to prevent and eliminate the formation of BCs. Initial management include bronchodilators, steroids, inhaled hypertonic saline, mucolytics and antibiotics. Topical fibrinolytic treatment aims to lysis of mucus plugs and removal with forced expectoration or removal with bronchoscopy. Of the topical agents reported in the treatment of these cases, inhaled heparin, urokinase, tissue plasminogen activator (tPA) act on fibrin, recombinant DNase acts on cellular material and nebulized N-acetyl cysteine acts on mucin (20). According to Brogan., *et al.* acetylcysteine has the greatest effect in dissolving these casts over DNase, urokinase and tPA [14].

Pneumonia/Eosinophilic pneumonia
Bronchiectasis
Asthma
Allergy
URI
Sickle cell acute chest syndrome
Acute myelogenous leukemia
Pulmonary lymphatic abnormalities
Pulmonary infection with Influenza A virus
Toxic inhalation (chemicals or thermals)
Systemic lymphatic abnormalities (Turner’s and Noonan’s syndrome)
Bronchopulmonary aspergillosis
Cystic fibrosis
Chronic obstructive pulmonary disease
Pericarditis
DORV with PVA
RAD
Tricuspid atresia
Tetralogy of Fallot

Table 1: Underlying diseases in patients with PB*.

*URI: Upper Respiratory Tract Infection; DORV: Double-Outlet Right Ventricle; PVA: Pulmonary Valve Atresia; RAD: Reactive Airway Disease. Adapted from Rubin BK, Moskowitz WB. 1st European Respiratory Society Handbook: Paediatric Respiratory Medicine. Plastic bronchitis. 2013; 577-81 and literatures [14,17,19]).

The use of bronchoscopy in removal of BC in patients with PB is first reported by Raghuram., *et al.* in 1997 [21]. It may be performed using flexible or rigid material. Rigid bronchoscopy has the advantage of being both diagnostic and therapeutic for removal of obstructing BC. It has been reported that if friability of plugs makes the bronchoscopic forceps removal impossible, rigid suctioning together with bronchoalveolar lavage during bronchoscopy may provide adequate cast clearance from the airways of affected patients [22].

Conclusion

In conclusion, PB is a challenge for the first liners of medical providers either in diagnosis or in treatment. Being an extremely rare and sometimes fatal disease, clinicians should have a high index of suspicion of PB in cases with right clinical setting. Prompt intervention including bronchoscopic removal of casts together with medical treatment is paramount. As our understanding of regulation of mucus production improves new treatment modalities may allow definitive therapy for patients with PB.

Bibliography

1. Walker PA., *et al.* "Treatment of plastic bronchitis using serial flexible bronchoscopy and aerosolized heparin therapy". *European Journal of Pediatric Surgery* 23 (2013): 157-160.
2. Hasan RA., *et al.* "Plastic bronchitis in children". *Fetal and Pediatric Pathology* 31 (2012): 87-93.
3. Eberlein MH., *et al.* "Plastic bronchitis: a management challenge". *The American Journal of the Medical Sciences* 335 (2008): 163-169.
4. Nayar S., *et al.* "Treatment of plastic bronchitis". *Annals of Thoracic Surgery* 83 (2007): 1884-1886.
5. Sanerkin NG and Leopold JG. "Plastic bronchitis, mucoid impaction of the bronchi and allergic bronchopulmonary aspergillosis, and their relationship to bronchial asthma". *The Annals of Allergy* 24 (1966): 586-594.
6. Bowen AD., *et al.* "Plastic bronchitis: large, branching, mucoid bronchial casts in children". *Journal of the American College of Radiology* 144 (1985): 371-375.
7. Jett JR., *et al.* "Plastic bronchitis: an old disease revisited". *Mayo Clinic Proceedings* 66 (1991): 305-311.
8. Leggat PO. "Plastic bronchitis". *Journal of Chest Diseases* 26.4 (1954): 464-473.
9. Johnson RS and Sita-Lumsden EG. "Plastic bronchitis". 15 (1960): 325-332.
10. Bettman M. "Report of a case of fibrinous bronchitis with a review of all cases in the literature". *The American Journal of the Medical Sciences* 123 (1902): 304-329.
11. Mulligan PB and Spencer RD. "Chronic fibrinous bronchitis as a symptom of mediastinal compression". *The Journal of the American Medical Association* 82 (1924): 791-792.
12. Hoskison E., *et al.* "Plastic bronchitis requiring bronchoscopy". *The Journal of Laryngology and Otology* 124.12 (2010): 1321-1324.
13. Seerer M., *et al.* "Bronchial casts in children: a proposed classification based on nine cases and review of the literature". *American Journal of Respiratory and Critical Care Medicine* 155 (1997): 364-370.
14. Brogan TV., *et al.* "Plastic bronchitis in children: a cases series and review of the medical literature". *Pediatric Pulmonology* 34 (2002): 482-487.
15. Madsen P., *et al.* "Plastic bronchitis: a new insights and classification scheme". *Paediatric Respiratory Reviews* 6.4 (2005): 292-300.
16. Silva RC., *et al.* "Endoscopic treatment of plastic bronchitis". *Archives of Otolaryngology - Head and Neck Surgery* 137 (2011): 401-403.
17. Do P., *et al.* "Successful management of plastic bronchitis in a child post Fontan: case report and literature review". *Lung* 190.4 (2012): 463-468.
18. Languopin J., *et al.* "Bronchial casts in children with cardiopathies: the role of pulmonary lymphatic abnormalities". *Pediatric Pulmonology* 28 (1999): 329-336.

19. Peixoto AO, *et al.* "Plastic bronchitis: a case report". *Global Allergy* 3.2 (2017): 22-26.
20. Singhi AK, *et al.* "Plastic bronchitis". *Annals of Pediatric Cardiology* 8 (2015): 246-248.
21. Raghuram N, *et al.* "Plastic bronchitis: an unusual complication associated with sickle cell disease and acute chest syndrome". *Pediatrics* 100 (1997): 139-142.
22. Soyer T, *et al.* "Use of serial rigid bronchoscopy in the treatment of plastic bronchitis in children". *Journal of Pediatric Surgery* 51 (2016): 1640-1643.

Volume 9 Issue 8 August 2020

© All rights reserved by Volkan Sarper Erikci.