

Intestinal Injury by Magnet Ingestion

Martin Mauricio*

Departamento de Cirugía Pedipatrica, Servicio de Cirugía Infantil, Salta, Argentina

***Corresponding Author:** Martin Mauricio, Departamento de Cirugía Pedipatrica, Servicio de Cirugía Infantil, Salta, Argentina.

Received: January 24,2020; **Published:** June 26, 2020s

Abstract

The intake of foreign bodies is a frequent entity in the population pediatric; most cases occur between 6 months and 3 years. In general, the vast majority of foreign bodies are not associated with morbi-mortality. Ingestion of 2 or more magnets can lead to obstruction, fistula formation, ulceration, perforation and volvulation of the intestine This paper presents a case registered in our institution.

Keywords: Foreign Body Intake; Magnets; Acute Abdomen; Complications

Introduction

The intake of foreign bodies is a frequent pathology in the pediatric population; In most cases, the foreign body corresponds to coins or toys, and is generally not associated with morbidity or mortality [1,2]. Most cases are between 6 months and 3 years old. In 80% of these, the foreign body will pass through the intestinal handles without complications, 10 to 20% of cases will require endoscopic extraction, and up to 1% of cases may require surgical intervention, given the presence of complications [2-9].

A complicated scenario is the ingestion of multiple magnets, which can be located in different intestinal handles and attract each other, leading to pressure necrosis of the intestinal walls and subsequently perforation [3,4,6].

Case Report

We present a medical history of a 3-year-old patient treated at Hospital Público Materno Infantil S.E. of the Province of Salta corresponding to the month of January 2020, with gastrointestinal lesions secondary to the intake of multiple magnets.

A 3-year-old patient with a history of multiple intake of magnets, rx of the abdomen is performed where there is evidence of 4 metal elements aligned within the small intestine referred to pelvic conglomerate.

An exploratory laparotomy with supra infraumbilical medial incision was performed. Cavity semiology is performed and location of foreign bodies is determined. Enterotomy and extraction of the magnets is performed. In the intestinal mucosa, a liquefied lesion is found. It is sutured. In the rest of the exam.

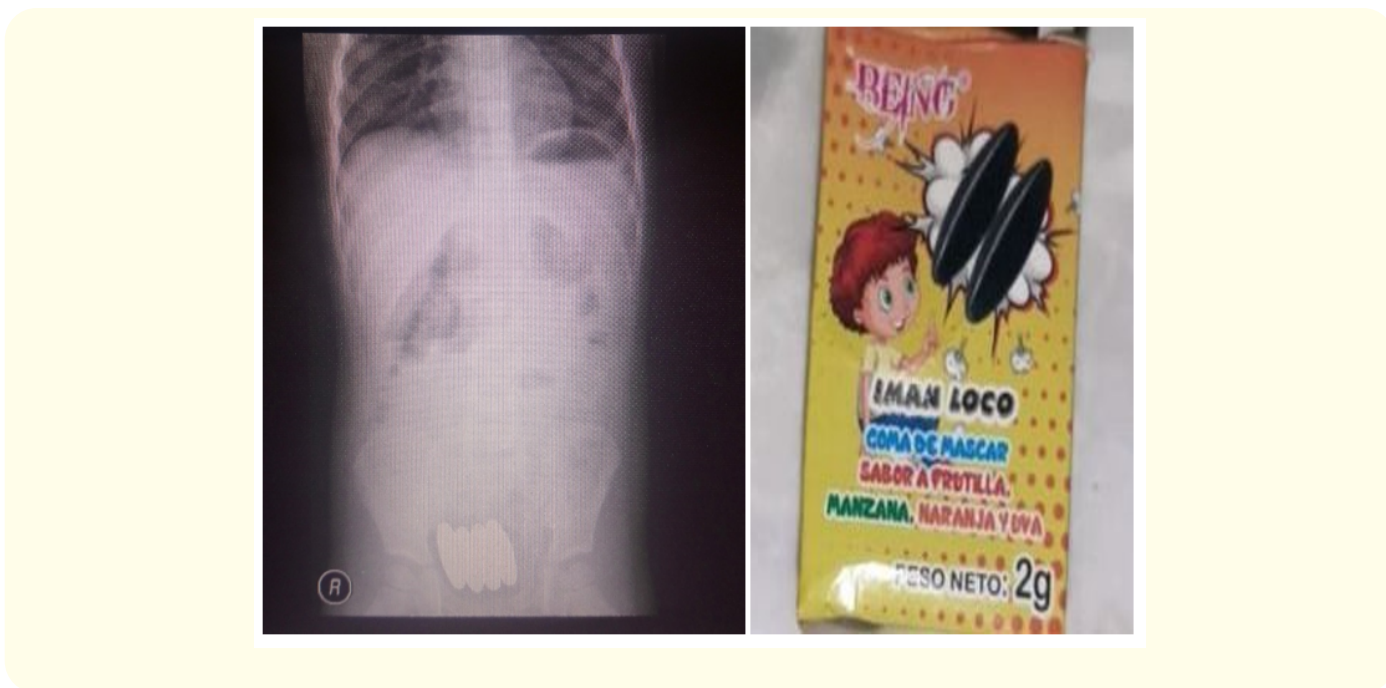
Intraoperative double gastrojejunal fistulas are evidenced on greater curvature of the stomach near the posterior aspect. And jejunal fistulas two doubles and one single. They are resected. Suture by planes. High dysfunctional jejunostomy. Patient with good clinical surgical evolution, persists in hospitalization for surgical and nutritional recovery. Waiting for surgical retransity according to evolution.

Discussion

The intake of foreign bodies in pediatric is in fact quite common in the age group [1]. Many times referred to the exploration of the environment surrounding children [3]. A large part of ingestion accidents are not detected by parents or guardians because they usually travel asymptomatic. In cases where this action is determined by parents or guardians, radiological control and depositions sufficient treatment is usually sufficient [5,6]. In symptomatic cases, high endoscopy or surgery is usually determined according to the level of digestive tract involvement [7-9].

We know of the high danger that the coin stack represents in our environment and all the faculty pay special attention to it to act quickly.

But separate issue has been the appearance of magnets in toys or other elements available to children. Even more if these can be confused with treats like in the case we present (Figure 1).



It is clear in the sporadic works published in Latin America [10] that we are at the forefront of an initiating health problem. Not so in the United States where the numbers of cases increased from 2016 to 2019 about 6 times.

Even the elimination of them is currently under discussion with a very strong reaction from the companies producing magnets [11].

According to international protocols, the presence of a single element can only be considered for expectant surgical behavior. As two magnetized elements or one magnetized and one metallic at least, it must be considered for emergency surgical behavior [12].

There are many publications where it is reported that the pathophysiology of the lesions requires the alternate intake of magnetized elements so that they are in different intestinal segments and can be attracted thus joining the intestinal walls favoring the perforation and/or fistulization of them as entities more frequent [2-6].

So would the damaging mechanism between a magnetized and a metallic element.

There are still no works that show evidence as to whether an element magnetized by itself can only generate an anatomopathological lesion defined only by its chemical composition.

Conclusion

It is evident that we are facing an incipient public health problem, which requires a deeper treatment and provision of more explicit norms regarding the new products that are included in the market for children.

The suggested protocols are simple and applicable to all health centers. Knowing the problem leads to timely specialized centers.

Bibliography

1. Kay M and Wyllie R. "Pediatric foreign bodies and their management". *Current Gastroenterology Reports* 7 (2005): 212-218.
2. Michaud L., et al. "Ingestion de corps étrangers chez l'enfant. Recommandations du Groupe francophone d'hépatologie gastroentérologie et nutrition pédiatriques". *Archives de Pédiatrie* 16.1 (2009): 54-61.
3. Gilger MA and Jain AK. "Foreign bodies of the esophagus and gastrointestinal tract in children". Upto Date (2018).
4. Wildhaber B., et al. "Ingestion of magnets: innocent in solitude, harmful in groups". *Journal of Pediatric Surgery* 40 (2005): E33-E35.
5. Fenton S., et al. "Magnetic attraction leading to a small bowel obstruction in a child". *Pediatric Surgery International* 23 (2007): 1245-1247.
6. Kircher M., et al. "Ingestion of magnetic foreign bodies causing multiple bowel perforations". *Pediatric Radiology* 37.9 (2007): 933-936.
7. Adu-Frimpong J and Sorrell J. "Magnetic toys. The emerging problem in pediatric ingestions". *Pediatric Emergency Care* 25 (2009): 42-43.
8. Berg D., et al. "Magnets in the stomach". *Journal of Pediatric Surgery* 41.5 (2006): 1037-1039.
9. Centers for Disease Control and Prevention (CDC). "Gastrointestinal injuries from magnet ingestion in children-United States, 2003-2006". *Morbidity and Mortality Weekly Report* 55 (2006): 1296-1300.
10. Butterworth J and Feltis B. "Toy magnet ingestion in children: revising the algorithm". *Journal of Pediatric Surgery* 42 (2007): E3-E5.
11. Tsai J., et al. "Ingestion of magnetic toys: report of serious complications requiring surgical intervention and a proposed management algorithm". *Permanente Journal* 17.1 (2013): 11-14.
12. Cortes C and Silva C. "Ingestion accidental de imanes en niños y sus complicaciones: Un riesgo creciente". *Revista Médica de Chile* 134 (2006): 1315-1319.

Volume 9 Issue 7 July 2020

©All rights reserved by Martin Mauricio.