

Is Laparoscopy Orchidopexia a Good Option in Canalicular Testicular Cryptorchidism Patients? Experience in Hospital General Occidente, Guadalajara, Jal. Mexico

Gallardo Meza Antonio Francisco*, González Sánchez José Manuel, Vidrio Patrón Francisco, Espinosa Jiménez Hermelinda, Murguía Guerrero Humberto, Cantoral Uriza Humberto, Vázquez Jackson Humberto, Elizabeth López Villalobos and Jessica Santoyo Cueva

Department of Pediatrics and Pediatric Surgery, Hospital General de Occidente, Guadalajara, Jalisco, México

***Corresponding Author:** Gallardo Meza Antonio Francisco, Department of Pediatrics and Pediatric Surgery, Hospital General de Occidente, Guadalajara, Jalisco, México.

Received: August 29, 2019; **Published:** October 25, 2019

Abstract

Introduction: Cryptorchidism has a prevalence of 1 - 2% in the general population. Of these, 20% are non-palpable or intra-abdominal testicles. In 1992 Jordan, *et al.* introduced laparoscopy as a diagnostic method in patients with non-palpable testicles, it is currently the treatment of choice intra-abdominal testicles. In 1995 Docimo, *et al.* applied the laparoscopic technique for canalicular testicles, like Riquelme, *et al.* in 2009, and Escárcega, *et al.* in 2011, with 100% successful testicular descent.

Materials and Methods: We studied 182 patients all underwent laparoscopic orchidopexy. The surgical technique is widely described.

Results: 45 orchidopexy were bilateral (90 units) and 137 unilateral (70 right and 67 left), giving a total of 227 testicles operated. Of these, 41 testicles were intra-abdominal and 186 canalicular. The follow-up of 182 patients varies from 6 days to 8 years. According to the Beltrán Brown classification, of 186 channels, 98 are size A, 64 B and 24C. Of the 41 abs, 15 are size A; 14 B, and 12 C. 17 cases had orchiectomy because the testicle was completely atrophic in the abdominal cavity. Surgical time was 60 minutes (unilateral) and 90 minutes (bilateral). With the increase in the learning curve, time was reduced to 35 - 40 minutes (unilateral) and 50 - 60 minutes (bilateral).

Conclusions: We think that laparoscopic orchidopexy is the method of choice as a treatment for cryptorchidism, not only intra-abdominal but also for the canalicular, according to the results presented.

Keywords: Orchidopexy; Laparoscopy; Cryptorchidism

Introduction

Cryptorchidism occurs in newborn children in 3-5% of cases, in the vast majority there is a spontaneous decrease around the first two years, leaving a prevalence of true cryptorchidism in 1 - 2% of the general population, of these 20% corresponds to non palpable or intra-abdominal testicles, and the rest to canalicular testicles [1,2]. There is no ideal study to locate the intra-abdominal testicles. Tomography, ultrasound, and magnetic resonance imaging have not proven to be a suitable method to locate the intra-abdominal testicles [3].

Citation: Gallardo Meza Antonio Francisco, *et al.* "Is Laparoscopy Orchidopexia a Good Option in Canalicular Testicular Cryptorchidism Patients? Experience in Hospital General Occidente, Guadalajara, Jal. Mexico". *EC Paediatrics* 8.11 (2019): 1111-1116.

In 1992 Jordan and Cols introduced laparoscopy as a diagnostic method in patients with non-palpable testicles [4,5]. Although a year earlier, pelviscopy had been used for ligation of sperm vessels as the first stage of the Fowler Stephens technique [6]. Since then, the management of laparoscopic cryptorchidism, especially in patients with non-palpable (intra-abdominal) testicles has changed radically; initially, it was used as a diagnostic tool to locate the intra-abdominal testicles, obtaining greater precision for its location and defining the canalicular testicles. By the end of the 90s and the beginning of 2000, laparoscopy was used to apply the Fowler Stephens technique in one or two stages, with an increase in success rates of up to 70 - 80%, and later it was also used to do extensive dissections of sperm vessels, noting that in the vast majority of cases the descent of the gonad to the scrotum was achieved with success rates much higher than those obtained with other procedures [7]. At present, laparoscopic orchidopexy has become the treatment of choice in the management of intra-abdominal testicles [8]. In 1995 Docimo., *et al.* applied the laparoscopic technique for canalicular (palpable) testicles but in very high testicles located in the inguinal canal, practically in the deep inguinal ring [9]. Riquelme., *et al.* in 2009 [10] and Escárcega., *et al.* In 2011 [11] published orchidopexy laparoscopic in canalicular (palpable) testicles, regardless of its location in the inguinal canal, with 100% successful testicular descent.

Objective of the Study

To show the experience of the use of the laparoscopic technique in intra-abdominal testicles and mainly in canalicular testicles, located anywhere in the inguinal canal, with or without associated inguinal hernia.

Materials and Methods

We reviewed a total of 182 patients with true cryptorchidism undergoing laparoscopic orchidopexy, of which all underwent a study protocol where parents are explained that cryptorchidism can be operated in two ways: one with open technique and the other with laparoscopic technique, the advantages, risks and disadvantages of each of the techniques are explained, thus obtaining informed consent. The laparoscopic surgical technique consists of inserting 3 ports of 5 mm. The first is placed at the level of the umbilical scar with Hasson's technique, for the optics of 5 mm and 30°; and the remaining ones are placed level of the external clavicular line at the height of the umbilical scar one on each flank for the work items. With a CO₂ insufflation of 8 to 10 mmHg depending on the patient's age. The inguinal region is identified, and it is checked for intra-abdominal or canalicular testicle and it is recorded if there is an associated inguinal hernia. In both cases, dissection of the spermatic vessels and the vas deferens begins, separating them from the posterior peritoneum, circumcising the peritoneum that surrounds the deep inguinal ring, separating the cord elements of the posterior peritoneum, and an extensive dissection of the spermatic vessels is made, until near their emergence of the renal vein in case of treating the left side or the great vessels in the cases of the right side. In those intra-abdominal testes, the gubernaculum test is identified, and sectioned with a ligasure clamp, as far as possible from its attachment to the testicle. In canalicular cases, the testicle is introduced into the abdominal cavity by pulling it from the hernia sac, once it has been introduced into the abdominal cavity, the gubernaculum is linked in the same way as is done in the intra-abdominal cases. Once the testicle is released into the cavity, it is carried towards the contralateral deep inguinal ring. If when performing this maneuver the testicle arrives easily it is an indication that the testicular descent will reach the ipsilateral scrotum without setbacks.

Subsequently, the neo-canal is performed, using blunt dissection between the umbilical ligament and the epigastric vessels, continuing to touch the pubis, once the pubis is identified, a clamp is inserted above it, which easily reaches the scrotal cavity the clamp is exposed through the skin of the scrotum, and an umbilical tape is taken. The laparoscopic clamp is returned to the abdominal cavity and completely removed from the port until the tape is recovered outside the trocar. A Kelly clamp is placed on the scrotal end of the tape and pulled into the abdominal cavity. Once the Kelly clamp has been recovered in the abdominal cavity, the neo-laparoscopic canal is enlarged, and the gubernaculum is taken with Kelly's clamp, lowering the testicle to the scrotum and fixing the Dartos testicle in the traditional way. Finally, hemostasis is checked. In the area of the neo canal and the primitive inguinal canal, no closure is performed.

Results

45 cases were bilateral (90 units) and 137 unilateral (70 right and 67 left), which gives a total of 227 testicles operated. Of these, 41 testicles were intra-abdominal and 186-channel (Figure 1 and 2).

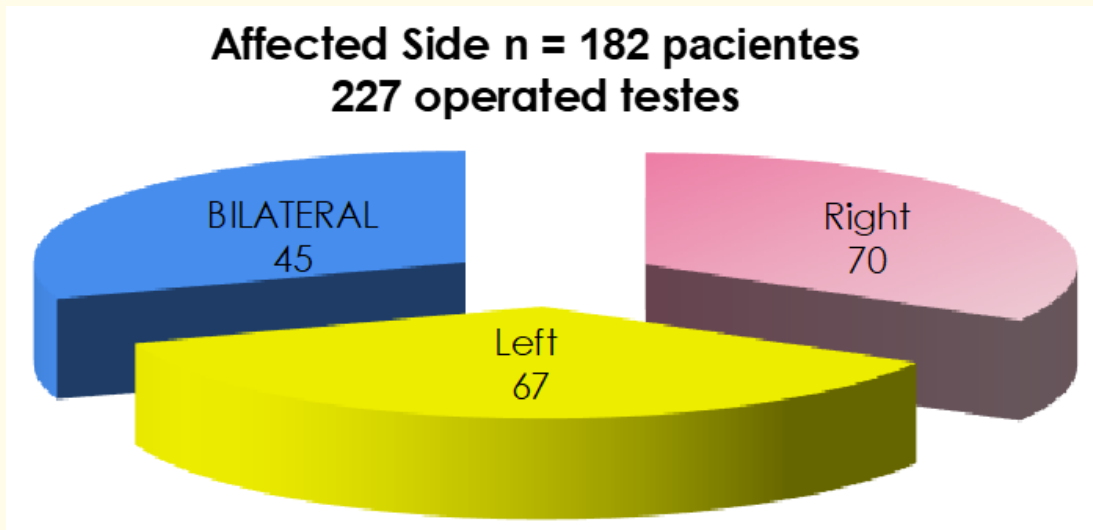


Figure 1

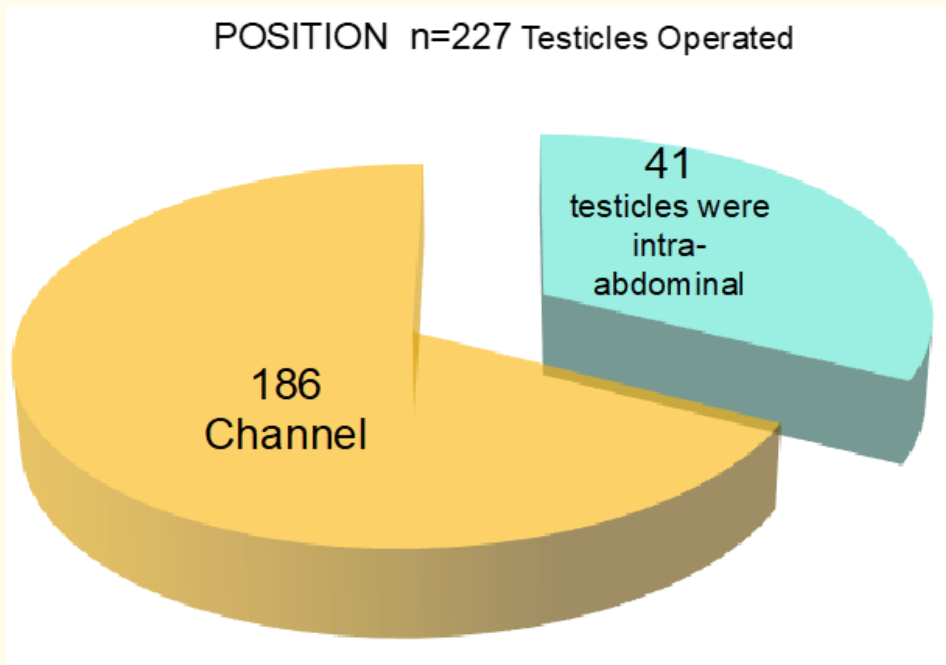


Figure 2

The age range of the operated patients was distributed as follows: Six were under 1 year old; 87 between 1 - 3 years; 30 between 3 - 5 years old, 53 between 5 - 10 years old, and six were older than 10 years old, having a peak incidence of 67.58% in children under 5 years (Figure 3).

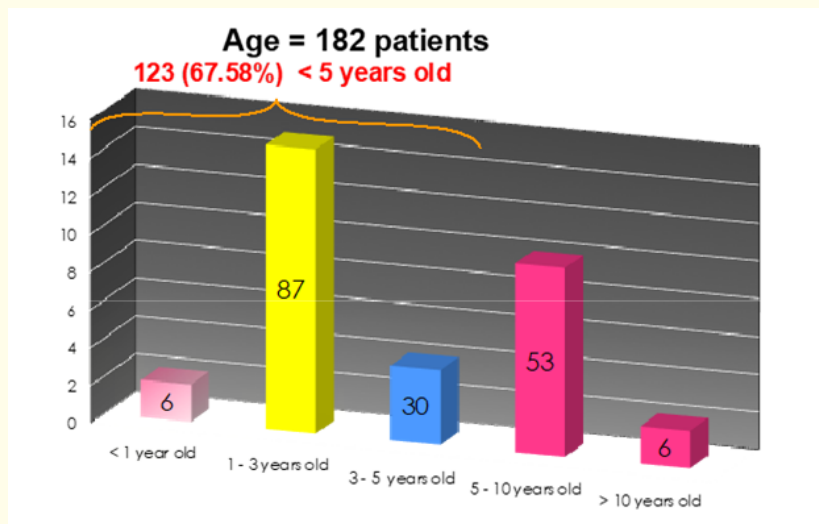


Figure 3

The follow-up of 182 patients, (227 operated testicular units), varied from 6 days to 8 years with an average follow-up of 4 years in total.

The position and size of the testicle after surgery and according to the Beltrán- Brown classification, were distributed as follows: Of the 186 canalicular testicles 98 are inside scrotum with size "A" (equal to the contralateral), 64 is intrascrotal with a size "B" (25% less than the contralateral), and 24 more also within the scrotum with a size "C" (50% smaller than the contralateral). Of the 41 abdominals all are intrascrotal, 15 are with an "A" size; 14 with size "B", and 12 cone size "C". The missing 17 cases required orchiectomy for presenting atrophic testis in the abdominal cavity (Figure 4).

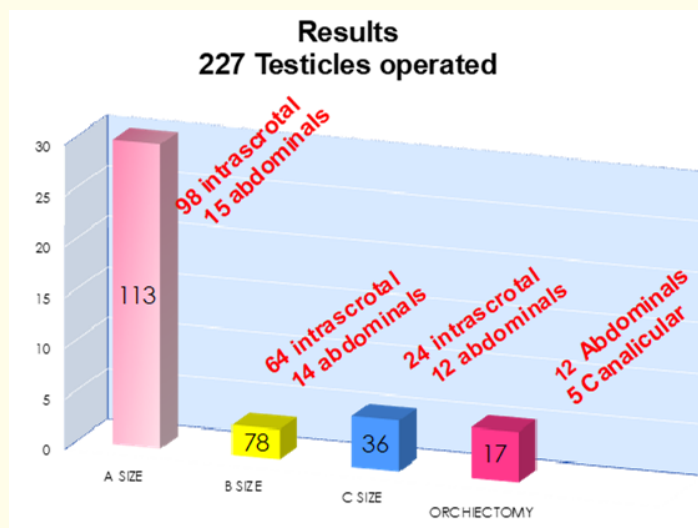


Figure 4

From the point of view of the surgical time the first cases consumed an approximate time of 1 hour; for the unilateral testicles and about 90 minutes for the bilateral ones. With the increase in the learning curve, the time was reduced to 35 - 40 minutes for the unilateral and 50 - 60 minutes for the bilateral.

There were no major complications, in one case it had to be converted by a viscera perforation when introducing one of the ports, and in another one, the defender was accidentally sectioned, both complications are not included in the case, however, it is convenient mention them.

Discussion

In this study we found, like most authors [2,10,11], the laparoscopic approach is the method of choice in all patients with intra-abdominal testes. In all 41 cases of intra-abdominal testis, it was possible in all to take the gonad to the scrotal bag, by means of a very extensive dissection of the spermatic vessels by this route. It should be mentioned that, by passing them through the neo-canal, the natural curvature that the vessels make when entering through the deep inguinal ring is removed, so there was no need to apply the Fowler Stephens technique. On the other hand, a higher incidence of testicular atrophy was found in the intra-abdominal testicles, having to perform orchiectomy in 17 cases.

In the canalicular testicles, the testicle was also lowered to the scrotal bag with very good results since 90% of these patients at a follow-up of 6 days to 8 years, have an "A" size. A case "B" and two "C". These last three cases were smaller from the moment of surgery. Like other authors such as Riquelme and Escárcega, we think that the laparoscopic approach to the canalicular testicles, regardless of the height of the canal, can be operated laparoscopically and with excellent results.

Conclusion

The laparoscopic approach for patients with cryptorchidism is a good option for testicular descent, regardless of its height. Based on the results reported as well as those reported by other authors such as Riquelme and Escárcega, it is considered that the canalicular (palpable) testicles, the laparoscopic approach should be considered the first choice to carry out the testicular descent; with the advantages for the patient of suffering less postoperative pain, an aesthetically favorable appearance, and with excellent results.

Bibliography

1. Berkowitz GS., *et al.* "Prevalence and natural History of cryptorchidism". *Pediatrics* 92.1 (1993): 44-49.
2. Nieto J and Ordorica RM. "Orquidopexia laparoscópica en testículo no descendido de localización intra-abdominal". *Revista Mexicana de Cirugía Endoscópica* 2.4 (2001): 181-184.
3. Frieland GW and Chang P. "The role of imaging in the management of the impalpable undescended testis". *American Journal of Veterinary Research* 151.6 (1998): 1107-1111.
4. Cortesi N., *et al.* "Diagnosis of bilateral abdominal cryptorchidism by laparoscopic". *Endoscopy* 8.1 (1976): 33-34.
5. Jordna GH., *et al.* "Laparoscopic Surgical management of the abdominal/transinguinal undescended testicle". *Journal of Endourology* 6.2 (1992): 159.
6. Bloom DA. "Twostep orchiopey pelvioscopic clip ligation of the spermatic vessels". *Journal of Urology* 145.5 (1991): 1030-1033.
7. Tejedor R., *et al.* "Indicaciones, Técnica y resultados de la Orquidopexia laparoscópica en un solo tiempo". *Cirugia Pediatrica* 21 (2008): 191-194.
8. Hamidina A., *et al.* "Localisation of non-palpable testes". *Surgery, Gynecology and Obstetrics* 159 (1984): 439.

9. Docimo SG., *et al.* "Laparoscopic Orchiopexy for the high palpable undescended testis preliminary experience". *Journal of Urology* 154.4 (1995): 1513-1515.
10. Riquelme MA., *et al.* "Orquidopexia laparoscópica en el testículo no descendido, palpable y no palpable". *Revista Mexicana de Urología* 69.5 (2009): 215-218.
11. Escárcega P., *et al.* "Orchiopexy laparoscopic or Traditional Surgical Technique in Patients with an Undescended Palpable Testicle". *Journal of Laparoscopic and Advanced Surgical Techniques* 21.2 (2011): 185-187.

Volume 8 Issue 11 November 2019

©All rights reserved by Gallardo Meza Antonio Francisco., *et al.*