

Giant Hydroureteronephrosis due to Idiopathic Ureterovesical Junction Obstruction: A Case Report and Review of Literature

Volkan Sarper Erikci* and Tunahan Altundağ

Department of Pediatric Surgery, Tepecik Training Hospital, Sağlık Bilimleri University, Izmir, Turkey

***Corresponding Author:** Volkan Sarper Erikci, Department of Pediatric Surgery, Tepecik Training Hospital, Sağlık Bilimleri University, Izmir, Turkey.

Received: March 25, 2019; **Published:** August 28, 2019

Abstract

Ureterovesical junction obstruction is a rare but important cause of hydroureteronephrosis in childhood. A 2-year-old boy suffered from giant hydroureteronephrosis originating from idiopathic ureterovesical junction obstruction. He was treated with excision of narrow ureteric segment with tapering ureteroplasty and a ureteral reimplantation was performed. This case is presented and discussed with reference to etiology of this rather rare anomaly.

Keywords: *Hydroureteronephrosis; Ureterovesical Junction Obstruction; Children*

Introduction

Congenital ureterovesical junction obstruction (UVJO) may be observed during fetal age or any stage at the time of childhood. It is aimed in this report to present a male child with obstructive megaureter due to congenital UVJO. He was surgically treated with excision of narrowed distal ureter in addition to tapering ureteroplasty with ureteroneocystostomy. The topic is discussed with special reference to the etiology of this rather rare entity under the light of relevant literature.

Case Report

A 27-month-old boy was admitted to our department with an antenatal history of right hydroureteronephrosis (HUN). Laboratory tests were otherwise normal except signs of urinary tract infection (UTI) including leucocyturia. The microbiological urinalysis was positive for UTI revealing *E. coli* 10⁵ CFu/mL. Urinary ultrasonography revealed an enlargement of the right kidney, pelvis and a megaureter with tortuosity down to the urinary bladder. Scintigraphy using dimercaptosuccinic acid (DMSA) and dimercaptopentetic acid (DTPA) showed a dilated right kidney with reduced scintigraphic uptake revealing a differential renal function of 41% for the right and 59% for the left kidney with signs and findings showing UVJO. Magnetic resonance imaging (MRI) showed enlargement of the right kidney with marked reduction of the cortical thickness, an enlarged pelvis and huge dilatation of right ureter with tortuosity down to the bladder (Figure 1). Due to progressive worsening of the upper urinary tract function and repeated UTIs, surgical intervention became a necessity rather than of choice. Surgical intervention revealed a severely narrowing of the right distal ureter for 2 cm in accordance with UVJO resembling bird's beak and the diameter of the ureter proximal to UVJO was measured nearly 4 cm (Figure 2). Excision of the distal ureter and a segment of megaureter with a tapering ureteroplasty of the proximally dilated megaureter for a length of 10 cm around an 8 Fr feeding tube and reimplantation using Politano Leadbetter technique was subsequently performed (Figure 3). The urinary bladder was drained via 8 Fr silicone foley catheter. Postoperatively he did well with no episode of pain, nausea or vomiting. On the second postoperative day, the patient started oral feedings and was discharged home in good condition.

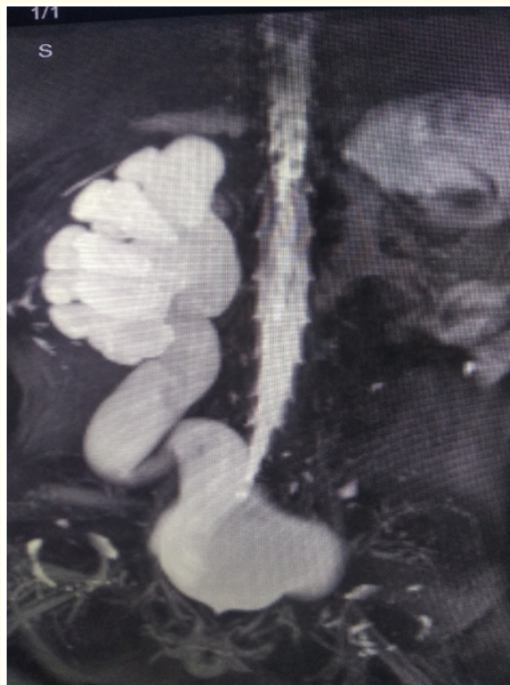


Figure 1: MRI showing the enlargement of the right kidney with reduction of cortical thickness and giant pelvis and ureter just before the ureterovesical junction.

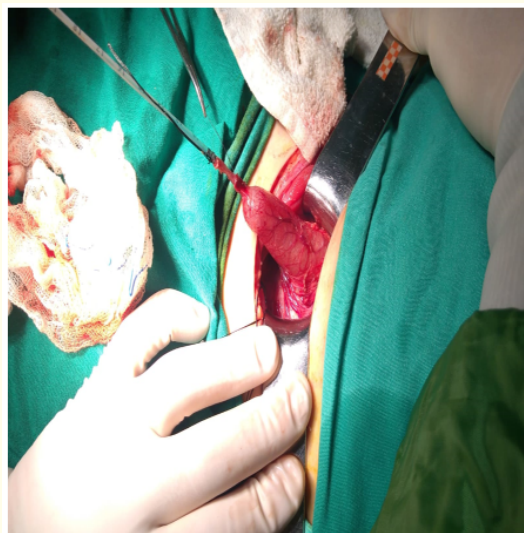


Figure 2: Operative view showing marked narrowing of the right distal ureter with dilation of the proximal ureter with tortuosity (Note 5 Fr catheter inside the ureter).

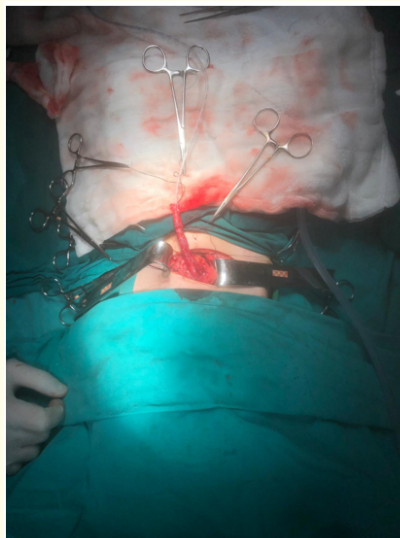


Figure 3: Operative view showing distal part of right ureter after tapering ureteroplasty around a 8 Fr catheter before reimplantation.

Discussion

As a cause of hydronephrosis in newborns, megaureter accounts for approximately 20% of cases and occurs bilateral in 15 - 25 of patients [1]. Ureteral dilatation can be classified into four categories and these are namely non-refluxing non-obstructed ureter, refluxing non-obstructive ureter, refluxing obstructive ureter and non-refluxing obstructive ureter. Diagnostic work-up performed in our case did not reveal vesico-ureteral reflux and so our patient can be classified as non-refluxing obstructive ureter. It has been reported that of the 27% of pediatric patients with kidney failure due to obstructive uropathy, obstructive megaureter accounts for 3.5% of cases [2,3]. Fortunately, due to rather normal findings in the left kidney and ureter, no kidney failure was observed in our case.

Among different etiologic factors in HUN, primary UVJO is rare and frequently associated with an aperistaltic segment of the distal ureter at the UVJ. Most of these cases can be detected during antenatal ultrasound screening of urinary tract [4,5]. Prenatal ultrasonography also revealed HUN in our case during routine follow-up. It is likely that most of these patients with primary UVJO show symptoms during childhood. Although the age of our patient was found to be within the limits of infancy period, surgical treatment was performed in our case since there was reduced scintigraphic function with repeated UTIs positive for *E. coli* and severe hydronephrosis (> 30 mm).

The etiology of primary UVJO is unclear. The transportation of urine at the UVJ occurs by means of peristalsis of the circular outer and longitudinal inner layers of muscles [6]. It has been postulated that increase in collagen and hypertrophy of the circular muscle and atrophy of the inner muscle may be responsible for the deterioration of urine flow at the UVJ [7-11]. It has been hypothesized that, with a resemblance to the gastrointestinal system, urinary tract obstructive disorders might be related with the aplasia or hypoplasia of the interstitial cells of Cajal (ICC) [12]. In a recent study by Kart and co-workers, it was shown that the number of ICC was decreased in the UVJ of the patients with primary obstructive megaureters compared to the normal control group [6]. Histological analysis in our patient revealed fibrosis of tissues removed at surgery.

Conclusion

In conclusion, UVJO is a rare but important cause of HUN in children and may occur at any stage during childhood. It is commonly associated with UTIs and deterioration of upper urinary tract. Timely and accurate management of this entity is important for the preser-

vation of upper urinary tract function. The health providers dealing with such kinds of patients should keep this anomaly in mind and a prompt pediatric surgical consultation is recommended and the patient should be treated accordingly.

Bibliography

1. Hinds AC. "Obstructive uropathy: considerations for the nephrology nurse (Continuing Education)". *Nephrology Nursing Journal* 31.2 (2004): 166-174.
2. Ardissino G., et al. "Epidemiology of chronic renal failure in children: data from the ItalKid Project". *Pediatrics* 111.4 (2003): 382-387.
3. Kaya C., et al. "A rare case of an adult giant hydroureteronephrosis due to ureterovesical stricture presenting as a palpabl abdominal mass". *International Urology and Nephrology* 37.4 (2005): 681-683.
4. Oliveira EA., et al. "Primary megaureter detected by prenatal ultrasonography: conservative management and prolonged follow-up". *International Urology and Nephrology* 32.1 (2000): 13-18.
5. Becker A and Baum M. "Obstructive uropathy". *Early Human Development* 82.1 (2006): 15-22.
6. Kart Y., et al. "Altered expression of interstitial cells of Cajal in primary obstructive megaureter". *Journal of Pediatric Urology* 9.6 (2013): 1028-1031.
7. Escala JM., et al. "Development of elastic fibres in the upper urinary tract". *Journal of Urology* 141.4 (1989): 969-973.
8. Gosling JA and Dixon JS. "Functional obstruction of the ureter and renal pelvis: a histological and electron microscopy study". *British Journal of Urology* 50.3 (1978): 145-152.
9. Hanna MK., et al. "Ureteral structure and ultrastructure. Part III. The congenitally dilated ureter (megaureter)". *Journal of Urology* 117.1 (1977): 24-27.
10. Nicotina PA., et al. "Segmental up-regulation of transforming growth factor-beta in the pathogenesis pf primary megaureter. An immunocytochemical study". *British Journal of Urology* 80.6 (1997): 946-949.
11. Notley RG. "Electron microscopy of the primary obstructive megaureter". *British Journal of Urology* 44.2 (1972): 229-234.
12. Solari V., et al. "Altered expression of interstitial cells of Cajal in congenital ureteropelvic junction obstruction". *Journal of Urology* 170.6 (2003): 2420-2422.

Volume 8 Issue 9 September 2019

©All rights reserved by Volkan Sarper Erikci and Tunahan Altundağ.