

Kummoona Auricular-Cervical Flap, New Technique for Reconstruction of Helix and Antihelix of the Ear

Raja Kummoona*

Emeritus Professor of Maxillofacial Surgery, Iraqi Board for Medical Specialization's, Baghdad, Iraq

***Corresponding Author:** Raja Kummoona, Emeritus Professor of Maxillofacial Surgery, Iraqi Board for Medical Specialization's, Baghdad, Iraq.

Received: November 09, 2018; **Published:** December 27, 2018

External ear arises from tissue derived from the first and second branchial arches, errors in their development are origin of accessory auricle, sinuses or congenital defect as in First arch dysplasia syndrome.

The ear defect is one of the most difficult area of the face to be reconstructed of partial large defect of the ear as result of traumatic injuries by missile war shell or missing of helix and antihelix by road traffic accident (RTA) or by radical excision by cancer surgery, small defect with wedge resection of small tumor as small triangular defect by direct closure may give satisfactory results but large defect required flap surgery.

Many techniques advocated for reconstruction or correction of helical margin and antihelix area such as post auricular, mastoid, cervical or composite flaps, gave less satisfactory results from cosmetic point of view.

Our aim is to produce a good cosmetic results; reconstruction of the ear is a difficult task required expertise, skill and knowledge because of intricate nature of chondro-cutaneous sandwich that give the delicate configuration of the auricle.

Flap is a mass of tissue contain or composed from skin, sub-cutaneous tissue and muscle, and they are two types Axial pattern flap with good arterial and venous supply or Random flap based on capillaries blood supply and they are local flaps of donor tissue obtained from area surrounding the defect and to be an ideal solution or regional flap or distant flap like tube pedicle [1,2].

Anatomy of the ear

We described briefly anatomy of the ear to understand the technique to be used in this clinical work or research.

The skin of the ear is thin, shiny and pale it adhere closely to the underlying cartilage on anterior aspect until helical rim then the skin become pink, soft and matt in texture. From superior to inferior aspect along the rim, the mount of subcutaneous tissue and excess of skin increased, the blood vessels are abundant.

The muscular structures consist of extrinsic and intrinsic muscles. Extrinsic muscles are auricularis anterior, superior and posterior; intrinsic muscles are helices major, helices minor, tragic us, antitragi us, transverse auricular and oblique auricular.

The motor supply from temporal branches and post auricular branches of Facial nerve. Sensory nerve from greater auricular and lesser occipital nerves from cervical plexus, auriculotemporal branch of mandibular nerve and auricular branch of vagus nerve.

The blood supply of the ear are from post auricular branches of external carotid and anterior auricular branches of superficial temporal and from branches of occipital artery and the veins from external jugular vein, lymphatic drain to upper deep cervical lymph nodes and mastoid nodes for all margin of the ear and posterior wall of external auditory meatus. Ear lobe and other structures drain to superficial cervical lymph nodes.

There are two options of flap reconstruction of helix and anti-helix successfully been used?

1. **Post auricular flap designed by Ian Jackson 1985:** As two stage operations, the bulk of the flap allow total reconstruction without necessary cartilage graft, flap planning based on edges of hairline, the breadth of the flap is equal to defect, the length is such that to reconstruct both anterior surface, rim and posterior surface. It may require tube of silicon to be placed under the flap it attached to ear skin [3].
2. **Kummoona Auricular-Cervical flap, 2017:** This flap is one stage operation, superiorly based flap, axial pattern flap no cartilage graft to cover the large defect of the rim of helix antihelix, the flap able to reconstruct both the anterior surface and posterior surface of the ear, no silicon tube required, the color of the flap matching the color of the ear and cosmetically very acceptable.

Flap design

Two parallel incisions one extend from lower mastoid anterior to stern mastoid muscle down to cervical area about 10 cm length and another incision anterior to it about 4cm extend to same length, the two incision joined together by lower transverse incision, the flap dissected from lower part as full thickness of skin, fascia and superficial muscle fibers of stern mastoid muscle.

Malignant Tumor of Helix and prehelix excised with safety margins as full thickness of the ear, the flap is superiorly based pedicle dissected with arc of rotation of 90 o to reconstructs first the margins of prehelix and helix rim and posterior part of the ear, the cervical incision closed by primary closure after under mining the skin by silk. After 10 days sutures removed and patient kept under Ceftriaxone 1 gm daily for 8 days.

Our flap proved much superior than post auricular flap, as one stage operation, with one day hospitalizations, the color of the flap match the color of the ear.

The blood supply is from posterior auricular and from superficial branch of the occipital arteries with rich blood supply.

The aim of this work is to share our colloquies worldwide our experience in managements of this type of defect and the flap can be applied in traumatic defect of the ear in children by car accident or other trauma.

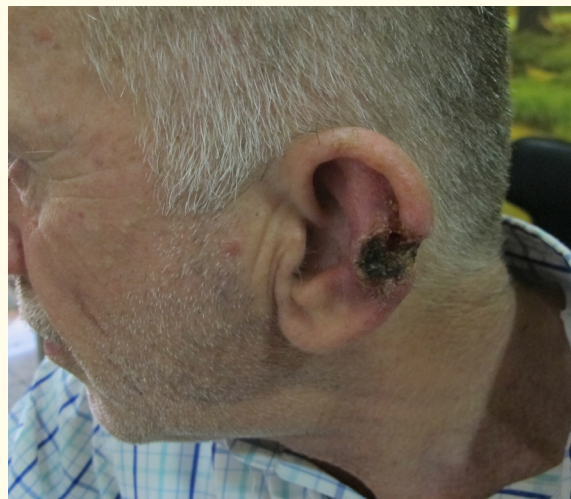

Figure 1: 55 year man with basal cell carcinoma transformed to squamous cell carcinoma of the ear.

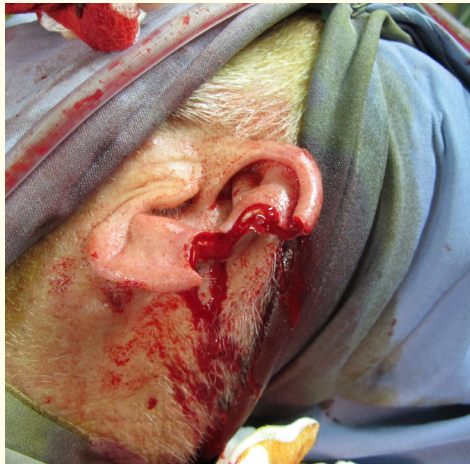

Figure 2: Radical excision of malignant tumor.

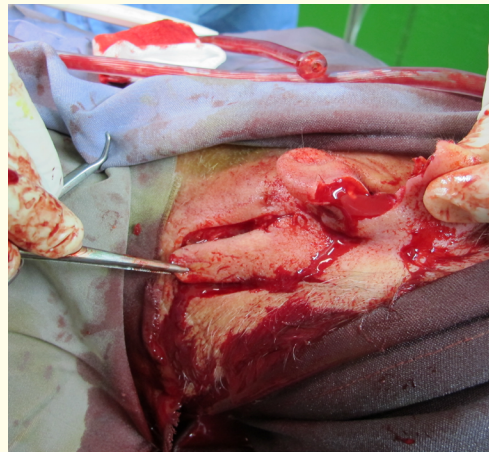


Figure 3: Design of Kummoona of auricular cervical flap.

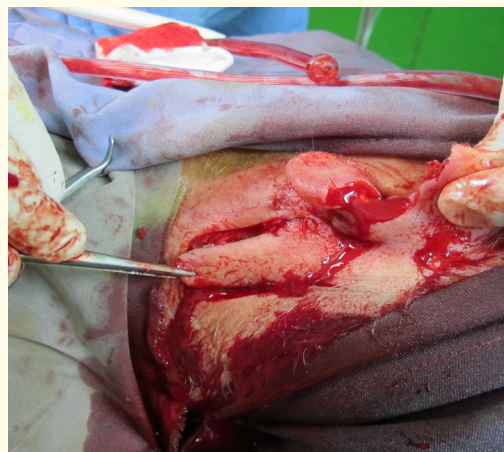


Figure 4: Auricular Cervical flap mobilized for reconstruction of the defect of ear.

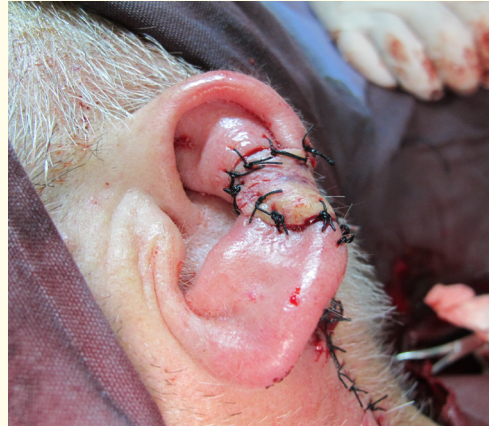

Figure 5: Flap reconstructed the helix and pre helix and posterior surface of the ear.

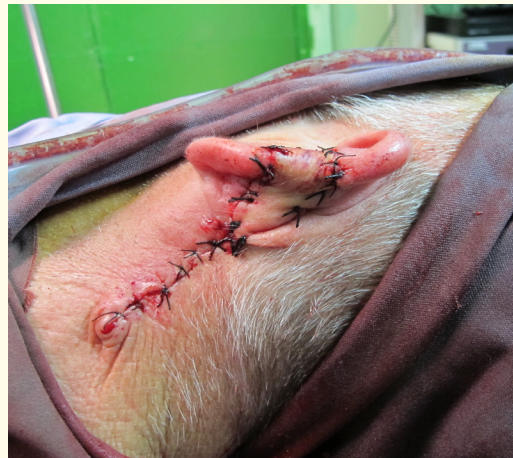

Figure 6: Specimen of malignant basal cell transformed to squamous cell carcinoma.

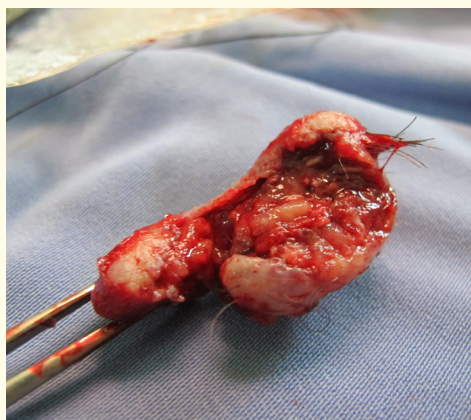

Figure 7: Three months Post-operative of reconstruction by Kummoona auricular cervical flap of the ear.

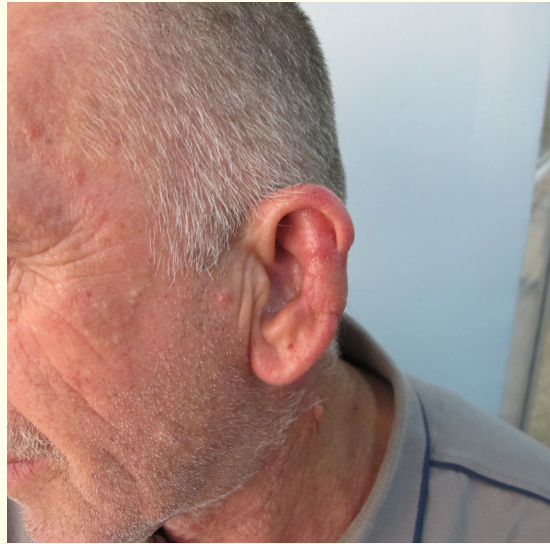

Figure 8

Bibliography

1. Kummoona R. "The use of lateral cervical flap in reconstructive surgery of orofacial region". *International Journal of Oral and Maxillofacial Surgery* 23.2 (1994): 85-89.
2. Kummoona R. "Reconstruction by lateral cervical flap of perioral and oral cavity, Clinical and experimental studies". *Journal of Craniofacial Surgery* 21.3 (2011): 660-665.
3. Jackson TI. "Local Flaps in Head Neck Reconstruction". Mosby, ST. Louis (1985).

Volume 8 Issue 1 January 2019

©All rights reserved by Raja Kummoona.