

Treatment of the Mouth Breather with Changes on the Occlusion and Body Posture Problems through the Human Body Total Care Method - Aragão Function Regulator (HBTC-RFA): A Case Report

Baruhm Margareth*

Specialist in Pediatric Dentistry, University of Santo Amaro, São Paulo, Brazil

***Corresponding Author:** Baruhm Margareth, Specialist in Pediatric Dentistry, University of Santo Amaro, São Paulo, Brazil.

Received: December 03, 2018; **Published:** December 26, 2018

Abstract

This article intends to show how the technique of the Human Body Total Care Method - Aragão Function Regulator (HBTC-RFA) works on the treatment of malocclusion, body posture and craniocervical posture on the proposed clinical case.

Keywords: Mouth Breather; Head Posture; HBTC-RFA

Introduction

Breathing is one of the main functions of the body, and happens physiologically through the nose, providing growth and the normal development of the craniofacial complex. The mere mechanical obstruction of the air passage is enough for the individual to initiate mouth breathing, in an effort to maintain their vital functions [1].

The mouth breathing syndrome happens when the child substitutes nasal breathing for mouth or mixed breathing. According to literature, an exclusively mouth breathing pattern is rare or inexistent [2].

In 1861, a well-known American artist, George Catlin, wrote about the noxious effects of mouth breathing. The title of this publication, "Mal-respiration or the Breath of Life" [3] was subsequently changed to "Shut Your Mouth and Save Your Life" [4].

Angle [5] in 1907, described that mouth breathing could cause structural deformations if these alterations had happened on an important period of growth.

Moss [6] in 1969, on his "Functional Matrix" theory, reported that nasal breathing is extremely important and favors growth and an adequate development of the craniofacial complex, which interacts with other functions, such as chewing and swallowing [7].

Nasal breathing has been well documented to providing various benefits. The nose is equipped with a complex filtering mechanism which purifies the air we breathe before it enters the lungs. Breathing through the nose during expiration helps maintain lung volumes and so may indirectly determine arterial oxygenation [8].

Mouth breathing is a pathological condition that deprives the individual from all the advantages that nasal breathing can propiciate. The nose is responsible for filtering, warming and humidifying the air inhaled even before it hits the lungs, besides participating on the olfaction and the resonance of sound during the vocal emission [9].

When the individual is breathing through the nose, the whole stomatognathic system functions normally, i.e. the proprioceptions of the periodontal dental membranes and of the temporomandibular joints (ATM) send messages to the Central Nervous System that they are working under normal conditions, with sub-atmospheric pressure of the internal environment, instead of atmospheric pressure, which is the correct state for the external environment. Working with sub-atmospheric pressure means that there is lip sealing and that at each deglutition this sub-atmospheric pressure will maintain itself. On the moment of feeding, with every food introduced on the mouth cavity, the lips will seal themselves and the bilateral, synchronic and harmonious chewing will begin [10].

Aragão [10] reports that bilateral chewing proporciona an adequate proprioception of all the periodontal membranes and of both ATM, which leads to an adequate afference to the SNC and also to the adequate stimulus of growth and development preconized by Moss, Planas and DalPont. The individual who breathes through the mouth does not have lip sealing and will end up chewing unilaterally. Consequently, all the muscles from the working side will hypertrophiate, and among them are the supra hyoid muscles, infra-hyoid muscles, tongue muscles, sternocleidomastoid muscle and cervical muscles. These muscles will tractionate the aponeurosis, wich will modify the spacial position of all the mimical muscles on this chewing side. This will cause a change on body posture, head inclination and the lifting of the collarbone to the same side of the shortening.

Mckeown and Macaluso [8], Okuro., *et al.* [11], Huggare., *et al.* [12] report postural problems on mouth breathers, besides facial problems, when the head is anteriorized to compensate the restriction of the air passages and to make brething possible, by the increase of air passage through the pharynx.

According to Hulcrants., *et al.* [13], when mouth breathing becomes chronic, by vice or nasal obstruction, many morphological alterations that compromise growth and the development of the child happen.

This article will report the treatment of a clinical case of mouth breathing on a child with the Human Body Total Care Method - Aragão Function Regulator (HBTC-RFA). The HBTC-RFA method disposes of three types of appliances: RFA II, III and IV. The results were obtained with the RFA III and IV appliances.

Clinical Case

The patient is 5 years and 2 months old, male, Caucasian, mouth breather, primary dentition, with the following intra-oral alterations: Class III Angle malocclusion on the right side and Class II Angle malocclusion on the left side, anterior crossbite, covering elements 11, 21 and 22, gothic palate and atretic maxilla, type II superior and inferior Baume's arches, absence of upper and lower primate spacing (between the elements 52 and 53, 62 and 63, 73 and 74, 83 and 84), lower crowding and lower midline deviated to the left side (patient's chewing side).

As for facial features, the patient presented dark circles, expressionless gaze, absence of lip sealing, labiovertion, dry lower lip and shortening of the upper lip.

Postural alterations were also noticed. Among them, there were the head anteriorized and slightly tilted to the left side, higher shoulder on this same side, abdomem projected forward and lordosis.

The chosen treatment plan was the Human Body Total Care Method - Aragão Function Regulator (HBTC-RFA). The method includes a protocol of lip sealing with slow and deep breathing and the use of the Aragão Function Regulator (RFA).

For the exercise of lip sealing, the patient used a thin silver chain, in na adequate size, between the lips, mantaining the pupillary plane on the horizon. The time of usage was from 5 to 10 minutes per hour, while awake, when the patient inhaled deeply and profoundly through the nose and then exhaled through the nose too.

Initially, the appliance used was the RFA III (Figure 1 and Figure B), with the intention of uncrossing the lower bite (Figure A) and proportioning maxillar growth. After 2 months and 18 days, the bite started to uncross (Figure C).

After 9 months of usage of the RFA III, the anterior bite uncrossed completely (Figure D), and the appliance was changed to the RFA IV (Figure E and Figure 2), which brought a very significant improvement between the upper and lower arches (Figure F).

It was possible to notice changes on body posture, as well as occlusal alterations (Figure 4), showing signifcant improvement on the positioning of the scapulas, head and spine.

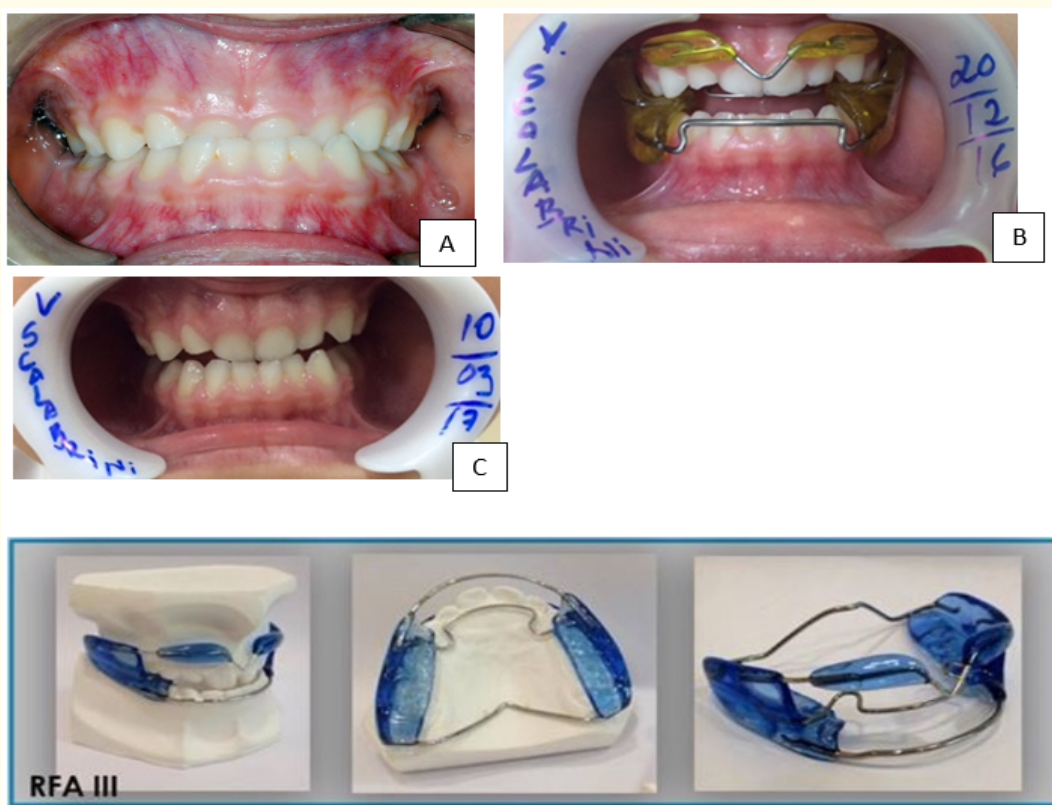

Figure 1: Aragão Function Regulator III.

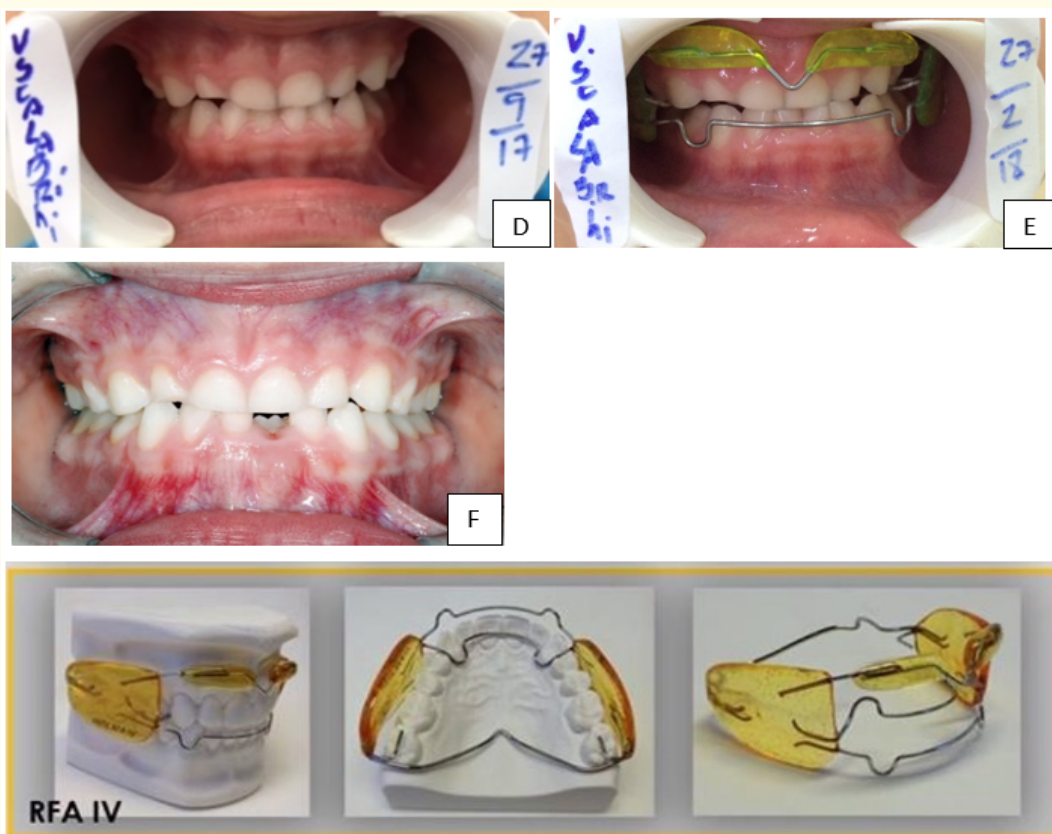


Figure 2: Aragão Function Regulator IV.

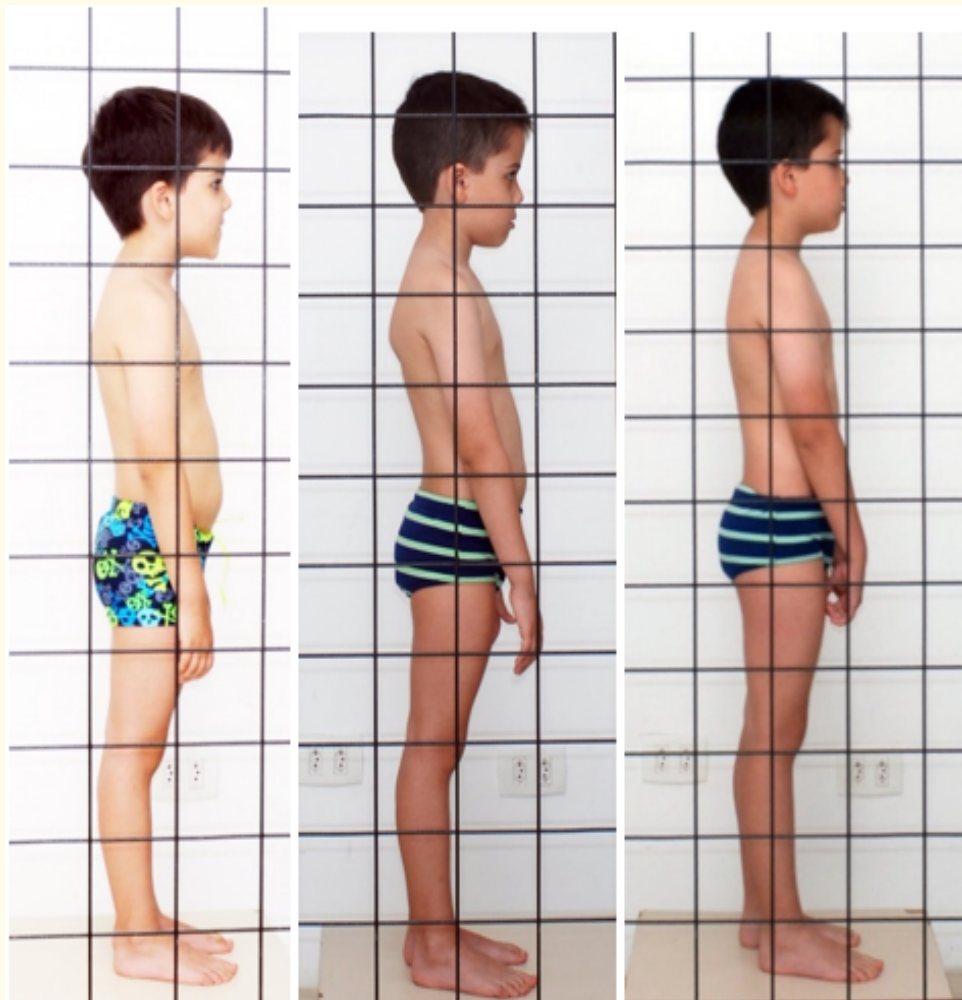

Figure 3: Effects on the body posture after using RFA III and IV.

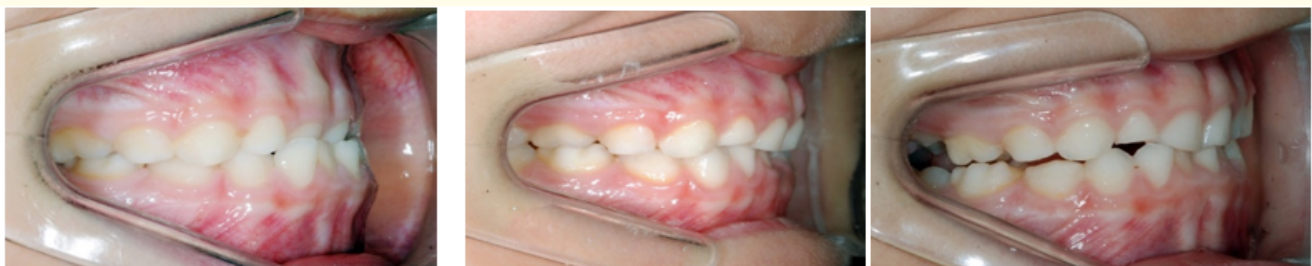

Figure 4: Occlusal alterations.

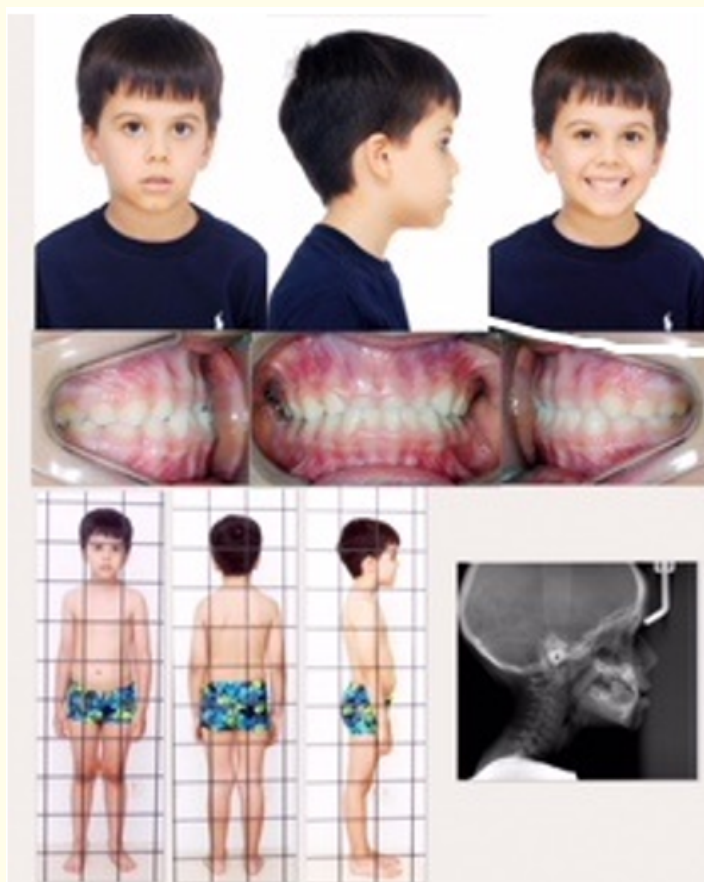

Figure 5: Pre-treatment photographs.

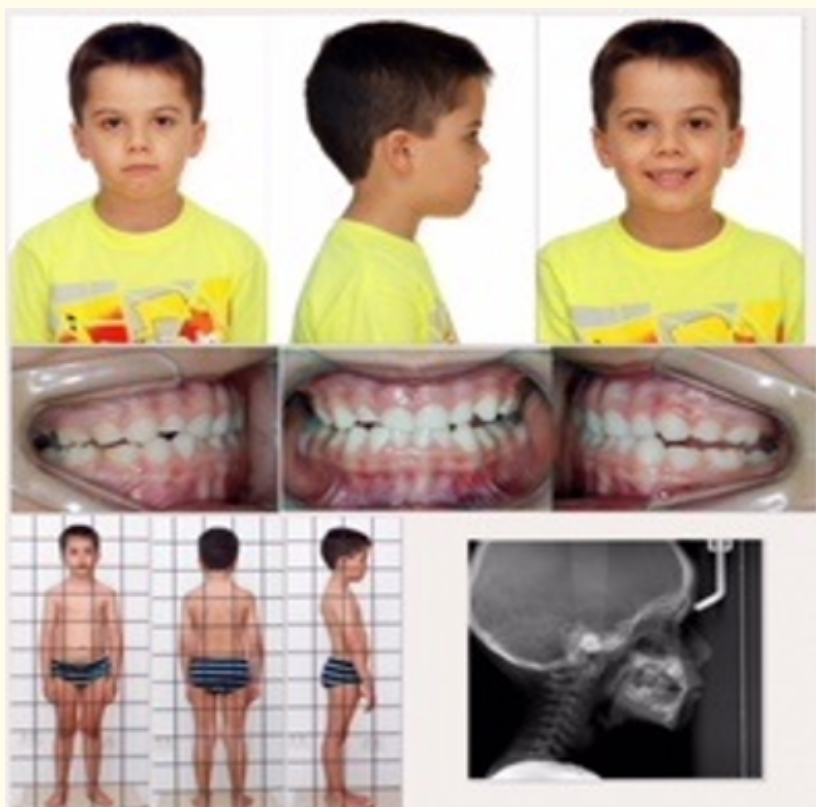

Figure 6: Photographs taken 11 months after the beginning of the treatment.

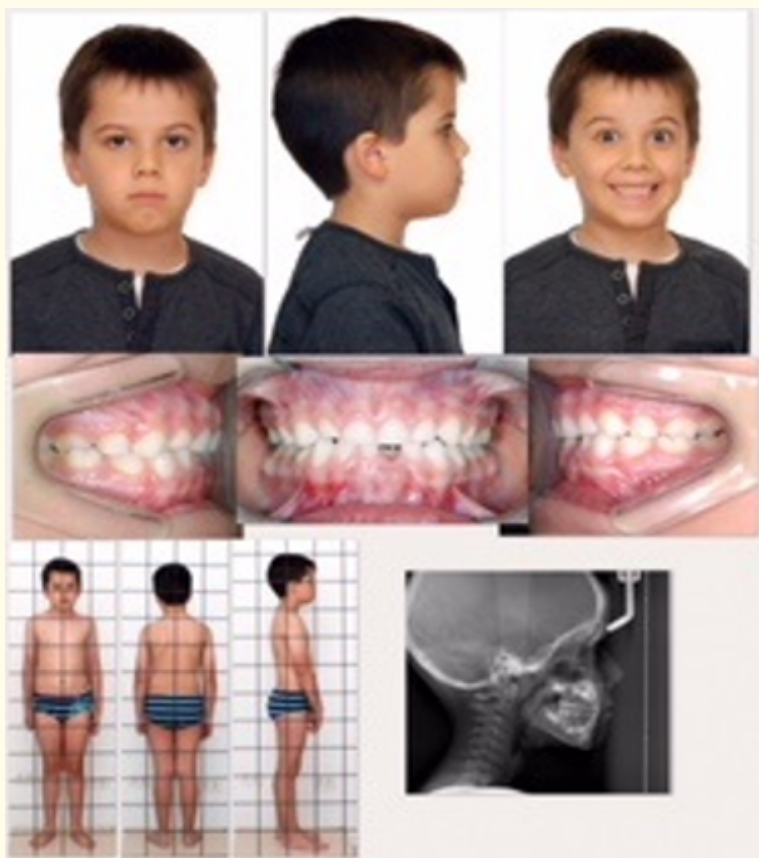

Figure 7: Photographs taken 1 year and 9 months after the beginning of the treatment.

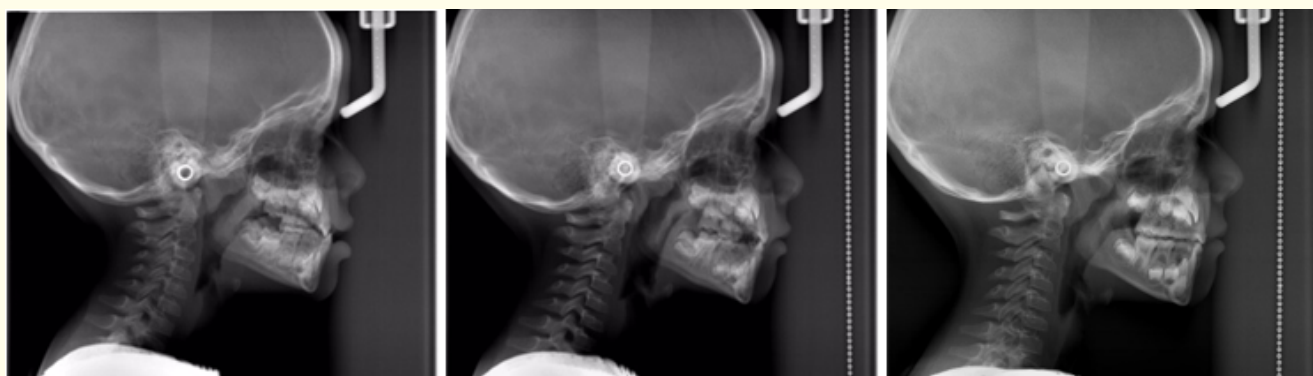

Figure 8: Cephalometric x-ray showing the improvement on the head posture from the beginning of the treatment to 1 year and 9 months of using Aragão Function Regulators III and IV.

Discussion

At the time of birth, the face is less developed than the skull. During the first years of life, facial growth is responsible for the changes on the craniofacial proportion. On this phase, however, nasal breathing can be impaired due to some factors, causing extremely important facial alterations on the child. The airway is covered by lymphoid tissue, forming the Waldeyer ring, which is mainly constituted by lingual, palatine, pharyngeal and tubal tonsils. They suffer hypertrophy from the second year of life to adolescence and, associated to the small

volume of the lower airway on this age, can obstruct the airway; this fact is more common on the pharyngeal tonsil, due to its volume increase on a narrow lower airway. The allergic rhinitis predisposes to nasal obstruction, which may cause mouth breathing on this age group. These two situations are the two main causes of mouth breathing, usually associated with each other, besides many other that can also be observed [14].

The mouth breather shows an anteriorized head and neck posture, in the way of making the air passage through the oropharynx easier. This body posture becomes more significant according to the time of unilateral chewing the patient presents. Besides leaning the head forward, the mouth breather also rotates his head back. This has major influence on the positioning of the cervical vertebrae [10].

As a result of assuming a new posture, to compensate and make breathing possible, the mouth breather may suffer these skeletal and myofunctional alterations even before the growth spurt during adolescence [14,15].

When there is no air passage with an adequate flow through the nasal fossae, the nasal mucosa becomes hypertrophied, pale and loses its function. Besides that, the low nasal flow leads also to the hypoplasia of the maxillary sinuses and the narrowing of the nasal fossae.

The maxillary hypoplasia can occur as a consequence of two factors: air passage with an inadequate flow through the nasal fossae and lack of tongue pressure against the hard palate. In most cases, the palate looks gothical, what leads to jaw deviations in an attempt to stabilise the bite. On the antero-posterior direction, the maxillary hypoplasia shows itself by a mandibular pseudoprognathism. On the vertical direction, the lack of tongue pressure against the palate leads to insufficiency of vertical growth of the alveolar processes, leading, in turn, to dental infra-occlusion [14].

Conclusion

The HBTC-RFA method has proved to be effective on the treatment of skeletal and myofunctional alterations, producing positive effects on the patient's face and body posture, contributing to a better growth pattern and general development of the child. This supports the statement that facial and body morphology and the breathing pattern are intrinsically related.

Conflict of Interest

There is no existent conflict of interest.

Bibliography

1. Falcão DA., *et al.* "Respiradores bucais diagnosticados clinicamente e por autodiagnóstico. Consequências na postura corporal". *International Journal of Dentistry* 2.2 (2003): 250-256.
2. Abreu RR., *et al.* "Prevalência de crianças respiradoras orais". *Jornal de Pediatria* 84.5 (2008): 467-470.
3. Godsmith JL and Stoll SE. "George Catlin's concepts on mouth breathing, as presented by Dr. Edward H. Angle". *Angle Orthodontist* 64.1 (1994): 75-78.
4. Stoll SE. George Catlin's "Mal-respiration of sleep": A 19th-Century view of Sleep Physiology and Pathophysiology". *Sleep* 10.5 (1987): 496-498.
5. Angle EH. "Treatment of malocclusion of the teeth: Angle System -7th edition". Philadelphia, SS White (1907): 106-120.
6. Moss ML. "The primary role of functional matrices in facial growth". *American Journal of Orthodontics* 55.6 (1969): 566-577.
7. Prates NS., *et al.* "Respiração bucal e problemas ortodônticos: relação caus e efeito". *Revista paulista de odontologia* 19.4 (1977): 14-18.
8. Mckeown P and Macaluso M. "Mouth Breathing: Physical, Mental and Emotional consequences". *Oral Health* (2017).
9. Hermann JS. "Características Clínicas De Crianças Respiradoras Orais". *Pediatria Moderna Set* 49.9 (2013): 385-392.

10. Aragão W. "Regulador de Função Aragão - Tratamento das Doenças Sistêmicas a Partir do Sistema Estomatognático" (2007): 4-5.
11. Okuro RT, *et al.* "Mouth breathing and forward head posture: effects on respiratory biomechanics and exercise capacity in children". *Jornal Brasileiro de Pneumologia* 37.4 (2011): 471-479.
12. Huggare JA and Laine-Alavaca MT. "Nasorespiratory function and head posture". *American Journal of Orthodontics and Dentofacial Orthopedics* 112.5 (1997): 507-511.
13. Hulcrantsz E., *et al.* "The influence of tonsillar obstruction and tonsillectomy on facial growth and dental arch morphology". *International Journal of Pediatric Otorhinolaryngology* 22.2 (1991): 125-134.
14. Pereira FC., *et al.* "Avaliação cefalométrica e miofuncional em respiradores bucais". *Revista Brasileira de Otorrinolaringologia* 67.1 (2001): 43-49.
15. Oliveira CF, *et al.* "Ocorrência de má oclusão e distúrbio articulatorio em crianças respiradoras orais de escolas públicas de Santa Maria- Rio Grande do Sul". *Revista Gaúcha de Odontologia* 56.2 (2008): 169-174.

Volume 8 Issue 1 January 2019

©All rights reserved by Baruhm Margareth.