

Intravesical Catheter Knot in a Girl: A Case Report and Review of Literature

Volkan Sarper Erikci^{1*}, Mehmet Mert¹, Tunç Özdemir² and Gökhan Köylüoğlu²

¹Departments of Pediatric Surgery, Tepecik Training Hospital, Sağlık Bilimleri University, Izmir, Turkey

²Departments of Pediatric Surgery, Tepecik Training Hospital, Katip Çelebi University, Izmir, Turkey

*Corresponding Author: Volkan Sarper Erikci, Departments of Pediatric Surgery, Tepecik Training Hospital, Sağlık Bilimleri University, Izmir, Turkey.

Received: June 26, 2018; Published: July 28, 2018

Abstract

Urinary catheterisation is a common urologic practice performed in daily medical practice. Despite its safety, the procedure itself is not without complications. As a rare complication of bladder catheterisation, knotting of a urinary catheter is mostly reported in young male children. Knotted catheters are mostly feeding tubes used for diagnostic and therapeutic purposes. Here we present a 3.5-year-old girl with a recurrent urinary tract infection referred to our department following the inability to remove a feeding tube that had been introduced into the bladder to acquire a urine sample. Under general anesthesia, cystoscopic removal of the knotted catheter after deknottting was performed safely. It is aimed in this report to review the presentation, imaging findings and management of a knotted urinary catheter inside the bladder in children and the patient is discussed under the light of relevant literature.

Keywords: Urinary Catheter; Catheterisation Complication; Knotting of Feeding Tube

Introduction

Inserted catheters for various purposes are known to spontaneously knot inside the human body [1]. As an integral part of daily urological practice, urethral catheters are commonly inserted for diagnostic and therapeutic purposes. It is a safe procedure but it is not free of complications. In a recent report, general complications of urethral catheterisation have been reported in 21% of children and include painful urination, genital pain, urinary retention, gross hematuria and secondary urinary tract infection [2]. There are few reports in the literature mentioning the management of spontaneous knotting of urinary catheters in children [3-8]. The incidence with regard to knotting of urethral catheterisation has been estimated to be 2 per one million catheterisations [4]. In this study, we report an instance of a feeding tube knotting within the bladder in a girl. It is also aimed in this report to review the presentation, imaging findings and management of these patients.

Case Report

A healthy 3.5-year-old girl was brought to the emergency department by her parents because of recurrent urinary tract infection (UTI). The infant was otherwise well and a 5 F infant feeding tube was inserted in the emergency department to acquire a urine sample for further investigation. After getting the urine sample, a resistance was noted on attempted removal of the catheter and it was found to be lodged within the bladder (Figure 1). Inspection of the child revealed that the catheter was deeply inserted into the bladder and become lodged at the catheter level of 21 cm (Figure 2). Under general anesthesia cystoscopy was performed and the feeding tube was found to be knotted (Figure 3). The feeding tube was removed after deknottting within the bladder (Figure 4). At the end of the procedure control cystoscopy was performed to evaluate the urethra and bladder mucosa which was found to be normal and a foley catheter was inserted into the bladder for urinary drainage. The child made a good post-operative recovery and was discharged home well the following day.

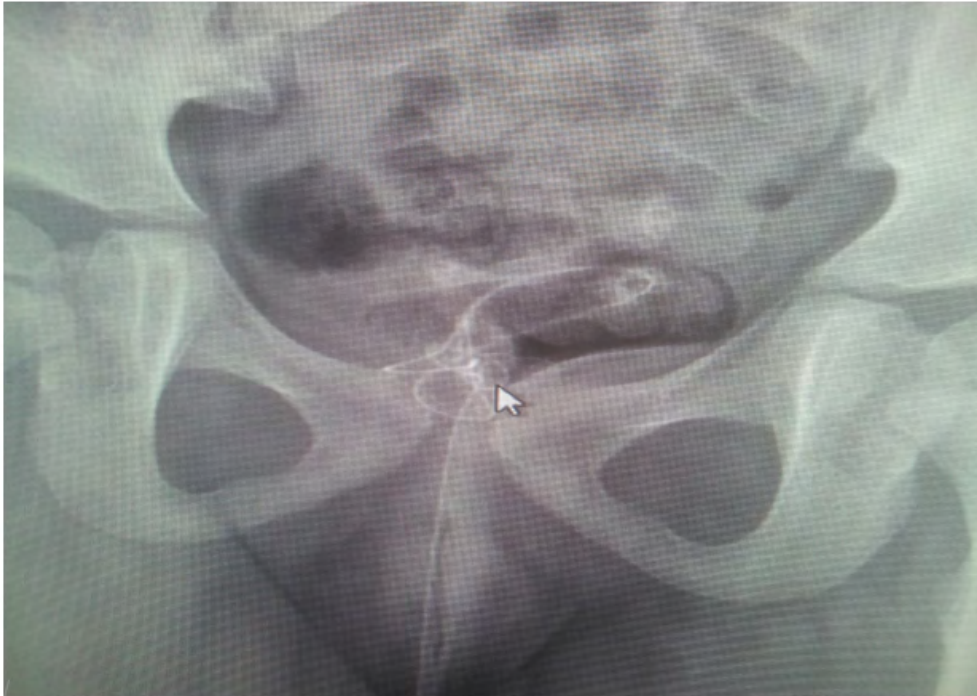

Figure 1: Radiograph showing the knotted catheter in the bladder (Arrow: the knot).

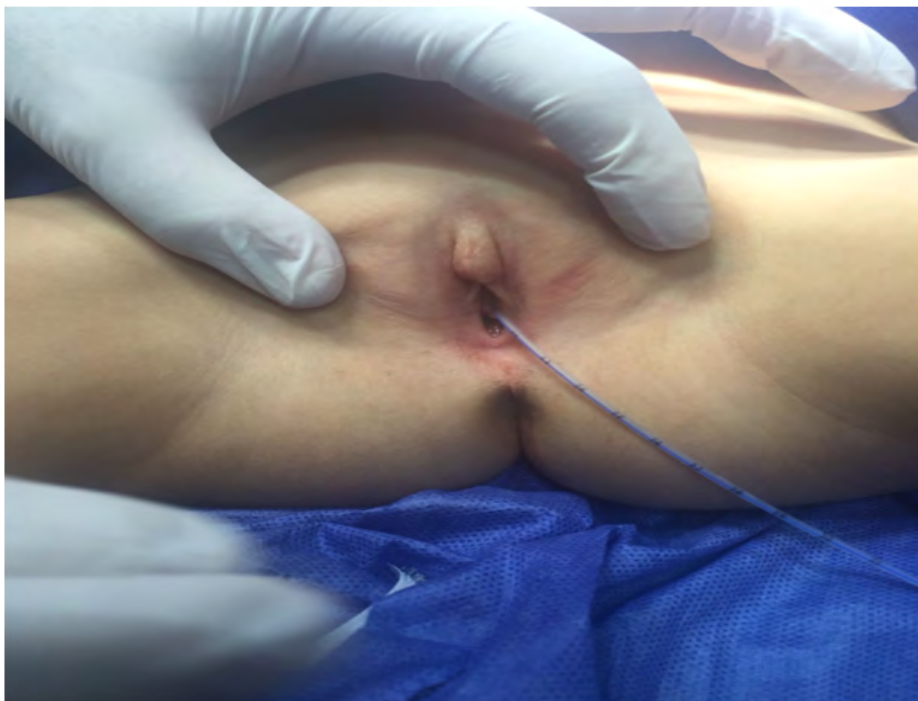

Figure 2: 5F feeding tube lodged at the catheter level of 21 cm.

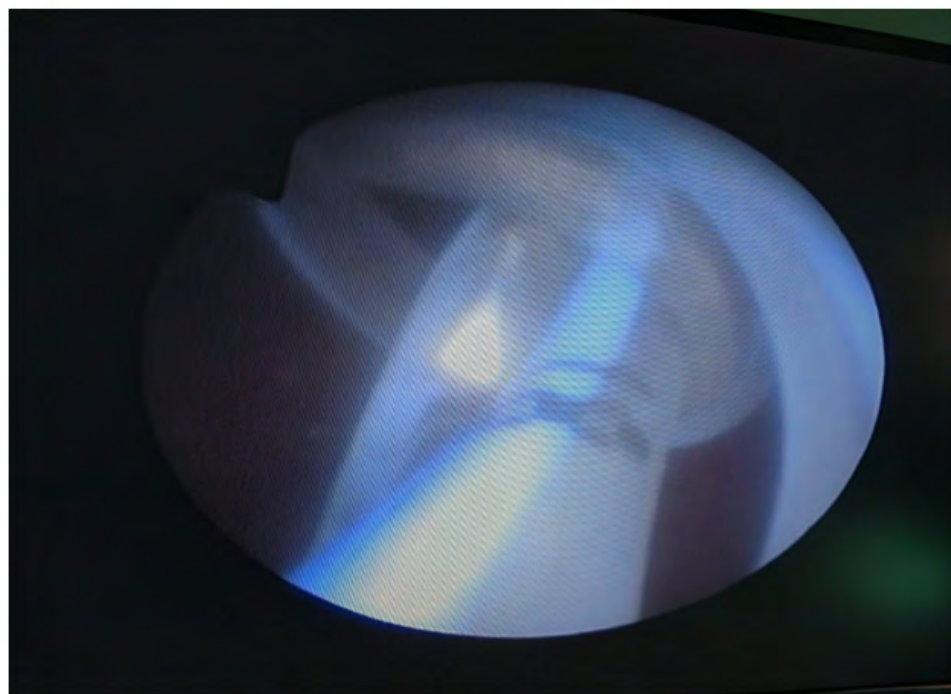


Figure 3: Cystoscopic view showing the knot formation at the distal end of the catheter.




Figure 4: Postoperative view showing the retrieved urethral catheter after deknottting.

Discussion

Urethral catheterisation is a safe procedure that is commonly performed in the pediatric age group in order to obtain urine sample, to relieve urinary retention and for clean intermittent catheterisation in the neurologically impaired patients, to monitor fluid balance in the critically ill children, or in investigation for vesicoureteric reflux which mandates a voiding cystourethrography. Although Foley's catheter is preferred, small feeding tubes (size 5F or 8F) as they are more rigid, freely available and cost effective, are suitable alternatives in infants and children [9-11].

The common complications of urethral catheterisation include infection, urothelial trauma during procedure, perforation, creation of false tracts and dislodgement [12]. Although rarely seen, spontaneous knotting of the catheter inside the urinary tract may be observed in children following urethral catheterisation and this has been described since 1974 [13]. It occurs more frequently in pediatric patients compared to adults and males are more commonly affected compared to females [8,10,14,15]. Common clinical traits of these patients include young age, male preponderance and usage of feeding tubes as urethral catheter. In a meta-analysis on urethral and ureteral knotting of catheters in children using a Medline search covering the period between 1974 and 2002, a total of 22 children (18 male, 4 female) were retrieved [16]. There are also more recent case reports that also describe this uncommon complication of urethral catheterisation [17,18]. To the best of our knowledge, our case is the 5th female child with a knotted catheter inside the bladder. Reported complications of removal of knotted catheter inside urinary tract include the need for undergoing general anesthesia, radiation exposure during fluoroscopy, haematuria, urethral trauma, urinary incontinence and stricture formation [19]. Apart from urethral catheterisation, catheter knotting during suprapubic catheterisation has also been described and may be regarded as an interesting complication [20].

It has been reported that the risk factors for knotting of urethral catheters in children include small size of the catheters, the use of feeding tubes as catheters, overestimation of the urethral length and the distance the catheter must be inserted, and previous surgery [4,10,15,20-26]. It is generally believed that excessive coiling of the catheter causes its distal tip to pass an open loop and when withdrawn, the coil tightens into a knot [4,22]. It is important not to insert too much of length of the catheter. The safe insertion lengths of 6 cm in a male newborn and 5 cm in a female newborn and in extremely premature babies with weight of < 750 grams the insertion length of < 2.5 cm in girls and < 5 cm in boys have been recommended [10]. The reason why knotting is more common in children than in adults is attributed to the use of slender and more flexible catheters in pediatric practice [4,22]. Overestimation of the male urethral length is the reason of male preponderance in catheter knotting cases. Bladder spasm has also been proposed as a risk factor and anticholinergic drugs have been suggested to prevent this complication [27]. Another possible explanation for the formation of knot is the water-current produced by the drainage of urine after insertion into a distended bladder. It has been stated that after overinsertion of the tube, the catheter's free end swirls under the influence of the water current and that an open-loop knot is formed [1]. Whatever the the cause of catheter knotting once it happens it should be managed properly.

There are several techniques which have been described to retrieve the knotted catheter [4,22]. These include sustained traction under general anesthesia, deknotted the knot using a guidewire, endoscopic removal, percutaneous cystotomy under general anesthesia and open surgery such as cystotomy or urethrotomy [4,20,22,27-30]. Sustained traction under general anesthesia carries the risk of urethral damage and this technique is not useful when the knot is bulky. Deknotting by the guide-wire manipulation is useful at the early 'open-loop stage' of knot formation when the knot is not tight enough [28]. Although open surgical intervention such as cystotomy or urethrotomy may be alternative choices of management, at the modern era of our century, endoscopic retrieval, if available, should be the first choice of treatment in these children. After removal of the knot, it is recommended that a control cystoscopy be performed to check for injury and bleeding. Hopefully, in our case, after deknotted of the catheter, cystoscopic removal of the catheter with the aid of endoscopic grasper could be possible and the control cystoscopy was found to be normal. In clinical algorithm with regard to management of catheter knotting in urinary tract after urethral catheterisation, our first choice of treatment is endoscopic retrieval.

The attention should be directed towards the prevention of this rather rare complication. Unfortunately, many medical staff are unaware of this problem. In a telephone survey reported from Canada comprising 24 emergency departments, it was found that none of the medical staff working in these centers were aware of catheter knotting [31]. Careful selection of the catheters and a better understanding of urethral anatomy and safe insertion lengths are important in prevention of the catheter knotting. Moreover it is important to use urinary catheters instead of feeding tubes because they contain balloon and are stiffer. It has also been reported that silicone catheters are more flexible than others and may predispose to even greater coiling and knot formation and should not be the first choice of use in bladder catheterisation [32]. After insertion of the tube it is also important to secure the tube appropriately otherwise it may fall out of or advance into the bladder giving rise to a possible knot formation [5]. Another measure to prevent knotting is to pass tube gently and as soon as the catheter enters the bladder which is indicated by flow of urine into the tube, the process should be terminated [33]. It is unlikely for the tube to loop and knot spontaneously with a short length of tube inside the bladder. In order to prevent catheter related complications, judicious use of indwelling catheter and its early and timely removal has been suggested [34].

Conclusion

In conclusion, this rare but hazardous complication should be kept in the minds of medical staff involved in the insertion, maintenance and removal of catheters. Catheters slender than 10F and insertion of excessive length with regard to age and sex of the child should be avoided. If necessary, balloon-tipped urethral catheters should be used for therapeutic and diagnostic purposes. With proper training and increased the experience of medical staff it will be possible to avoid such a rare but dangerous complication.

Bibliography

1. Raveenthiran V. "Spontaneous knotting of urinary catheters: clinical and experimental observations". *Urologia Internationalis* 77.4 (2006): 317-321.
2. Ouellet-Pelletier J., et al. "Adverse events following diagnostic urethral catheterization in the pediatric emergency department". *Canadian Journal of Emergency Medicine* 18.6 (2016): 437-442.
3. Sujjantararar P. "Intravesical knotting of a feeding tube used as a urinary catheter". *Journal of the Medical Association* 90.6 (2007): 1231-1233.
4. Foster H., et al. "Adventitious knots in urethral catheters: reports of 5 cases". *Journal of Urology* 148.5 (1992): 1496-14968.
5. Mayer E., et al. "Management of urethral catheter knot in a neonate". *The Canadian Journal of Urology* 9.5 (2002): 1649-1650.
6. Singh RB., et al. "Knotting of feeding tube used for bladder drainage in hypospadias repair". *Journal of Indian Association of Pediatric Surgeons* 10.3 (2005): 199.
7. Lodha A., et al. "Intraurethral knot in a very-low-birth-weight infant: radiological recognition, surgical management and prevention". *Pediatric Radiology* 35.7 (2005): 713-716.
8. Turner W. "Intravesical catheter knotting: an uncommon complication of urinary catheterization". *Pediatric Emergency Care* 20.2 (2004): 115-117.
9. Anbu AT. "Urethral catheter knotting in preterm neonates". *Indian Pediatrics* 41.6 (2004): 631-632.
10. Carlson D and Mowery BD. "Standards to prevent complications of urinary catheterization in children: should and should-nots". *Journal of Pediatric Nursing* 2.1 (1997): 37-41.

11. Gnanaraj and Gnanaraj L. "The infant feeding tube: a boon to the rural urologist". *Tropical Doctor* 26.4 (1996): 191.
12. Sithasanan N., et al. "Twisted fate of bladder catheters". *Medical Journal of Malaysia* 61.3 (2006): 369-370.
13. Lissos I. "Knots in the bladder". *British Journal of Urology* 46.3 (1974): 346.
14. Kanengiser S., et al. "Knotting of a bladder catheter". *Pediatric Emergency Care* 5.1 (1989): 37-39.
15. Sugar EC and Firlit CF. "Knot in urethral catheter due to improper catheterization technique". *Urology* 22.6 (1983): 673-674.
16. Tsaroucha AK., et al. "Catheter knots in the urinary tract". *Minerva Urologica E Nefrologica* 56.4 (2004): 353-357.
17. Minami Y., et al. "Knotting of a urethral catheter". *Pediatrics International* 59.8 (2017): 932-933.
18. Terentiev V., et al. "A knotted urethral catheter in the emergency department". *Pediatric Emergency Care* 33.3 (2017): 190-191.
19. Perera TMR., et al. "A case of intravesical knotting of a feeding tube used as a urethral catheter". *Sri Lanka Journal of Child Health* 46.1 (2017): 80-81.
20. Yiğiter M and Salman AB. "Intravesical catheter knotting: an unusual complication of suprapubic catheterization". *Turkish Journal of Pediatrics* 58.4 (2016): 452-455.
21. Klein EA., et al. "Retained straight catheter: complication of clean intermittent catheterization". *Journal of Urology* 135.4 (1986): 780-781.
22. Goetting MG. "Bladder catheter knotting: a case report". *Henry Ford Hospital Medical Journal* 36 (1988): 191-192.
23. Pearson-Shaver AL and Anderson MH. "Urethral catheter knots". *Pediatrics* 85 (1990): 852.
24. Parker A. "A rare complication of pediatric catheterization". *Pediatric Nursing* 19 (1993): 194-195.
25. Ball R., et al. "Transurethral removal of knotted bladder drainage catheter in a male following bladder neck reconstruction". *Urology* 41.3 (1993): 234-236.
26. Gonzalez CM and Palmer LS. "Double-knotted feeding tube in a child's bladder". *Urology* 49.5 (1997): 772.
27. Steinbecker KM and Teague JL. "Catheter knotting in a catheterizable urinary reservoir". *Journal of Pediatric Surgery* 36.3 (2001): 516-517.
28. Arda IS and Özyaylalı I. "An unusual complication of suprapubic catheterization with cystofix: catheter knotting within the bladder". *International Journal of Urology* 8.4 (2001): 188-189.
29. Harris VJ and Ramilo J. "Guide wire manipulation of knot in a catheter used for cystourethrography". *Journal of Urology* 116.4 (1976): 529.
30. Dogra PN., et al. "Endoscopic removal of knotted urethral catheter: a point of technique". *Urologia Internationalis* 71.1 (2003): 8-9.
31. Sarin YK. "Spontaneous intravesical knotting of urethral catheter". *APSP Journal of Case Reports* 2.3 (2011): 21.
32. Arena B., et al. "Urethral catheter knotting: be aware and minimize risk". *Canadian Journal of Emergency Medicine* 4.2 (2002): 1-5.

33. Mustafa NA and Lope RJR. "Spontaneous knot formation impeding the removal of a silicone urethral catheter". *Images in Neonatal Medicine* 91.4 (2005).
34. Eke N, *et al.* "Spontaneous knotting of a feeding tube in the bladder". *Annals of African medicine* 12.1 (2013): 40-42.
35. Garg G., *et al.* "Urinary catheterization from benefits to hapless situations and a call for preventive measures". *Journal of Family Medicine and Primary Care* 5.3 (2016): 539-542.

Volume 7 Issue 8 August 2018

© All rights reserved by Volkan Sarper Erikci, *et al.*