

## Single Port Laparoscopic Orchidopexy in Children Using Surgical Glove Port and Conventional Rigid Instruments

BEN DHAOU Mahdi<sup>1</sup>, CHTOUROU Rahma<sup>1\*</sup>, JALLOULI Mohamed<sup>1</sup>, ZITOUNI Hayet<sup>1</sup>, MHIRI Riadh<sup>1</sup>

Department of Paediatric surgery, Hedi Chaker Hospital, Tunisia

\*Corresponding Author: Dr. Rahma CHTOUROU, Department of pediatric surgery, Hedi Chaker Hospital, Tunisia.

Received: August 18, 2015; Published: September 23, 2015

### Abstract

**Objectives:** Using a review of the literature, we described our technique for laparoendoscopic single site surgery orchidopexy using glove port and rigid instruments and we assessed its feasibility and its outcomes.

**Patients and Methods:** We retrospectively reviewed the case records of all children who had undergone laparoendoscopic single site surgery orchidopexy for a nonpalpable intraabdominal testis between January 2013 and September 2014, using surgical glove port and conventional rigid instruments in children.

**Results:** A total of 20 patients were collected. Mean age was 18 months. All cases had non palpable unilateral undescended testis. Fourteen patients (70%) had unilateral right side and six patients (30%) had unilateral left side. Seventeen patients underwent primary orchidopexy. Three patients had single-port laparoscopic Fowler-Stephens orchidopexy for the first and the second stage. Average operating time was 57 minutes (ranging from 40 to 80 minutes). No patient was lost to follow-up. At follow-up 2 testis were found to have retracted out of the scrotum and these were successfully dealt with a second operation. One testis was hypoplastic in the scrotal pouch. There were no signs of umbilical hernia.

**Conclusion:** Single port laparoscopic orchidopexy using glove port and rigid instruments is technically feasible and safe for various nonpalpable intraabdominal testis. However, surgical experience and long-term follow-up are needed to test the superiority of this technique.

**Keywords:** Children; Non palpable testis; Orchidopexy; Single port laparoscopic surgery; Undescended testis

**Abbreviations:** NPAT: nonpalpable intraabdominal testis; SGP: surgical glove port; LESS: laparoendoscopy single site; FS: Fowler-Stephens; SILS: single incision laparoscopic surgery

### Introduction

Laparoscopy represents the gold standard to appreciate the effective strategy for diagnosis and treatment of nonpalpable intraabdominal testis (NPAT) which represents around 20% of un-descended testis [1]. With the evolution of minimally invasive surgery, the operative approach toward orchidopexy for NPAT has shifted from a traditional open approach to a multiport and single laparoscopic technique.

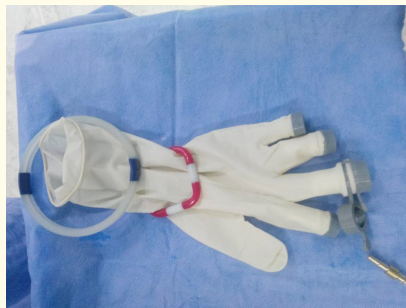The aim of this study was to evaluate the feasibility of orchidopexy for a NPAT using surgical glove port (SGP) and conventional rigid instruments.

### Materials and Methods

We retrospectively reviewed of all cases of patients with NPAT who have undergone laparoendoscopy single site (LESS) orchidopexy at our department between January 2013 and September 2014. Throughout the study period LESS was done by using small size (ROSE PORT). All families consented to the single-incision approach and possible conversion to multiport laparoscopy. The medical records of the patients were reviewed, and data concerning age, weight, operative time, complications and surgical outcome were collected.

### Operative technique

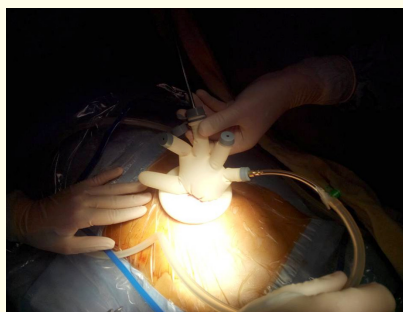
We started intervention by glove preparation which consisted in the insertion of two 3-mm and one 5-mm trocars through the fingers of the glove by cutting the tips. A flexible ring was passed through the open end of the glove and turned around it [figure 1].



**Figure 1:** Glove port ready for insertion.

A 1 cm incision at the level of the umbilicus, without dissection of subcutaneous tissue was done. After the incision, the inner flexible ring, fitted with the glove, was introduced into the abdomen. The open end of the glove was then wrapped around the outer larger ring. Carbon dioxide insufflations can be performed through any of the trocars.

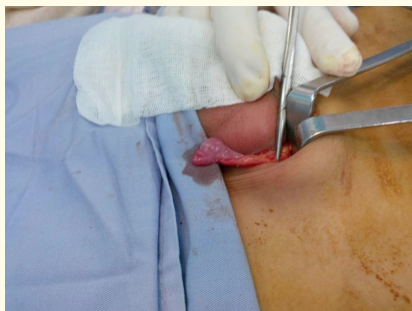Thirty degree angle laparoscope with 3-mm or 5-mm straight rigid instruments identical to those for conventional laparoscopy including grasper, scissors and electrocautery were used to perform our LESS orchidopexy [figure 2].



**Figure 2:** Surgical glove port with conventional rigid instruments.

We opted for first stage of two-stage Fowler-Stephens (FS) Orchiopexy if the testis was closer to the iliac vessels. The remaining details of orchidopexy were the same as those in the multiport procedure [Figure 3].

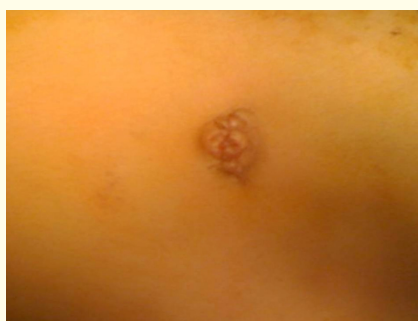No other trocars were used for any of the procedure.



**Figure 3:** Intra operative view of undescended testis.

## Results

A total of 20 boys LESS orchidopexy were performed in our department. Their age ranged from 9 months to 24 months (mean age: 18 months). All patients had non palpable unilateral undescended testis, which was in the right side in 14 patients and left side in six patients. Seventeen patients had laparoscopic orchidopexy without vessel division as a one-stage procedure and 3 patients had LESS Fowler-Stephens orchidopexy for the first and the second stage. LESS orchidopexy was possible in all selected cases without conversion. Average operating time was 57 minutes, with extremes ranging from 40 to 80 minutes. The mean operative time for those undergoing one-stage orchidopexy was 57.11minutes, extremes ranging from 40 to 80 minutes, 24 minutes for primary FS (ranging from 20 to 26 minutes) and 56.66 minutes for second stage (ranging from 56 to 58 minutes). Neither intra nor postoperative complications were seen and the patients were discharged within a few hours of surgery. No patients were lost to follow-up. The total duration of the follow-up period ranged from 3 months to 1 year 6 months where one patient had atrophy, after FS procedure, and two cases had re-ascent of the testicle. There was no score done to evaluate the final scar. But umbilical incision was nearly invisible and much appreciated by the parents. There were no signs of umbilical hernia [Figure 4].



**Figure 4:** Postoperative photograph showing umbilical incision.

## Discussion

The question that arises, why did we choose this technique to do orchidopexy for NPAT? In fact, the society pushes us to remain up to date and even be ahead of our time, but not at any price, in terms of potential complications and financial costs especially for pediatric population. That's why we had chosen LESS, which has gained popularity over the last decade and it has been previously described for various procedures in adults [2] and children [3]. In addition, these approaches offer documented benefits including improved cosmetic, decreased pain and the ability to easily perform combined procedure without having to place additional ports [4].

LESS procedures can be performed with (R-port), (Uni-X) and (SILS port) which are very costly. Alexis wound retractor; curved instrument and flexible Tip laparoscope are not available in our country. Therefore, we have chosen a less expensive access method known as “surgical glove port” or “home made single-port”, which was described to perform a various procedure but only in adults [5] to improve orchidopexy for NPAT.

To our knowledge, this technique has been previously used by only four authors in pediatric population. Sultan., *et al.* [6] for a 2-year-old boy using R-port, Raju., *et al.* [7] for an 18-month-old child, Lima., *et al.* [8] for 3 boys with rigid instruments and Paul., *et al.* [9] who reported a series of 17 patients using a multichannel single port and flexible Tip Laparoscope.

In terms of technical considerations, single-incision technique, allows adequate visualization and counter traction for performing orchidopexy especially with standard instrument. However, it needs a significant coordination between the surgeon and the camera holder. The instruments are usually crossed at the access port into the abdominal cavity. This problem has been resolved by curved instruments [10].

In fact, when the first 10 operative single-incision cases were compared with the second 10 cases, a trend toward a shorter operative time was noted, but this was not statistically significant. This suggests that the learning curve to perform this operation is short.

Decreased post operative pain, as theoretical benefit of LESS, requires further investigation. Recently Zani., *et al.* [4] reported that LESS seems to be associated with more post operative pain than standard laparoscopy. But a meta-analysis described by Saldana., *et al.* [11] showed similar pain scores in both techniques. In this study, post operative pain score were not analyzed because this score did not correlate with requirement of additional analgesics. All patients were very satisfied with the cosmetic result.

### Conclusion

This is one of the largest series of pediatrics patients to undergo LESS orchidopexy and the only pediatric study to have been done with surgical gloves port. It demonstrates the safety and the feasibility of this procedure which can be an alternative to the costly commercially available single-port systems especially in a developing country.

### Conflict of interest

There exists neither financial interest nor conflict of interest.

### Bibliography

1. Scorer CG and Farrington GH. “Congenital Deformities of the Testis and Epididymis”. *Proceedings of the Royal Society of Medicine* 65.8 (1972): 744.
2. Pfluke JM., *et al.* “Laparoscopic surgery performed through a single incision: a systematic review of the current literature”. *Journal of the American College of Surgeons* 212.1 (2011): 113-118.
3. Ponsky TA., *et al.* “Early experience with single-port laparoscopic surgery in children”. *Journal of Laparoendoscopic & Advanced Surgical* 19.4 (2009): 551-553.
4. Zani A., *et al.* “Is Single Incision Paediatric Endoscopic Surgery more painful than standard laparoscopy in children? Personal experience and review of the literature”. *Minerva Pediatrica* (2014).
5. Orozakunov E., *et al.* “Single-port laparoscopic surgery by use of a surgical glove port: initial experience with 25 cases”. *Chirurgia* 108.5 (2013): 670-672.
6. Sultan RC., *et al.* “Laparoendoscopic single site orchidopexy”. *Journal of Pediatric Surgery* 46.2 (2011): 421- 423.
7. Raju GA., *et al.* “Single-site laparoscopic orchidopexy in an infant”. *Urology* 143.4 (2010): 143-146.
8. Lima GR., *et al.* “Single incision multiport laparoscopic orchidopexy: Initial report”. *Journal of Pediatric Surgery* 44.10 (2009): 2054-2056.
9. Noh PH., *et al.* “LaparoEndoscopic Single Site orchidopexy for intra-abdominal testes in the pediatric population with a multi-channel single port and flexible tip laparoscope”. *Journal of Endourology* 27.11 (2013): 1381-1383.

---

**Citation:** Rahma CHTOUROU, *et al.* “Single Port Laparoscopic Orchidopexy in Children Using Surgical Glove Port and Conventional Rigid Instruments”. *EC Paediatrics* 2.1 (2015): 92-96.

10. Dapri G., *et al.* "Single access transumbilical laparoscopic appendectomy and cholecystectomy using new curved reusable instruments: a pilot feasibility study". *Surgical Endoscopy* 25.4 (2011): 1325-1332.
11. Saldaña LJ and Targarona EM. "Single-incision pediatric endosurgery: A systematic review". *Journal of Laparoendoscopic & Advanced Surgical* 23.5 (2013): 467-480.

**Volume 2 Issue 1 September 2015**

© All rights are reserved by Rahma CHTOUROU., *et al.*