ECRONICON OPEN ACCESS

EC ORTHOPAEDICS
Case Report

Role of Distraction of the Spinous Process in Sever Adult Isthmic Spondylolisthesis for Preparation of Intervertebral Disc Space and Cage Insertion

Wallead Aljaeafee*

Consultant Orthopedic Spine Surgeon, Al Emadi Hospital, Doha, Qatar

***Corresponding Author:** Wallead Aljaeafee, Consultant Orthopedic Spine Surgeon, Al Emadi Hospital, Doha, Qatar.

Received: January 13, 2021; **Published:** September 30, 2021

Abstract

Introduction: Isthmic spondylolisthesis can be divided into three subtypes: In the first type, there is a stress fracture leading to a complete pars defect; in the second type, the pars is intact but elongated due to the healing of micro fractures; and in the third type, the rarest of all, there is an acute pars fracture. For surgical treatment of a symptomatic adult isthmic spondylolisthesis a posterior decompression alone without fusion was introduced by Gill 1955 (1). It can result in gradual increase of listhesis and worsening of a symptomatic central, foraminal or lateral recessus stenosis. In 1985 Clowerd published the posterior interbody fusion in combination with posterior decompression to avoid the disadvantages of Gill decompression which was the instability following removal of posterior element (2).

Aim: to determine the role of distraction of the spinous process in sever adult isthmic spondylolisthesis of the vertebra above and below the slipped vertebrae after removal of posterior element to achieve a good preparation of intervertebral disc space for cage insertion.

Method: After removing of the lamina and the spinous process of the slipped vertebra, which is mainly loss in isthmic lysthesis, there will be a gap between the spinous process of the vertebra below and vertebra above the slipped vertebrae. Using a parallel lumbar rod distractor between the spinous process of the boundary vertebrae allows a central distraction and opens the intervertebral disc space in the spondylolisthesis level. If the distractor is deep enough, the risk of fracture of the spinous process is decreased and the risk of local kyphosis is reduced. This distraction allows a good preparation of the intervertebral disc space and insertion of optimal size cage, which improves the reduction of listhesis and enhance good fusion.

Conclusion: The distraction of the spinous process above and below the slipped vertebra using interspinous distractor after removal of the posterior element can be used cautiously to facilite preparation of the disc space and insertion of the intervertebral cage.

Keywords: *Spondylolisthesis; Reduction; Distraction; Spinous process; Cage insertion*

Introduction

Spondylolisthesis is the migration of one vertebra over another below it. Many classification systems are available. To reduce the sever Spondylolisthesis there is many technics with a lot of controversy. I found distraction of the spinous process above and below the slipped vertebrae by using a parallel lumbar rod distractor a safe and effective technique to be used during the operation. A good bone quality is very important for successful distraction.

Sever spondylolisthesis is mainly due to spondylolysis and affect mainly the L5/S1 82%. The disc space is very narrow and deformed in adult isthmic spondylolisthesis. The deformity of the disc space is due to deformed End plates of the involved vertebrae. The L5 is mainly dysplastic, distorted and changed mainly from square to a trapezoid with lumbar index around 0.7 and 0.76 (Figure 1 and 2) [3-6].

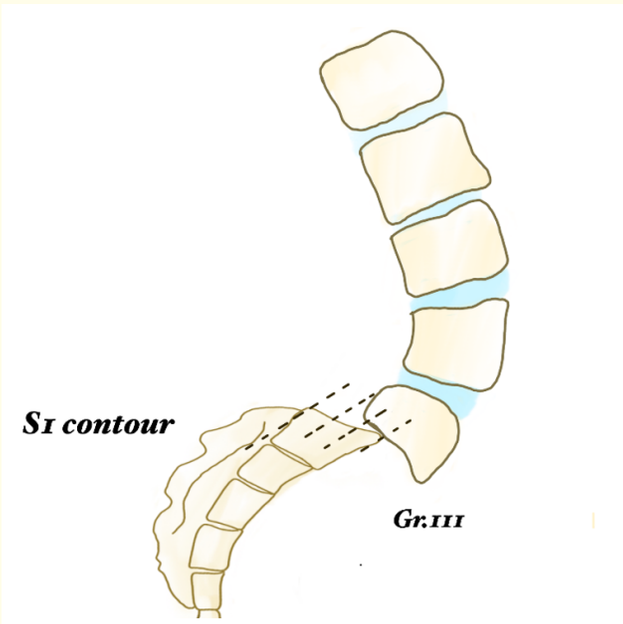

Figure 1

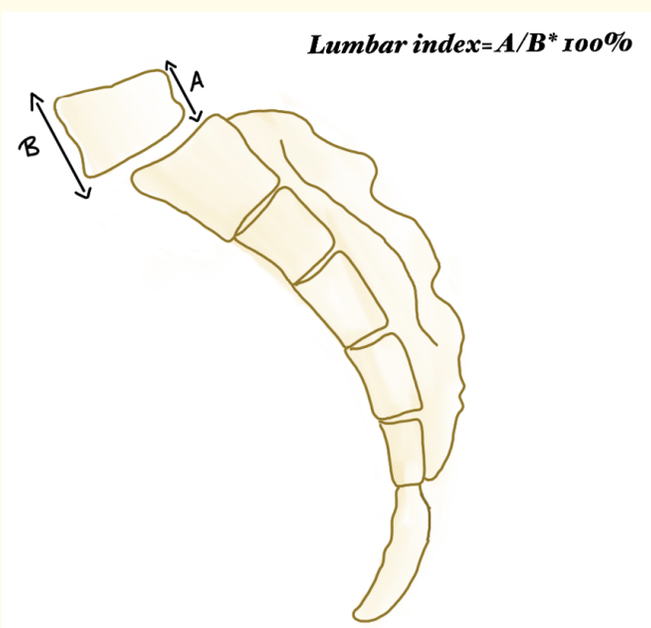

Figure 1

S1 is also dysplastic with sacral rounding or dome shape. The sacral rounding can be divided into 3 grades [7]. These anatomical changes make the preparation of the intervertebral disc space and insertion of the intervertebral cage difficult.

Case Report and Operative Technique

A 52 years old male patient with a chronic lower back pain and radiculopathy of L5 on the left more than the right with weakness of the foot dorsiflexion on the left side. Extended conservative therapy with different types of pain killers and physiotherapy has been done without benefit. Patient decided to undergo the surgery. Preoperative diagnostics were done with x-ray, Ct and MRI.

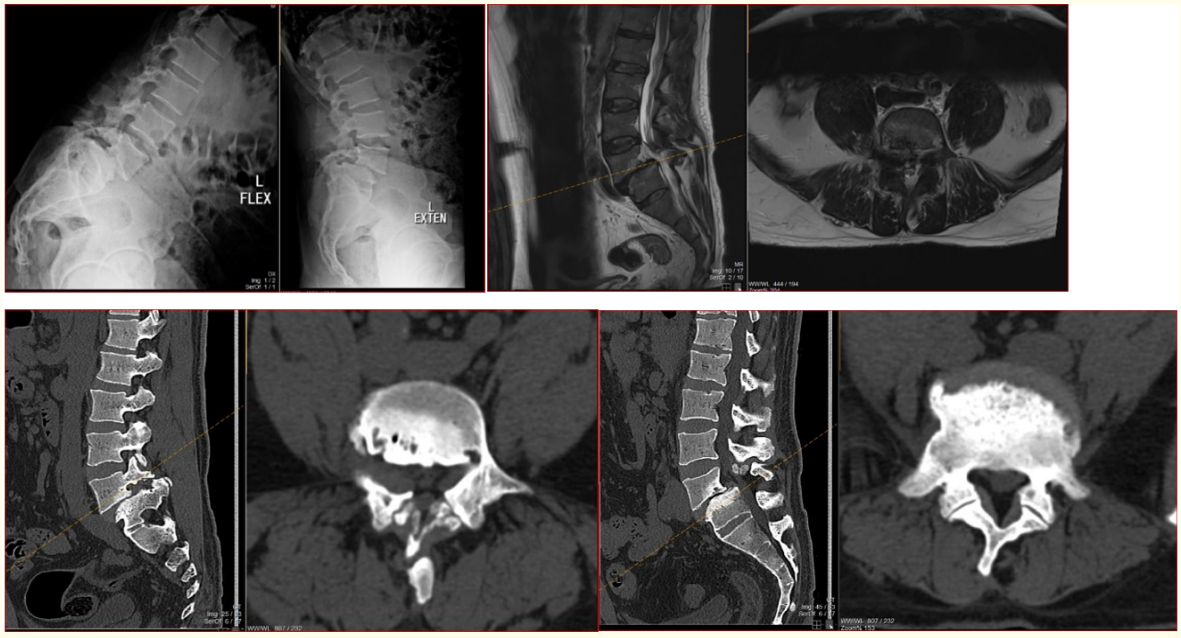

Figure A

Under General anesthesia and in usual prone position over the radiolucent table general anesthesia was administered with endotracheal intubation. Perioperative antibiotic prophylaxis was given according to our protocol. All bony prominences were well padded. The patient was prepared and draped for surgery in the usual sterile manner. A 6 cm midline skin incision is made and deep preparation were done according to the standard posterior lumbar approach until exposure of the Facet L4/5 with preservation of the Facet capsule and L5/S1 both sides. Bilateral defects of the L5 pars interarticularis were demonstrated and the instability of the L5 Lamina was verified. Starting with the pediculation of S1 followed by L5 for both sides. Then removing the spinous process and the lamina of the segment containing the pars defect of the fifth lumbar vertebra. Then the decompression of foramen both sides is completed and the L5 nerve root is exposed. Now starting with the Discectomy and preparation of the disc space between the L5/S1. Localization of the entry point with Penfield dissector. At this moment it was difficult to enter the involved disc space. Application of distraction using the rod distractor (Figure 3) which was used as an interspinous distractor of L4 and S1. We took care here to apply the distractor as ventral as possible in the spinous process to minimize the risk of local kyphosis during preparation of the Disc space. At the end of the preparation and removal

of the trail cage, the disc height is maintained by the interspinous distractor, hence we were able to insert the permanent Cage with bone graft. After the removal of the rod distractor we got very good reposition of the spondylolisthesis with good stability. Radiologically no signs of local kyphosis occur. At the end the rods on the pedicle screws were applied and the cups under compression were tightened to lock the cage and improve the lumbosacral lordosis.

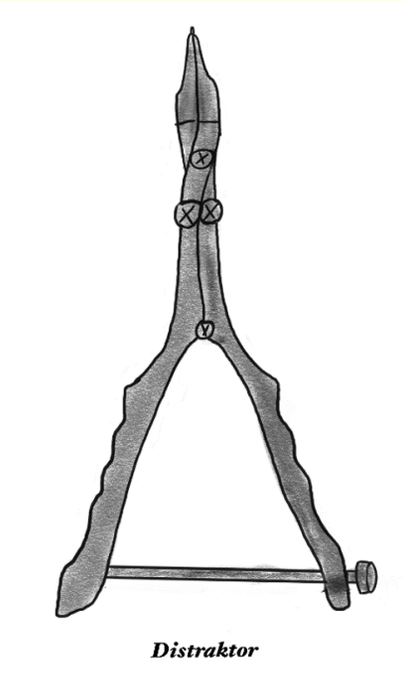

Figure 3

Figure B

Discussion

The above mentioned method of distraction was used; rather than other methods that are used to obtain distraction and perform interbody fusion as a distraction by using intradiscal spreaders, because there is less risk to injury the neural structures and the rod should not be tightened on the pedicle screws to maintain the reduction.

Distraction using pedicle screws can be used to open the disc space but may result in segmental kyphosis du to the big distance between the distraction point and the center of rotation of the functional spinal unit to be distracted.

Conclusion

The distraction of the spinous process above and below the slipped vertebra using interspinous distractor after removal of the posterior element can be used cautiously to facilite preparation of the disc space and insertion of the intervertebral cage.

Conflict of Interest

I did not received payments or services, either directly nor indirectly from a third party in support of any aspect of this work.

Bibliography

1. Gill GG., *et al.* "Surgical treatment of spondylolisthesis without spine fusion; excision of the loose lamina with decompression of the nerve roots". *Journal of Bone and Joint Surgery American* 37 (1955): 493-520.
2. Cloward RB. "Posterior lumbar interbody fusion updated". *Clinical Orthopaedics and Related Research* 193 (1985): 16-19.
3. Wiltse LL., *et al.* "Classifi cation of spondylolisis and spondylolisthesis". *Clinical Orthopaedics and Related Research* 117 (1976): 23-29.
4. Antoniades SB., *et al.* "Sagittal plane confi guration of the sacrum in spondylolisthesis". *Spine* 25.9 (2000): 1085-1091.
5. Laurent LE and Einola S. "Spondylolisthesis in children and adolescents". *Acta Orthopaedica Scandinavica* 31 (1961): 45-64.
6. Slim GP. "Vertebral contour in spondylolisthesis". *The British Journal of Radiology* 46.544 (1973): 250-254.
7. Boxall D., *et al.* "Management of severe spondylolisthesis in children and adolescents". *The Journal of Bone and Joint Surgery American* 61.4 (1979): 479-495.

Volume 12 Issue 10 October 2021