

Dislocation of the Inner Ball from the Head due to a Broken Ring after Bipolar Hip Arthroplasty in Three Patients

Hiraku Kikuchi^{1*}, Wataru Shimada¹, Sei Mihira¹, Jin Nakajima¹ and Narihiro Okada²

¹Department of Orthopaedic Surgery, Sakai Sakibana Hospital, Osaka, Japan

²Department of Orthopaedic Surgery, Sumoto Itsuki Hospital, Hyogo, Japan

*Corresponding Author: Hiraku Kikuchi, Department of Orthopaedic Surgery, Sakai Sakibana Hospital, Osaka, Japan.

Received: May 28, 2021; Published: June 08, 2021

Abstract

We encountered three patients in whom the inner ball was dislocated from the ring-type head after undergoing bipolar hip arthroplasty. In all three patients, the ring made of high-molecular polyethylene was dislodged from the inside of the outer head and could not hold the inner ball. In one of the three patients, the dislocation was left untreated for 18 months, causing metallosis and stem breakage. All three patients were treated surgically. In two patients, the broken ring was replaced with a new cup. In the other patients, because the stem was broken, the greater trochanter was removed, and the hip was totally reconstructed with a new hip prosthesis. We have already reported incidents to the manufacturer of the prostheses, which informally consented to improve them in the future.

Keywords: Dislocation; Broken Ring-Type Head; Bipolar Hip Arthroplasty

Abbreviations

BHP: Bipolar Hip Arthroplasty; BMI: Body Mass Index; HMP: High-Molecular Polyethylene

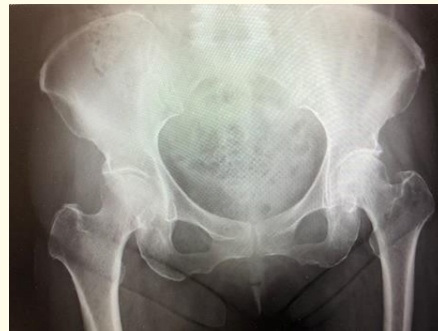Introduction

Since March 2015, hip arthroplasty with bipolar hip prosthesis (BHP) has been performed for femoral neck fractures and femoral head necrosis in 269 patients (21 men and 248 women; age, 58 - 104 years; mean age, 79 years) at our hospitals. At our hospitals, cementless BHP is selected for patients with adequate bone mass and cemented BHP is selected for patients with bone atrophy, bone fissures, or bone defects. The models used were Vector Titan (Peter Brehm, Germany) in 106 patients, and Muller type (Peter Brehm, Germany) BHP in 82 patients, Trifit and Trinity (Corin, England) in 70 patients, and others (Microport, USA) in 11 patients.

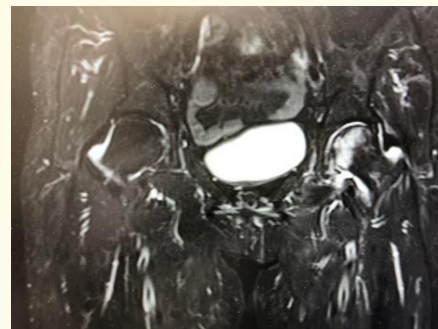
Case Presentation

Case 1: A 72-year-old woman had a height of 144 cm, weight of 54 kg, and body mass index (BMI) of 26.0. In September 2015, she had a left aseptic necrosis of femoral head (Figure 1A), which was caused by high-dose prednisolone therapy administered after steroid pulse therapy for anti-neutrophil cytoplasmic antibody-associated vasculitis and confirmed by a magnetic resonance image (Figure 1B). On May 8, 2016 (at the age of 67 years), the patient underwent replacement with the cementless Vector Titan BHP, which consisted of a stem

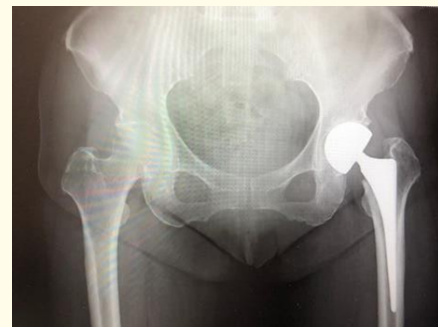(Size:S; Lot:61413-08), a cobalt chrome ball (φ 22 mm; Size: M; Lot:59334-51), and bipolar ring-type head (φ :41 mm; Lot: 59641-16) (Figure 1C). The postoperative follow-up was uneventful. However, on March 10, 2021, she twisted her hip joint when she tried to leave a low table with a heater attached. Consequently, hip joint pain occurred, and the patient was unable to stand. Imaging revealed dislocation of the inner ball (Figure 1D). The manual reduction was attempted but failed. As for medical treatment, prednisolone at a dose of 5 mg/day was continued. On March 12, the patient underwent surgery. Because the stem was intact, the inner ball and head were replaced with a new cobalt chrome ball (φ :22 mm: 59334-51) and a new bipolar ring-type head (φ :41 mm; Lot: 59641-16) (Figure 1E). This was the first case of dislocation of the inner ball due to a broken ring, in which the replacement was eventually repeated with an inner ball and an outer head of the same size. The pain was relieved immediately after surgery, and the patient was able to walk.



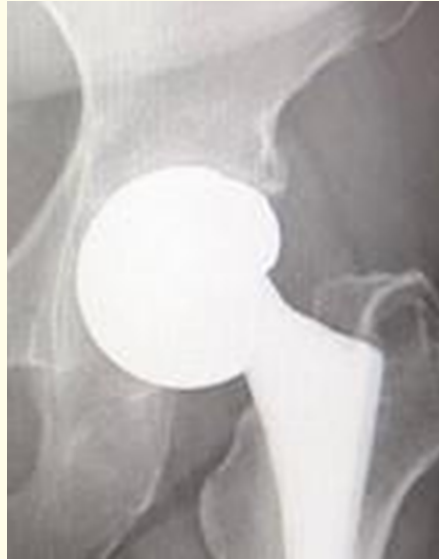1A



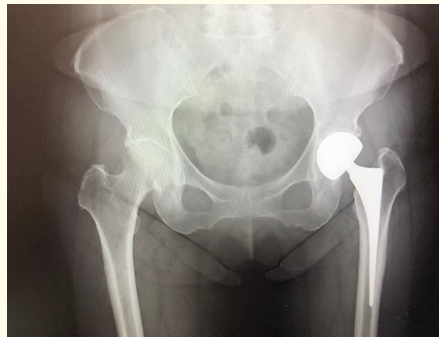1B



1C



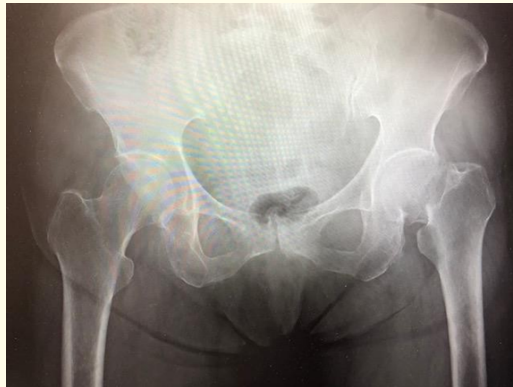
1D



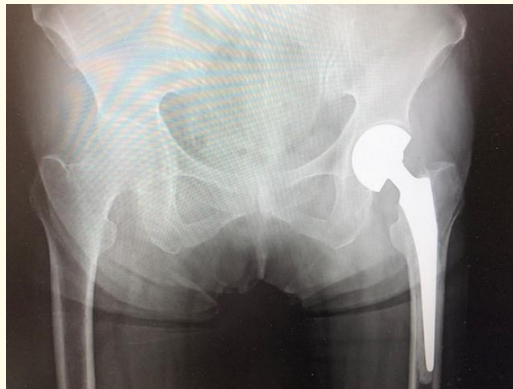1E

Figure 1A-1E: A: 72-year-old woman; a left aseptic necrosis of femoral head. B: A magnetic resonance image. C: On May 8, 2016, received with the cementless Vector Titan BHP. D: On March 10, 2021, dislocation of the inner ball due to a broken ring. E: Revision for same size of the new inner ball and head.

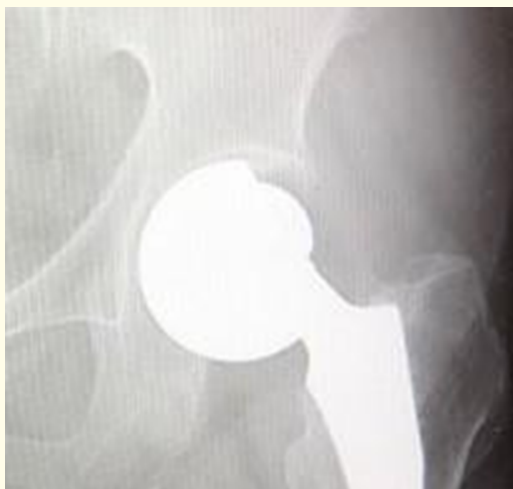Case 2: A 72-year-old woman had a height of 150 cm, weight of 55 kg and BMI of 24.4. On January 21, 2021, she fell from a bicycle and was brought to our hospital by ambulance. On January 29, a replacement for a left femoral neck fracture (Figure 2A) was performed with the cemented Muller type BHP, which consisted of a stem (Size:6.25 strait standard; Lot: 60800-5), a cobalt chrome ball (φ :28 mm; Size: S; Lot:59334-21) and a bipolar ring-type head (φ :44 mm; Lot:59648-18) (Figure 2B). On March 6, the patient was able to walk without assistance and was discharged without any problems. On April 6, the left hip joint pain occurred without any particular changes. Although the reduction failed under imaging guidance, no locking of outer head was detected. She was diagnosed with dislocation of the inner ball due to a broken ring (Figure 2C). This is the second case of this condition. On April 9, while the stem was retained, the inner ball and head were replaced with a new cobalt chrome ball (φ :28 mm; Size: S; Lot:59334-21) and a bipolar ring-type head with a size of 2 mm larger (φ :46 mm; Lot:59648-18) (Figure 2D).



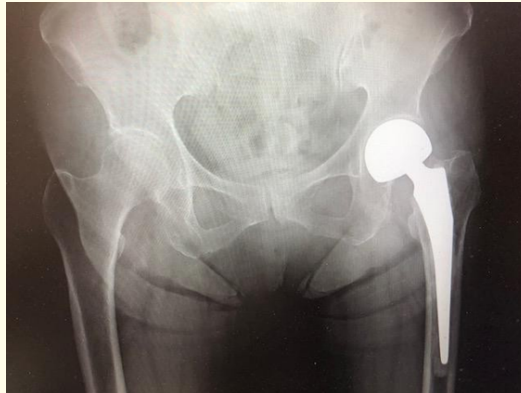2A



2B



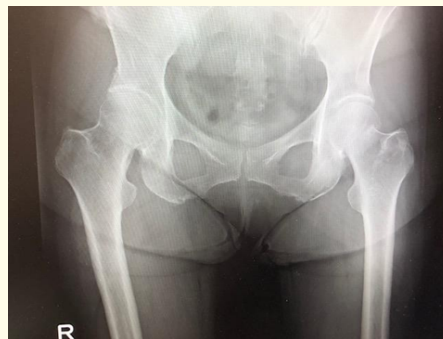2C



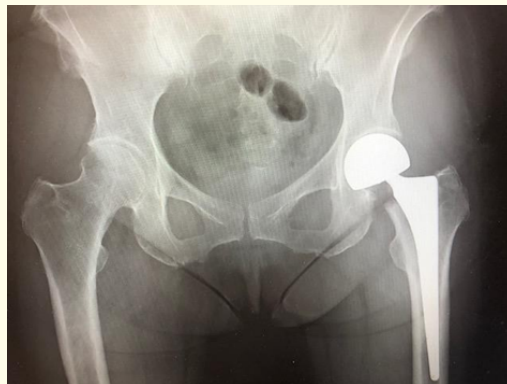2D

Figure 2A-2D: A: 72-year-old woman; a left femoral neck fracture. B: On January 29, 2021, received with the cemented Muller type BHP. C: On April 6, 2021, dislocation of the inner ball due to a broken ring. D: On April 9, 2021, revised for same size of the inner ball and larger head.

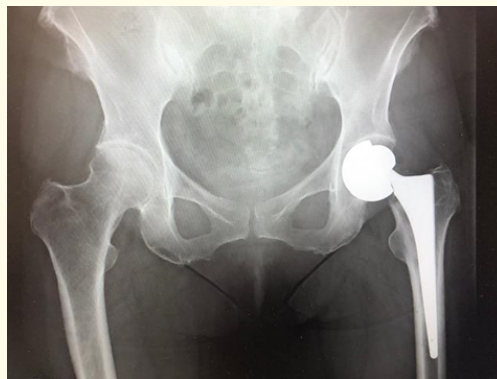Case 3: A 71-year-old woman had a height of 163 cm, weight of 75 kg and BMI of 28.2. On October 31, 2018, she fell from a bicycle and was brought to our hospital by ambulance. On November 2, a replacement for a left femoral neck fracture (Figure 3A) was performed with the cementless Vector Titan BHP, which consisted of a stem (Size: L; Lot 61403-08) a cobalt chrome ball (φ : 28 mm; Size: M; Lot: 59334-61/1), and a bipolar ring-type head (φ :45 mm; Lot: 59645-18) (Figure 3B). On November 22, she was able to walk without assistance and was discharged. On December 4, she experienced a right metacarpal bone fracture and hip pain (the third case of dislocation of the inner ball due to a broken ring (Figure 3C). However, because she found to have sigmoid colon cancer at the same time, cancer treatment was prioritized. On February 6, 2019, the patient under laparoscopic sigmoidectomy. Despite discomfort in the hip joint due to dislocation sustained during chemotherapy, the patient was able to walk. At the end of 2020, hip joint pain intensified. Although imaging revealed a broken stem (Figure 3D), she could walk without assistance. On May 7, 2021, after we explained to her, we removed the BHP and reconstructed the hip joint with cemented total hip arthroplasty (Peter Brehm, Figure 3E). The stem did not show any particular changes except for the broken neck portion and was firmly fixed in the femur. In the joint, the combined effects of metallosis and mechanical stimulation by hip dislocation contributed to the progression of bone joint destruction affecting the acetabulum to the acetabular rim.



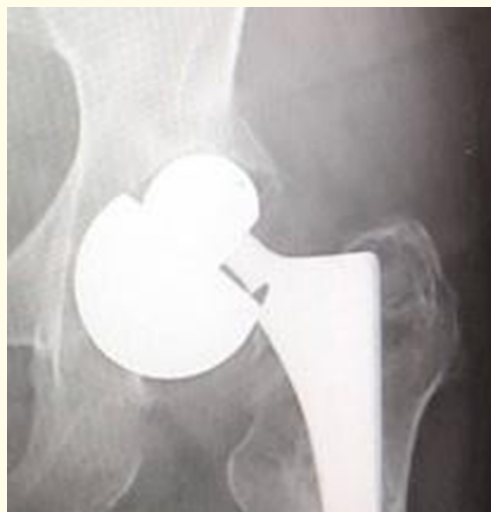3A



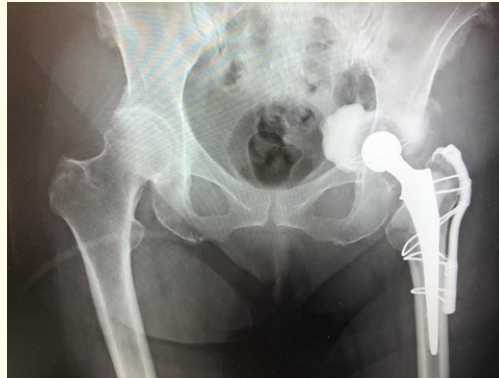3B



3C



3D



3E

Figure 3A-3E: A: 71-year-old woman; a left femoral neck fracture. B: On November 2, 2018, received with the cementless Vector Titan BHP. C: On December 4, 2018, dislocation of the inner ball due to a broken ring. D: At the end of 2020, hip joint pain intensified and revealed a broken stem. E: On May 7, 2021, reconstructed with cemented total hip arthroplasty.

Discussion

The BHP used for these three patients was manufactured by Peter Brehm. They accounted for 1.6% of the 183 patients (comparative test between this BHP and those of other manufactures showed no significant difference). When the outer head is fixed, the inner head dislocates as well as THA when stress is applied from the limit range of motion (Figure 1D, 2C and 3C) [1,2]. For the 22 mm and 28 mm inner balls manufactured by Peter Brehm, the thickness of the liner-high-molecular polyethylene (HMP) in the outer head is different. The liner HMP for the 28 mm inner ball was 3 mm thinner than that for the 22 mm inner ball for all size. Consequently, the 28 mm inner ball cannot be accommodated in cups measuring less than 45 mm (dates from Peter Brehm). Moreover, the HMP ring and inner cup, which are the components, are not treated with gamma-ray radiation and vitamin E to reinforce the crosslinking. Therefore, during impingement, the 28 mm inner ball presumably puts more load on the ring than the 22 mm inner ball. Meanwhile, no dislodgement of the inner ball occurred in any of the 81 patients for whom BHP manufactured by other companies was used during the same period. The use of the tapered one-piece type, instead of the ring type, for the fixation of the inner cup and inner ball seems to be an advantage of the BHP of other manufactures. While the number of people undergoing BHP for fractures increases because of the ageing population, this procedure is sometimes selected even for young people with femur necrosis or other conditions in Japan. In an increasingly ageing society, it is preferable to pay full attention to the selection of models in consideration of long-term outcomes.

Conclusion

Three (1.6%) out of 183 patients in whom the inner ball was dislocated from the ring-type head after undergoing bipolar hip arthroplasty (Peter Brehm, Germany). When the outer head is fixed, the inner head dislocates as well as total hip arthroplasty when stress is applied from the limit range of motion.

Acknowledgements

Special thanks for the director general Dr Keiji Inoue (Krijinn group).

Conflict of Interest

No potential conflict to this article was reported.

Bibliography

1. J Langlois., *et al.* "Intraprosthetic dislocation: a potentially serious complication of dual mobility acetabular cups". *Skeletal Radiology* 43 (2014): 1013-1016.
2. K Tanaka., *et al.* "A dislocation of the inner head in bipolar prosthesis with a self-centering system: a case report". *Journal of Nippon Medical School* 69.2 (2002): 192-195.

Volume 12 Issue 7 July 2021

©All rights reserved by Hiraku Kikuchi., *et al.*