

Does Resection of Anterior Tibial Plafond Bony Spur Influence the Postoperative Outcomes in Patients Undergoing Arthroscopic Surgery for Osteochondral Lesion of the Talus? Clinical Results and Second-Look Arthroscopic Evaluation

Yong Sang Kim and Yong Gon Koh*

Center for Stem Cell and Arthritis Research, Department of Orthopaedic Surgery, Yonsei Sarang Hospital, Seoul, Republic of Korea

***Corresponding Author:** Yong Gon Koh, Center for Stem Cell and Arthritis Research, Department of Orthopaedic Surgery, Yonsei Sarang Hospital, Hyoryeong-ro, Seocho-gu, Seoul, Republic of Korea.

Received: September 18, 2020; **Published:** October 31, 2020

Abstract

Introduction: The anterior tibial plafond bony spur, frequently observed when performing arthroscopic surgery for an osteochondral lesion of the talus (OLT), is usually resected during the arthroscopic procedure. The aim of the study was to evaluate the clinical outcomes after arthroscopic resection of anterior tibial plafond bony spur as an additional procedure in patients with OLT and to compare the outcomes in patients without bony spurs.

Methods: We reviewed 123 patients (129 ankles) who underwent arthroscopic treatments for OLT. The patients were divided into three groups according to the presence of anterior tibial plafond bony spur and whether second-look arthroscopy was performed: group 1 (76 ankles; without bony spur), group 2 (32 ankles; with bony spur and did not undergo second-look arthroscopy), and group 3 (21 ankles; with bony spur and underwent second-look arthroscopy). The visual analog scale, the American Orthopaedic Foot and Ankle Society score, and the range of movement were assessed for clinical outcomes, and patient satisfaction was recorded.

Results: The clinical outcomes and patient satisfaction improved significantly after primary arthroscopic treatment in all three groups. The clinical outcomes and patient satisfaction before second-look arthroscopy in group 3, which were significantly improved after second-look arthroscopy, were similar to those at the final follow-up in group 2. Significant correlations were found between clinical outcomes and adhesion at the bony spur resection site during the second-look arthroscopy in group 3.

Conclusion: This study demonstrates that adhesions developed at the bony spur resection sites caused less favorable clinical outcomes which can be resolved with arthroscopic adhesiolysis performed during second-look arthroscopy.

Keywords: Anterior Tibial Plafond Bony Spur; Adhesion; Osteochondral Lesion of the Talus; Second-Look Arthroscopy

Abbreviations

LOM: Limitation of Motion; OLT: Osteochondral Lesion of the Talus; ICRS: International Cartilage Repair Society; VAS: Visual Analog Scale; AOFAS: American Orthopaedic Foot and Ankle Society

Introduction

The presence of a bony spur on the anterior tibial plafond often induces anterior ankle bony impingement, causing limitation of motion (LOM) and ankle pain in forced dorsiflexion with joint stiffness [11]. The cause of pain is thought to be not only the bony spur itself but also a soft-tissue component that can be squeezed between the tibia and talus during dorsiflexion [19]. The bony spur on the anterior tibial plafond is frequently observed when performing arthroscopic treatment for an osteochondral lesion of the talus (OLT) and is usually resected during the arthroscopic procedure. However, even with improvement in the symptoms of OLT without any postoperative complications after arthroscopic treatment for OLT, patients often experience unexplained pain with LOM, which is shown as the other-

wise appearance compared to that of preoperative pain. Thus, we hypothesised that a specific factor related to the resection of the bony spur might be associated with ankle pain with LOM after an uncomplicated arthroscopic treatment in patients with OLT and attempted to investigate this factor with second-look arthroscopy. This study evaluated the clinical outcomes after arthroscopic resection of bony spurs on the anterior tibial plafond as an additional procedure in patients with OLT and compared the outcomes in patients without bony spurs. We also investigated the results of second-look arthroscopy in patients who underwent arthroscopic bony spur resection.

Materials and Methods

Patient enrollment

This study protocol was approved by the institutional review board of our hospital, and all patients provided written informed consent. We retrospectively reviewed the medical records of 181 consecutive patients (193 ankles) with a diagnosis of OLT who underwent arthroscopic treatments between May 2008 and February 2013. All patients had localized OLT with symptoms of ankle joint pain or functional limitations despite a minimum of 3 months of conservative management, including ankle bracing, physical therapy, and non-steroidal anti-inflammatory drugs. All patients underwent preoperative magnetic resonance imaging to confirm the diagnosis of OLT and identify the bony spur on the anterior tibial plafond. To avoid potential bias, an independent observer who was a musculoskeletal trained radiologist, not involved in the care of the patients and blinded to the intention of this study, evaluated the MRI films. Patients with a history of previous surgical treatments and patients with arthritic changes of their ankle joint or deformity of the axis of the ankle on conventional radiographs were excluded. Patients were also excluded if they underwent lateral ligament reconstruction concurrently with the arthroscopic treatments for OLT. Thus, of the 181 consecutive patients (193 ankles), 123 patients (129 ankles) were finally enrolled in this study. Of the 123 patients (129 ankles), a bony spur on the anterior tibial plafond was observed in only 51 patients (53 ankles), and 72 patients (76 ankles) did not have a bony spur on the anterior tibial plafond in their ankles at the time of the primary arthroscopic treatments for OLT. Bony spur on the anterior tibial plafond was confirmed through preoperative radiographs or magnetic resonance imaging scans before surgery, and all patients with bony spur had symptoms of anterior bony impingement. As a follow-up, we suggested to all patients that they undergo second-look arthroscopy, and we explained its purpose (evaluation of the OLT lesion and the need for additional arthroscopic procedures such as debridement, synovectomy, and/or adhesiolysis). Of the 123 patients (129 ankles), 64 patients (68 ankles) refused the procedure, and second-look arthroscopies were performed at a mean of 14.4 months (range, 11-18 months) post-operatively in 61 of the 129 ankles after written consents were obtained. The patients were divided into three groups (Figure 1). Group 1 included 72 patients (76 ankles) without a bony spur on the anterior tibial plafond. Among the 51 patients (53 ankles) with a bony spur on the anterior tibial plafond, 31 patients (32 ankles) who did not undergo the second-look arthroscopy were classified as group 2 and 20 patients (21 ankles) who underwent the second-look arthroscopy were classified as group 3. There were 59 men and 64 women. The mean age of the patients was 46.4 years (range, 23 - 63 years) and the mean duration of follow-up was 26.9 months (range, 24 - 41 months). There were no significant differences in basic characteristics among the three groups regarding age, sex, follow-up period, and preoperative clinical values (Table 1).

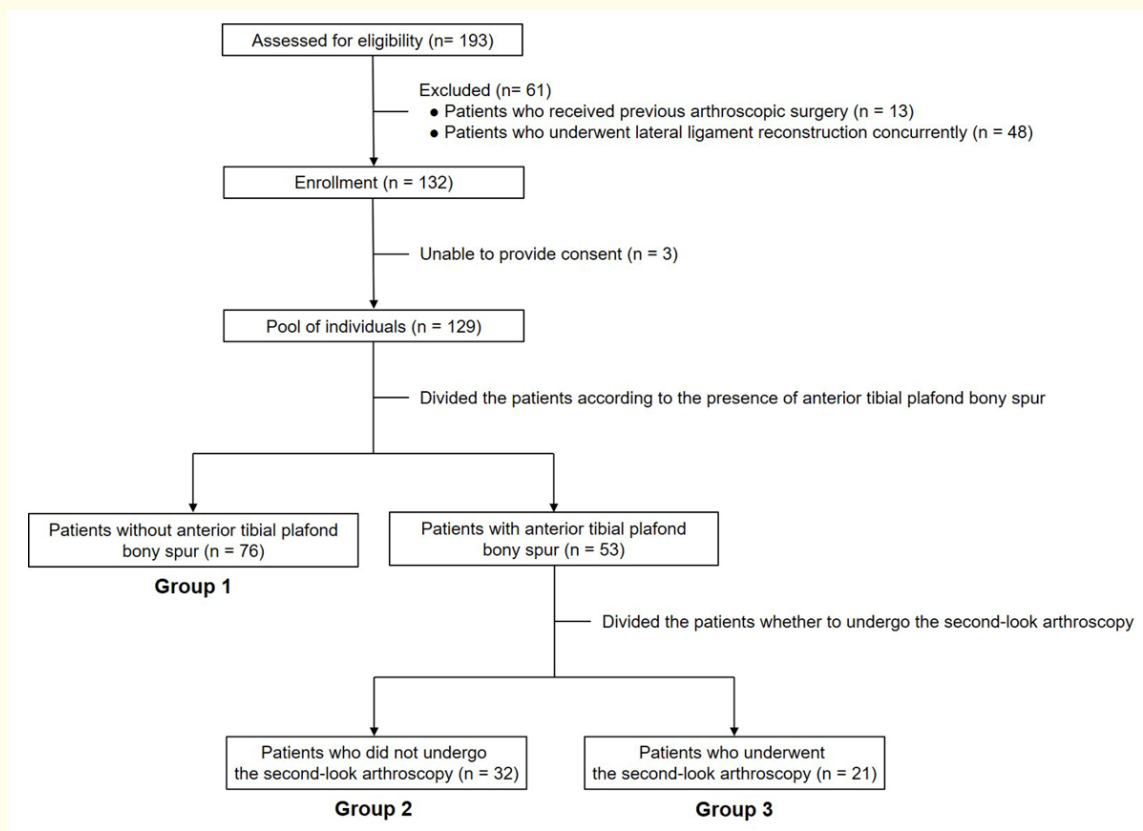


Figure 1: Flow diagram of patient involvement in the study.

Surgical technique

The patient was placed in the supine position under spinal anaesthesia. After applying the thigh tourniquet for haemostasis, non-invasive ankle distraction (15 lb) was applied using a harness. A 2.7-mm, 30°-angled arthroscope was introduced in turn through the standard anteromedial and anterolateral portals. The arthroscopic treatment for OLT was performed in a standardised manner as described by Steadman, *et al.* [16] in every case. In patients with bony impingement, the bony spur on the anterior tibial plafond was resected using an arthroscopic punch and bur (Figure 2). After the operation, we recommended tolerable weight-bearing activities for all groups of patients. Patients began both active and passive range-of-motion ankle joint exercises 4 weeks after the operation. Sports or high-impact activities were limited for at least 3 months.

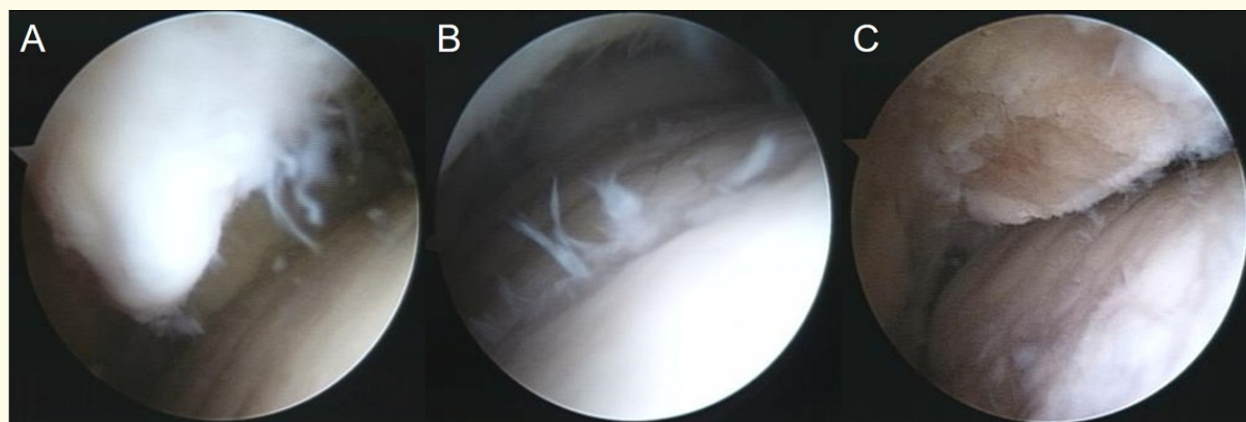


Figure 2: (A) Arthroscopic findings showing a bony spur on the anterior tibial plafond. (B) Tram-track lesion on talar dome due to the bony spur was observed. (C) The bony spur was resected during the primary arthroscopic treatment for osteochondral lesion of the talus.

In patients who underwent the second-look arthroscopy, additional arthroscopic procedures such as debridement of scar tissue, adhesiolysis, or synovectomy using an arthroscopic punch or power shaver were performed by the same surgeon if pathologic lesions were found in the ankle joint during the second-look arthroscopy (Figure 3). During the second-look arthroscopy, cartilage lesions which were treated with marrow simulation previously in primary arthroscopic treatments were macroscopically evaluated using the International Cartilage Repair Society (ICRS) [3] grade. Immediately after the second-look arthroscopic procedures, patients were allowed tolerable weight-bearing activities without immobilization.

Clinical and radiological evaluation

All patients were evaluated clinically and radiologically before surgery and as part of the follow-up. For clinical evaluation, a visual analog scale (VAS) for pain (0, no pain; 10, worst pain) and the American Orthopaedic Foot and Ankle Society (AOFAS) ankle-hindfoot score [8] were used, and the range of movement was measured with a goniometer. Patients also rated their overall satisfaction with the operation as 'very satisfied', 'satisfied', or 'not satisfied'. Weight-bearing anteroposterior and lateral radiographs were obtained for radiological evaluation before the surgery and during follow-up. On the lateral radiographs, we identified the bony spur on the anterior tibial

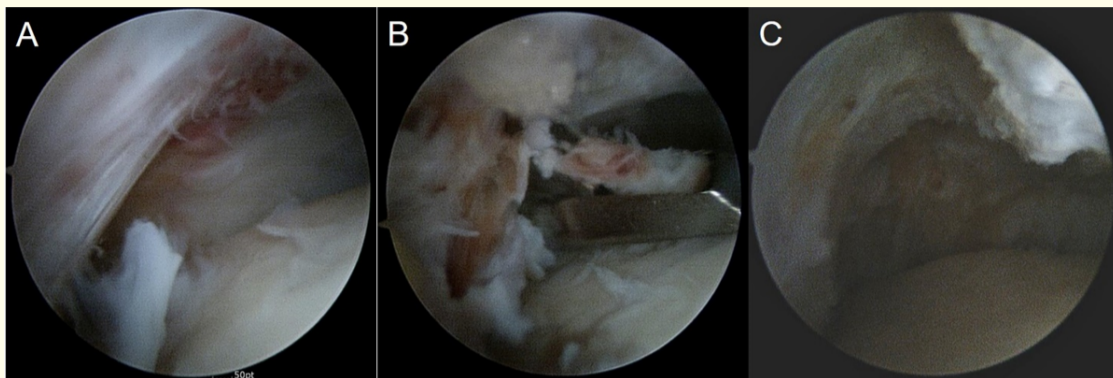


Figure 3: (A) Arthroscopic images showing the fibrous adhesion in the anterior aspect of the ankle. (B) Arthroscopic adhesiolysis was performed. (C) The adhesion was removed during the second-look arthroscopy.

plafond pre-operatively and confirmed the resected bony spur post-operatively. At serial follow-up examinations, the site of the resected bony spur was examined if it had recurred (Figure 4). The clinical and radiological evaluations were performed by single observer who was not involved in the care of the patients and blinded to the intention of this study.

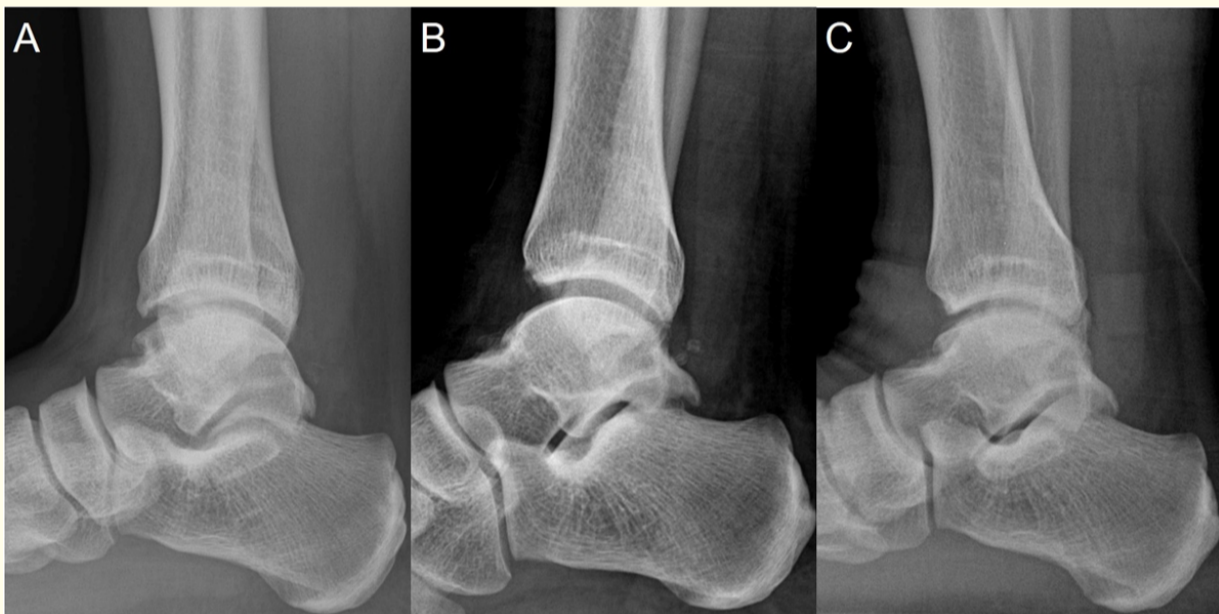

Figure 4: Serial weight-bearing lateral radiographs in a 47-year old-male patient. (A) Pre-operative radiograph showing the bony spur on anterior tibial plafond. (B) Postoperative radiograph revealing disappearance of the bony spur after resection of the lesion during the primary arthroscopic treatment. (C) Final follow-up radiograph showing no bony spur recurrence at 2 years after operation.

Statistical analysis

Descriptive statistics were calculated as mean \pm standard deviation. The Kruskal-Wallis test was performed for comparison of continuous variables among the three groups. A paired *t*-test (for group 1) or Wilcoxon signed rank test (for groups 2 and 3) was conducted for evaluation of changes in clinical outcomes before the primary or second-look arthroscopy and at the final follow-up. For multiple comparisons of clinical outcomes among the three groups, the *P* values were adjusted using the Bonferroni method. The adjusted *P* value is the minimum value of $P_{\text{observed}} \times k$ or 1, where P_{observed} is the unadjusted value and *k* is the number of comparisons. Fisher's exact test was used to compare patient satisfaction among the groups. We analysed the associations between adhesion and clinical outcomes before the second-look arthroscopy and at the final follow-up in group 3, and the Spearman rank-order correlation test was used to analyse the correlations of adhesion and ICRS grade with clinical outcomes before the second-look arthroscopy and at the final follow-up in group 3. Statistical analyses were performed using SPSS, Version 13.0 (IBM Corp., Armonk, NY, USA), and a *P* value < 0.05 was considered to indicate statistical significance.

Results

The clinical outcomes are shown in table 2. The mean VAS, AOFAS score, and range of movement improved significantly in all three groups at the final follow-up (*P* < 0.05 for all). When comparing the clinical outcomes at the final follow-up in group 1 versus 3, there were no significant differences between the groups. However, significant differences in the clinical outcomes at the final follow-up were found when comparing groups 1 versus 2 and 2 versus 3. Regarding the patient satisfaction, 69 patients (90.8%) in group 1, 22 (68.7%) in group

	Group 1 (n = 76)	Group 2 (n = 32)	Group 3 (n = 21)	P Value ^a		
				Group 1 vs. Group 2	Group 1 vs. Group 3	Group 2 vs. Group 3
VAS for pain						
Initial (before primary arthroscopic treatment for OLT)	6.7 ± 0.9	6.8 ± 0.7	7.1 ± 0.8	1.000	0.591	1.000
Before second-look arthroscopy			3.2 ± 0.7			
Final follow-up	2.4 ± 1.0	3.1 ± 0.8	2.2 ± 0.8	0.021	1.000	0.030
P Value ^b	< 0.001	< 0.001	0.001			
P Value ^c			0.020			
AOFAS score						
Initial (before primary arthroscopic treatment for OLT)	67.1 ± 5.7	67.4 ± 4.7	69.2 ± 5.5	1.000	0.747	0.978
Before second-look arthroscopy			76.1 ± 5.9			
Final follow-up	80.1 ± 5.3	75.0 ± 4.3	81.8 ± 8.0	0.003	0.453	0.006
P Value ^b	< 0.001	< 0.001	0.001			
P Value ^c			0.049			
Range of movement, °						
Initial (before primary arthroscopic treatment for OLT)	28.5 ± 3.3	29.7 ± 3.3	29.6 ± 3.7	0.615	0.909	1.000
Before second-look arthroscopy			32.5 ± 8.7			
Final follow-up	38.4 ± 4.1	35.0 ± 4.0	40.4 ± 4.6	0.027	0.486	0.012
P Value ^b	< 0.001	0.001	0.001			
P Value ^c			0.011			

Table 2: Comparison of clinical outcomes between groups.

Values are presented as mean ± standard deviation. VAS: Visual Analog Scale; OLT: Osteochondral Lesion of the Talus; AOFAS: American Orthopaedic Foot and Ankle Society.

^aThe P value adjusted for multiple comparisons using the Bonferroni method. The P value was the minimum value of $P_{observed} \times k$ or 1, where $P_{observed}$ was the unadjusted value and k was the number of comparisons ($k = 3$).

^bWilcoxon signed rank test for comparison of clinical outcomes at initial and final follow-up.

^cWilcoxon signed rank test for comparison of clinical outcomes before second-look arthroscopy and at final follow-up.

2, and 19 (90.5%) in group 3 were satisfied or very satisfied with the outcomes at the final follow-up (Table 3). The significant differences in patient satisfaction were found when comparing groups 1 versus 2 and 2 versus 3 ($P = 0.004$ and 0.033 , respectively). However, no significant difference was found between groups 1 and 3 ($P = 0.512$).

During the second-look arthroscopy, fibrous adhesions in the anterior recess were observed at the bony spur resection site in nine ankles of group 3, and arthroscopic adhesiolysis was performed accordingly at that time (Figure 3). Although the mean VAS, AOFAS score, and range of movement before second-look arthroscopy in group 3 were similar to the values at the final follow-up in group 2, after the arthroscopic adhesiolysis, the mean VAS, AOFAS score, and range of movement at the final follow-up in group 3 improved significantly compared with the values before second-look arthroscopy ($P = 0.020$, 0.049 , and 0.011 , respectively) (Table 2). Moreover, patient satisfaction improved significantly after second-look arthroscopic adhesiolysis ($P = 0.040$) (Table 3).

	Group 1 (n = 76)	Group 2 (n = 32)	Group 3 (n = 21)			P Value ^b		
			Before Second-Look Arthroscopy	Final Follow-up	P Value ^a	Group 1 vs.Group 2	Group 1 vs.Group 3	Group 2 vs. Group 3
Satisfaction, n (%)					0.040	0.004	0.512	0.033
Very satisfied	52 (68.4)	9 (28.1)	6 (28.6)	13(61.9)				
Satisfied	17 (22.4)	13 (40.6)	9 (42.8)	6 (28.6)				
Not satisfied	7 (9.2)	10 (31.3)	6 (28.6)	2 (9.5)				

Table 3: Comparison of patient satisfaction between groups.

^aFisher’s exact test for comparison of patient satisfaction before second-look arthroscopy and at final follow-up in group 3.

^bFisher’s exact test for comparison of patient satisfaction at final follow-up between groups.

The associations between adhesion and clinical outcomes before and after second-look arthroscopy are summarised in table 4. When the adhesion was present, the mean VAS, AOFAS, and range of movement were significantly improved after arthroscopic adhesiolysis during second-look arthroscopy (P = 0.006, 0.010, and 0.007, respectively). Moreover, significant differences were observed in VAS and range of movement before second-look arthroscopy according to the presence of adhesion (P = 0.029 and 0.002, respectively); however, there were no significant differences in VAS and range of movement after the arthroscopic adhesiolysis (P = 0.518 and 0.364, respectively). We analysed the correlations between adhesion and clinical outcomes before second-look arthroscopy and at the final follow-up in group 3. Significant correlations were found between adhesion and VAS as well as between adhesion and range of movement before second-look arthroscopy (P = 0.009 and 0.001, respectively) (Table 5). To investigate whether the status of repaired cartilage lesions after primary arthroscopic treatment for OLT might affect the clinical outcomes, we also analysed the correlations between ICRS grade and clinical outcomes before second-look arthroscopy and at the final follow-up in group 3. However, the status of the repaired cartilage lesions did not seem to have a significant influence on the clinical outcomes before second-look arthroscopy and at the final follow-up in group 3 (Table 5).

	Adhesion		
	Present (n = 14)	Absent (n = 7)	P Value ^a
VAS for pain			
Before second-look arthroscopy	3.6 ± 0.5	2.6 ± 0.5	0.029
Final follow-up	2.1 ± 0.8	2.4 ± 0.9	0.518
P Value ^b	0.006	0.564	
AOFAS score			
Before second-look arthroscopy	73.9 ± 4.9	80.0 ± 6.1	0.083
Final follow-up	82.2 ± 9.7	81.0 ± 4.2	0.364
P Value ^b	0.010	0.317	
Range of movement, °			
Before second-look arthroscopy	27.8 ± 6.7	41.0 ± 4.2	0.002
Final follow-up	39.4 ± 4.6	42.0 ± 4.5	0.364
P Value ^b	0.007	0.317	

Table 4: Associations between adhesion and clinical outcomes before second-look arthroscopy and at final follow-up in group 3.

Values are presented as mean ± standard deviation. VAS, visual analog scale; AOFAS, American Orthopaedic Foot and Ankle Society.

^aMann-Whitney U test.

^bWilcoxon signed rank test.

	Adhesion		ICRS grade	
	Spearman rho	P Value	Spearman rho	P Value
VAS for pain				
Before second-look arthroscopy	0.669	0.009	0.277	0.339
Final follow-up	-0.198	0.497	0.355	0.213
AOFAS score				
Before second-look arthroscopy	-0.514	0.060	0.203	0.486
Final follow-up	0.268	0.355	0.235	0.419
Range of movement, °				
Before second-look arthroscopy	-0.792	0.001	0.247	0.395
Final follow-up	-0.277	0.337	0.124	0.672

Table 5: Correlations of adhesion and ICRS grade with clinical outcomes before second-look arthroscopy and at final follow-up in group 3. Calculated using the Spearman rank-order correlation test. ICRS: International Cartilage Repair Society; VAS: Visual Analog Scale; AOFAS: American Orthopaedic Foot and Ankle Society.

At serial radiological follow-up examinations, no recurrence of bony spur was found in any of the patients in groups 2 and 3 (Figure 4).

Discussion

Although several studies have reported the results of bony spur treatment [1,4,7,11,15,22], published studies on the second-look arthroscopic findings after bony spur resection are rare. In this study, we hypothesised that a specific factor related to the bony spur on the anterior tibial plafond which was removed as an additional procedure during the arthroscopic treatment for OLT might be associated with post-operative ankle pain with LOM. Therefore, we attempted to identify this factor with the second-look arthroscopy and found that the adhesion which developed at the bony spur resection site was the reason for the less favourable clinical outcomes, which were significantly improved after the arthroscopic adhesiolysis performed during second-look arthroscopy. We also found significant correlations between adhesions and clinical outcomes. To the best of our knowledge, this is the first study that has evaluated the bony spur accompanied by OLT and has used second-look arthroscopy to identify the adhesion developed at the bony spur resection site to be associated with the clinical outcomes.

A bony spur on the anterior tibial plafond is one of the most common causes of anterior ankle impingement presenting as chronic pain on dorsiflexion of the ankle and restricted ankle motion [1,7,21]. Several hypotheses have been proposed to describe the aetiology of bony spur formation. One hypothesis is that repeated capsular traction while having the foot in a maximally plantar-flexed position may induce traction spur formation [9]. This hypothesis is supported by the fact that these spurs are frequently found in athletes who repetitively force their ankle in hyper-plantar-flexion actions, with repetitive traction to the anterior joint capsule [5,12]. The other hypothesis described by O’Donoghue [10] is that the bony spur is related to direct mechanical trauma associated with the impingement of the anterior articular border of the tibia and the talar neck during forced dorsiflexion of the ankle. Repeated impingement causes subperiosteal haemorrhages and subsequent bone growth [17]. According to this hypothesis, spurs develop along the anterior margin of the tibiotalar joint in association with damage to the anterior chondral margins which occur frequently in runners, dancers, and high jumpers [6]. Another hypothesis of spur development is recurrent microtrauma. In soccer players, spur formation is related to recurrent ball impact, which can be regarded as repetitive microtrauma to the ankle joint [18]. The bony spurs are located on the edge of the anterior joint surface cartilage, within the capsular envelope, where they develop secondarily to repetitive microtrauma and induce the bony anterior ankle impingement, causing pain which is probably not a result of the spur itself but of the inflamed soft tissue caught between the traction

spurs [19]. This microtrauma may be related to chronic ankle instability. Scranton, *et al.* [15] reported that the incidence of spurs was three times higher in a group with unstable ankle joints than a group without ankle instability. At any rate, patients with bony spur typically present complaining of a prolonged and persistent pain in the ankle with a history of a recent traumatic event and have increased pain after prolonged walking or physical activity [7]. Most patients with a bony spur in this study also had these typical symptoms of anterior ankle impingement in addition to the symptoms of OLT. Furthermore, in this study, concerning the relationship between chronic ankle instability and spur development as reported by Scranton, *et al.* [14], we excluded the patients who underwent lateral ligament reconstruction for chronic ankle instability concurrently with arthroscopic treatments for OLT (Figure 1) because we considered that the results of lateral ligament reconstruction might influence the outcomes at follow-up after bony spur resection.

Arthroscopic treatment of bony anterior ankle impingement is now well-described and provides a clear functional benefit, eliminating chronic anterior pain, and several studies have shown satisfactory short-term results after arthroscopic bony spur resection [15,18,22]. However, the results are prone to deterioration over time [4,21]. In this study, the clinical outcomes and patient satisfaction improved significantly after primary arthroscopic treatment in all three groups, and no bony spur recurrences were observed in follow-up radiographs in groups 2 and 3 (Figure 4). However, when comparing the clinical outcomes and patient satisfaction at the final follow-up in groups 1 versus 2 and 2 versus 3, there were significant differences between the groups. Moreover, the clinical outcomes and patient satisfaction before second-look arthroscopy in group 3, which were significantly improved after second-look arthroscopy, were similar to those at the final follow-up in group 2 (Table 2 and 3). We considered that there could be a specific factor related to these results and attempted to identify this factor with second-look arthroscopy. During the second-look arthroscopy, fibrous adhesion in the anterior recess was observed at the bony spur resection site in nine ankles of group 3 (Figure 3). We found that when the adhesion was present, the clinical outcomes improved significantly after arthroscopic adhesiolysis during second-look arthroscopy ($P = 0.006, 0.010$ and 0.007 respectively). Furthermore, there were significant differences in VAS and range of movement before second-look arthroscopy according to the presence of adhesion ($P = 0.029$ and 0.002 respectively), but these differences were not found after the arthroscopic adhesiolysis ($P = 0.518$ and 0.364 respectively) (Table 4). We also found significant correlations of adhesion with VAS and range of movement before second-look arthroscopy ($P = 0.009$ and 0.001 respectively) (Table 5). Also worth noting is that because we considered that the status of repaired cartilage lesions after primary arthroscopic treatment for OLT might affect the clinical outcomes, we analysed the correlations between ICRS grade and clinical outcomes before second-look arthroscopy and at the final follow-up in group 3. The status of the repaired cartilage lesions did not seem to have a significant influence on the clinical outcomes before second-look arthroscopy and at the final follow-up in group 3 (Table 5). Given these results, we believe that the adhesion which developed at the bony spur resection site was the reason for the less favorable clinical outcomes, which could be improved after the arthroscopic adhesiolysis performed during second-look arthroscopy.

Persisting pain after ankle surgery is often caused by development of intra-articular fibrous scars or adhesions. Russo, *et al.* [13] described that chondral and bone cell stimuli will initiate a repair reaction such as cartilage proliferation, scar tissue formation, and calcification, depending on the amount of damage. We considered that fibrous adhesion developed gradually as a result of the stimuli which occurred during and after the bony spur resection procedure. Although conventional radiography is valuable for diagnosis of bony impingement, it does not readily reveal the soft tissue impingement conditions. Thus, arthroscopy is an effective method for diagnosing and treating soft tissue impingement of the ankle [2]. In this study, fibrous adhesion in the anterior recess was observed at the bony spur resection site in nine ankles (64.3%) during second-look arthroscopy in group 3 (Figure 3), and after the arthroscopic adhesiolysis, the clinical outcomes (VAS and range of movement) improved significantly (Table 4). Therefore, we discerned that second-look arthroscopy would be useful for providing valuable prognostic information as well as treating such pathologic conditions.

Limitation of the Study

The present study had some limitations. First, it was retrospective and the small number of patients limited its significance. Especially, the number of patients undergoing second-look arthroscopic surgery (group 3) was small. However, through non-parametric analysis, improved clinical outcomes and patient satisfaction in group 3 equivalent to those of group 1 were observed. Second, the follow-up period

was short and second-look arthroscopy was performed at 14.8 months after the primary arthroscopic treatment. It is unknown whether the adhesion treated during second-look arthroscopy will develop again over time, and additionally, the changes in clinical outcomes at long-term follow-up cannot be predicted. Last, although we found no correlations between the status of repaired cartilage lesions after primary arthroscopic treatment for OLT and the clinical outcomes in group 3, it is unknown whether similar correlations exist in groups 1 and 2. In addition, there could be other intra-articular pathologic conditions such as synovitis influencing the clinical outcomes of arthroscopic treatments for OLT. Evaluation with a larger series of cases and a power analysis using second-look arthroscopy is necessary to evaluate the results of arthroscopic bony spur resection more precisely.

Conclusion

This study shows that adhesion developed at the bony spur resection site caused the less favorable clinical outcomes which can be resolved with arthroscopic adhesiolysis performed during second-look arthroscopy. An understanding of the results of this study will help patients with a bony spur on the anterior tibial plafond along with OLT to have more realistic expectations regarding the arthroscopic procedure.

Conflict of Interest

The authors declare that they have no conflict of interest.

Bibliography

1. Bauer T, et al. "Anterior Ankle Bony Impingement with Joint Motion Loss: The Arthroscopic Resection Option". *Orthopaedics and Traumatology: Surgery and Research* 96.4 (2010): 462-468.
2. Brennan SA, et al. "Arthroscopic Debridement for Soft Tissue Ankle Impingement". *The Irish Journal of Medical Science* 181.2 (2012): 253-256.
3. Brittberg M and L Peterson. "Introduction to an Articular Cartilage Classification". *ICRS Newsletter* 1 (1998): 5-8.
4. Coull R, et al. "Open Treatment of Anterior Impingement of the Ankle". *The Journal of Bone and Joint Surgery British* 85.4 (2003): 550-553.
5. Haller J, et al. "Mr-Imaging of Anterior Tibiotalar Impingement Syndrome: Agreement, Sensitivity and Specificity of Mr-Imaging and Indirect Mr-Arthrography". *European Journal of Radiology* 58.3 (2006): 450-460.
6. Hawkins RB. "Arthroscopic Treatment of Sports-Related Anterior Osteophytes in the Ankle". *Ankle and Foot* 9.2 (1988): 87-90.
7. Jacobson K, et al. "Arthroscopic Treatment of Anterior Ankle Impingement". *Clinics in Podiatric Medicine and Surgery* 28.3 (2011): 491-510.
8. Kitaoka HB, et al. "Clinical Rating Systems for the Ankle-Hindfoot, Midfoot, Hallux, and Lesser Toes". *Foot and Ankle International* 15.7 (1994): 349-353.
9. McMurray TP. "Footballer's Ankle". *Journal of Bone and Joint Surgery* 32 (1950): 68-69.
10. O'Donoghue DH. "Impingement Exostoses of the Talus and Tibia". *Journal of Bone and Joint Surgery American* 39-A.4 (1957): 835-852.
11. Parma A, et al. "Arthroscopic Treatment of Ankle Anterior Bony Impingement: The Long-Term Clinical Outcome". *Foot and Ankle International* 35.2 (2013): 148-155.

12. Robinson P and LM White. "Soft-Tissue and Osseous Impingement Syndromes of the Ankle: Role of Imaging in Diagnosis and Management". *Radiographics* 22.6 (2002): 1457-1469.
13. Russo A., et al. "Ankle Impingement: A Review of Multimodality Imaging Approach". *Musculoskeletal Surgery* 97.2 (2013): S161-168.
14. Scranton PE., et al. "Anterior Tibiotalar Spurs: A Comparison of Open Versus Arthroscopic Debridement". *Foot Ankle* 13.3 (1992): 125-129.
15. Scranton PE., et al. "The Relationship between Chronic Ankle Instability and Variations in Mortise Anatomy and Impingement Spurs". *Foot and Ankle International* 21.8 (2000): 657-664.
16. Steadman JR., et al. "Microfracture: Surgical Technique and Rehabilitation to Treat Chondral Defects". *Clinical Orthopaedics and Related Research* 391 (2001): S362-S369.
17. Stoller SM., et al. "A Comparative Study of the Frequency of Anterior Impingement Exostoses of the Ankle in Dancers and Nondancers". *Foot Ankle* 4.4 (1984): 201-203.
18. Tol JL., et al. "The Relationship of the Kicking Action in Soccer and Anterior Ankle Impingement Syndrome. A Biomechanical Analysis". *American Journal of Sports Medicine* 30.1 (2002): 45-50.
19. Tol JL and C N van Dijk. "Anterior Ankle Impingement". *Foot and Ankle Clinics* 11.2 (2006): 297-310, vi.
20. Tol JL., et al. "The Anterior Ankle Impingement Syndrome: Diagnostic Value of Oblique Radiographs". *Foot and Ankle International* 25.2 (2004): 63-68.
21. Tol JL., et al. "Arthroscopic Treatment of Anterior Impingement in the Ankle". *The Journal of Bone and Joint Surgery British* 83.1 (2001): 9-13.
22. Van Dijk CN., et al. "Medial Ankle Pain after Lateral Ligament Rupture". *The Journal of Bone and Joint Surgery British* 78.4 (1996): 562-567.

Volume 11 Issue 11 November 2020

©All rights reserved by Yong Sang Kim and Yong Gon Koh.