

## Magnetic Resonance Cartigram Sequencing in the Setting of Autologous Orthopedic Immunobiologics

Austin Yeargan\* and Brittany LaRussa

Regenerative Medicine Clinic, Wilmington, North Carolina, USA

\*Corresponding Author: Austin Yeargan, Regenerative Medicine Clinic, Wilmington, North Carolina, USA.

Received: December 26, 2019; Published: January 23, 2020

### Abstract

Magnetic resonance Cartigram® T2 wetmap sequencing (General Electric®, Chicago, IL) has the capability to diagnose appendicular degenerative joint disease with greater sensitivity and specificity than any other imaging modality. This diagnostic advantage has become particularly advantageous with the advancement of autologous orthopedic immunobiologics (AOI) in the orthopedic surgery over the last decade. No studies have been published where diffusion weighted sequences have been used in the setting of autologous biologic therapeutics. T2 wetmapping studies may perfectly compliment the screening process in orthopedic and neurosurgical patients who could be candidates for signaling cell procedures.

The imaging sequences are enabled by the natural metabolic consequences of the degenerative processes that occur during the biological life of human connective tissues. Proteoglycan is the major shock absorbing protein in joint cartilage and the spinal disks and has been likened to a sponge retaining water. The T2 wetmap sequences provide additional information concerning degenerative neurologic disease, metabolic musculoskeletal disease and degenerative orthopedic disease. Each of these can be identified earliest with T2 wetmap sequencing when combined with routine MR sequencing. In the setting of central nervous system disease, Apparent diffusion coefficient (ADC) and diffusion weighted imaging (DWI) sequences provide similar advantages to routine MR imaging and costs are negligible compared to the clinical advantage to the patient. Wetmap imaging has the power to define disease earliest when conservative measures are most likely to stop the advancement of the pathological process and even reverse it. Arthritis is a mechanically induced disease with sinister molecular consequences that are best visualized with wetmap sequencing. We review our clinical algorithm for management of patients with osteoarthritis who seek signaling cell-based treatments.

**Keywords:** MR Sequencing; Apparent Diffusion Coefficient (ADC); Diffusion Weighted Imaging (DWI); Orthopedic Immunobiologics

### Background

In response to gravitational load, water distribution is excluded by articular cartilage matrix remodeling where pillars of stiff collagens stacked against stiffening subchondral bone lead to a materials mismatch and pathologic force transfer across the tidemark. At the same time, the chondrocytes and chondroblasts that have clustered to oppose this challenging cyclic loading are producing less and lower quality proteoglycan, the normally hydrophilic matrix substance present in the ECM responsible for dissipating load vectors. Chondrocytes secrete their own matrix where additional metabolically active cells can migrate. Without unloading the joint, there is no active migration into the receding matrix front. The signaling environment begins to favor catabolism as the joint reacts through the immune

system relative to gravitational load. The extracellular matrix of the articular cartilage is no longer able to bear the load adequately against gravity and structural breakdown proceeds as a function of the immune system regulation of the cytokine environment that is generated. Naturally diminishing hydrophilicity of structural proteoglycan molecules in cartilaginous matrices in favor of the elaboration of stiff collagen constructs causes structural changes that unfavorably alter load transfer (Figure 1).

Cartigram® sequencing establishes a platform for complex mathematical manipulation of software algorithms that are able to favor earlier detection of cartilage abnormality through visualization of articular dessication that is consistent with loss of proteoglycan signaling and water retention. We use commercially available software packages from General Electric (CartiGram®, GE Healthcare Products, Chicago, Illinois) that is a T2 mapping sequence and processing utility used to non-invasively detect changes in the collagen component of the extracellular cartilage matrix. This technique acquires multiple echoes at different TE times at each slice location that represent different T2 weighting. The acquired data can be processed to produce T2 color maps which demonstrate more subtle changes in cartilage ultrastructure that are not visible on gray scale MR images and permit the clinician to make earlier, more accurate diagnoses that may affect surgical decision making that are critical in the setting of autologous orthopedic immunobiologics.

These studies are ideally suited for the early detection of appendicular joint pathology due to arthrosis and arthritis. The final destructive signaling molecular pathways are common between primary (RA) and secondary (OA) arthritis. Despite substantial pathobiological differences between these arthropathies, the hierarchical, imbalanced pro-inflammatory cytokine networks (HIPICNs) created are quite common, thus justifying the merging of these disorders mechanistically and suggesting that these common mechanisms exist in the onset and progression of different joint diseases [1].

As the result, the imaging procedure lends itself to patients suffering from joint pain without evident etiology on plain radiographs or other studies likely to be arthritis based on clinical evidence alone. From the time patients first present with knee pain, regardless of imaging findings, typically there is a four-year interval until full joint compartment destruction occurs. This is reflected by proteomic evaluation of articular aspirate noted previously. Typically, patients are only studied with radiographs and arthritis is managed expectantly and symptomatically until joint replacement is indicated. We believe that standard is no longer appropriate and that with the widespread use of MR wetmap cartigram imaging, the management strategies for knee arthritis need another look and additional design and development.

Earlier detection of these biochemical and structural changes may lead the way to establishing more evidence-based treatment options that prevent disease progression and limit future costs and disability, particularly with the emergence of autologous biologic signaling cell treatments. Signaling cell treatments, like the NAMAD† (Nanoplasty And Mechanical Axis Deviation) have become mainstream for degenerative, organic joint pain with over 700 clinics in the United States now claiming to offer ‘regenerative medicine’. Sadly, the vast majority are marketing clinic feigning expertise in orthopedic surgery. There is immunologic evidence that suggests these techniques may provide a novel solution to combat what was previously certain progression of joint destruction and organism disability. Cartigram® technology also plays a role in the validation of treatment techniques with modern autologous biologic applications in orthopedic surgery like arthritis where there is initially diminishing hydrophilic attraction to degenerative fragments of proteoglycan in the extracellular matrix, like keratan sulfate and chondroitin sulfate with degeneration.

We discuss the role of MRC in the setting of bone marrow aspirate/signaling cell concentrate techniques for orthopedic surgery with applications to arthritis and demonstrate examples of patients with arthritic joint disease. Autologous biologics are also emerging as a treatment for early stage disc and facet joint disease, which may change the natural history of both to a far more favorable outcome if loading is taken into consideration and modified. Based on risk profile and published outcomes, biologics should be integrated into the current standard of care in the management of bone and joint disease and have earned a place in the armamentarium of the orthopedic surgeon.

### Introduction

In 2008 approximately 100 million adults were affected by chronic, noncancer pain attributed to joint pain [2]. Chronic pain costs the nation over \$635 billion each year in medical treatment and lost productivity [3]. A large proportion of this pain and lost productivity comes from arthritis and related complications. Understanding the immunologic signaling cascades underlying the inflammatory processes and understanding how scientific models actually translate to clinical solutions are key to providing patients with their best potential biologic outcomes in the setting of signaling cell treatments.

Radiology and imaging play major roles in orthopedic and neurosurgery disciplines as well as many others. Orthopedic surgeons, neurosurgeons and radiologists have continued to develop imaging algorithms to determine cartilage deep tissue health [4-6]. These sequences provide clinicians with the first indicators of joint disease without contrast, when intervention is likely to be most successful and prove most durable [7].

### Pathophysiology of mechanical cartilaginous diseases

With cyclic loading against gravity, chondrocytes and chondroblasts align in organized clusters against gravity within the extracellular matrix (ECM). This process is mediated by cell-cell and cell to matrix protein signaling, known as mechanotransduction and mediated through specific protein receptors as well as integrins and cadherins. Primary cell surface receptors, like growth factor receptors may be

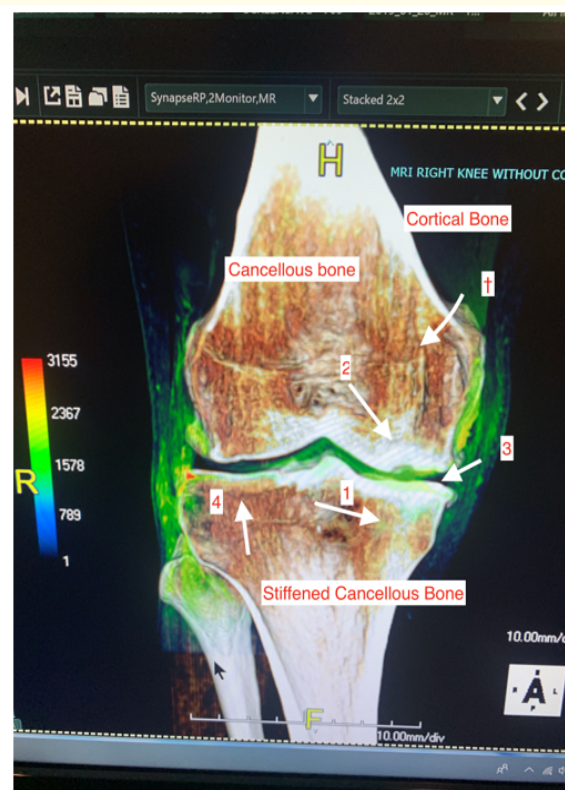
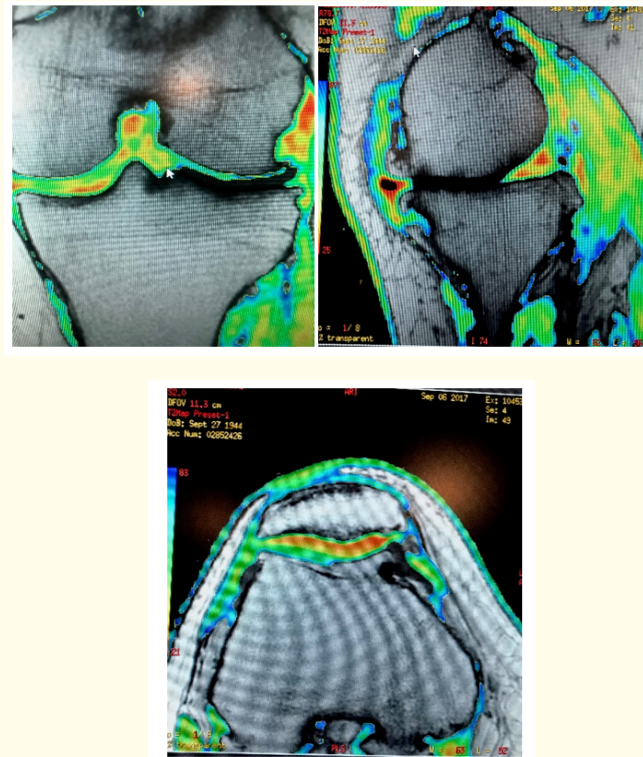
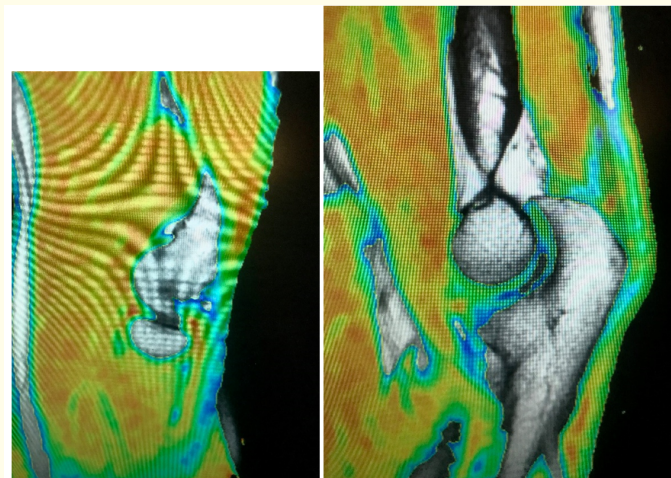


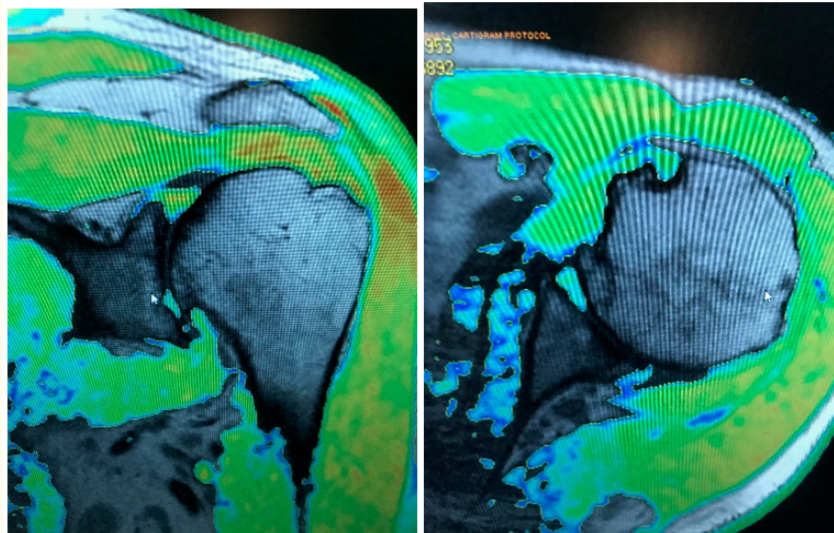
Figure 1: Order of arthritis in the knee joint from the concave side of the joint to the convex side of the joint. Terracon MRI sequencing.



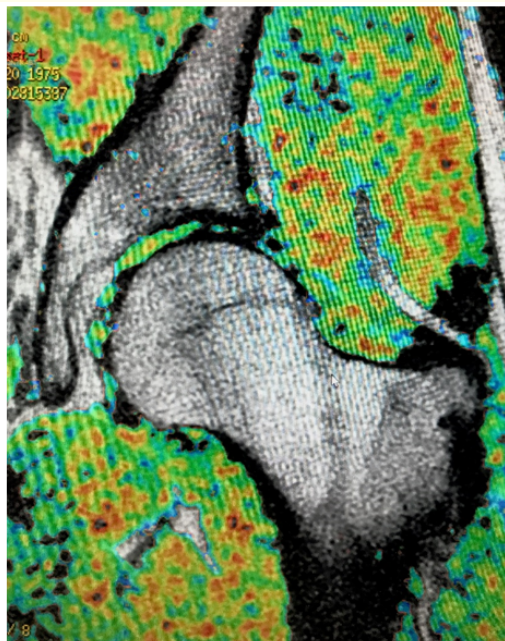
**Figure 2:** T2 Wetmap CartiGram® sequences of osteoarthritic knee in a 62 year old tennis player with intractable knee pain.



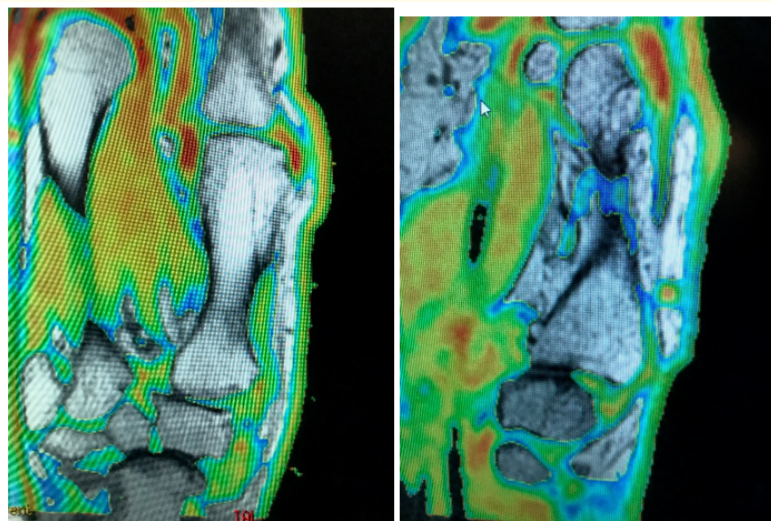
**Figure 3:** T2 Wetmap CartiGram® sequences of osteoarthritic elbow in an active 63 year old pickleball player with intractable elbow pain.



**Figure 4:** T2 Wetmap CartiGram® sequences of osteoarthritic shoulder in a 62-year-old surfer with intractable pain.



**Figure 5:** T2 Wetmap CartiGram® sequences of osteoarthritic hip in an active 76-year-old patient with intractable groin pain.



**Figure 5:** T2 Wetmap CartiGram® sequences of osteoarthritic pantrapezial disease in an active 70-year-old male sculptor.

Janus Kinase type that are aligned with second messenger NF-KB prompts. Second messengers can initiate a simple frameshift during transcription, that alters the proteome of the extracellular matrix and the joint fluid.

Reacting to cyclic loading versus gravity, the nanomolecular result is that the extracellular matrix of the cartilage begins to remodel and becomes stiff. This molecular phase occurs far in advance of the clinical ‘chondromalacia’ phase where very ‘soft’, yet mechanically inferior cartilage has yet to demonstrate gross degeneration or fragmentation. Proteoglycan transcripts and production diminish in zones where cartilage is overloaded, in favor of stiffer collagens, type I, IX and X. Mechanotransduction is the stimulus that occurs in reaction to gravity and drives bone and soft tissue remodeling in synovial joints.

### Management strategies

The Challenge in treating patients with arthritis and spondylosis is the early identification of patients at risk for chronicity and subsequently preventing progressive degeneration. Cartigram sequencing enables clinicians to establish an earlier, more accurate patient diagnosis, potentially limiting future disease. Identifying arthritis and degenerative disk disease at the earliest stage’s possible preserves tissues and cell matrices, making interventions easier on the patient and more cost effective with the elimination of most knee replacement surgeries. Decision-making may be affected drastically when information from DWI is taken into consideration, particularly in the setting of a unicompartamental osteoarthritis diagnosis.

Diffusion weighted MR imaging sequences contribute unique information without additional cost once the software package is loaded. The sequencing provides useful pre and postoperative information on disc degeneration and bone marrow changes for more accurate assessments of pathology and better treatment plans [8]. Similar findings on peripheral joint imaging with other commercially available T2 mapping sequencing at 3T have been reported, underscoring the value of the imaging study [9-12].

Identifying arthritis and degenerative disk disease at the earliest stage gives patients the benefit of understanding their prognosis and presents more opportunity for simple treatments. Identification of patients at earlier time points on the disease spectrum may facilitate

and enhance the ability of patients to take responsibility for the consequences of their treatment decisions. MRC could play a major role in arthroplasty protocols that are likely to be forthcoming with more cost-containment measures.

Intense investigation has improved our understanding of complex biomechanical and biochemical consequences of musculoskeletal disease, leading to a search for the best therapeutic molecular targets. Biochemical protein sequencing and magnetic resonance imaging have elaborated specific stages of disease, providing the opportunity to determine timing of intervention. The studies offer the capability to follow progression of disease versus response to treatment at the same cost as conventional MRI.

### Biologic therapeutics and signaling cell therapies

Autologous biologic cellular technologies have emerged as safe, viable options for the treatment of arthritic joint pain and disk disease. These applications have become popular and use will continue to grow. An aging population that is more active than their predecessors are demanding autologous biologic-based arthritic joint pain solutions that, unlike bionic solutions, will not limit their recreational and vocational pursuits and are viewed as natural solutions. Many if not most patients indicated for total knee arthroplasty are candidates for these procedures.

Bone marrow stimulating procedures and bone marrow concentrates demonstrate clinical utility and disease modifying capability in human and other animal models of arthritis [13-17]. Bone marrow MSCs are a heterogeneous population of adult stem cells with the ability to specialize along mesenchymal lines into cartilage, bone, fat, tendon and other mesodermal derivatives [18,19]. In spite of their clonal capability, it is their immune-modulating and anti-inflammatory effects that have been concluded to be responsible for their clinical efficacy. Environmental cues cause progenitor cells to respond heterogeneously through ligand-receptor binding mediated activation of nuclear second messengers that promote translation of functional proteins needed in response to the environmental cues. Soluble signaling proteins and platelet granules contain additional growth factors elaborated elsewhere and including but not limited to IGF and PDGF-bb. Cellular communication at the molecular level is complex and spatiotemporally based. The mesenchymal stem cells function as “medicinal signaling cells” through the molecular immune-signaling pathways that are the basis of human disease [20,21].

Autologous mesenchymal stem cell (MSC) transplantation is a safe, autologous procedure with proven clinical efficacy in relieving arthritic joint pain. The procedure is professionally completed in an hour and is essentially painless and bloodless when performed properly [22-24]. Bone marrow aspirate concentrates have proven scientifically safe to use, reliable and viable cellular products. The procedure is reproducible and based on immunomodulatory signaling and anti-inflammatory principles. The high costs of the procedure may limit more widespread use currently. Patient demand continues to grow rapidly in some areas of the United States in particular [25,26].

### Advanced imaging

There have been dramatic advances in targeted treatments enabling improved disease management and more efficient control of inflammation and joint disease [27,28]. The commercial availability of magnetic resonance imaging (MR) T2 wetmap and apparent diffusion coefficient (ADC) MR may signify the time for a paradigm shift in the management of orthopedic surgery and neurosurgery patients with arthritis and spondyloarthropathy respectively [29].

Quantitative MRI techniques can provide a metric by which to evaluate the efficacy of cartilage repair techniques and offer insight into the composition of cartilage and cartilage repair tissue [30]. Studies comparing T2 mapping before and after bone marrow concentrate injections into the knee joint and/or subchondral bone are lacking. These studies will yield important information when used as part of a controlled, routine, database driven protocol. No studies and no reviews have been published where diffusion weighted sequences have been used in the setting of autologous biologic therapeutics. T2 wetmapping studies may perfectly compliment the screening process in orthopedic and neurosurgical patients who could be candidates for signaling cell procedures. The imaging provides advantages defining

patient options and treatment planning and may prove useful in qualifying or eliminating patients as candidates for treatment with autologous biologics.

### Future Direction

The predictable molecular consequences that are closely intertwined with maladaptive physical joint changes may be reversed with autologous biologic treatments (Figure 7). Orthopedic surgeons and neurosurgeons must have a working knowledge of the immunological basis for treatment using biologics. Patient demand for the less invasive procedures with now proven efficacy is certain to increase particularly with the evolution of this technology that is still in its infancy. New biologics and biosimilars with diverse cellular effects continue to be produced using DNA recombinant technology for rheumatoid arthritis with excellent safety, efficacy, tolerability and immunogenicity [31].

Orthopedic surgery and neurosurgery, like the majority of medical and surgical subspecialties, are practiced and taught based on a clinically reactive strategy. Until now, preventative maintenance of the musculoskeletal system has been limited. Advanced imaging technology is now widely available that provides a distant early warning in the setting of organic joint disease. There are no added insurance or patient costs for the complete T2 wetmap imaging study compared to standard MRI sequences. The clinical information derived from the images reliably improves diagnostic accuracy and helps guide patients to more completely understand their options. In this context and acting in the best interest of the patient, physicians and surgeons must adapt a more proactive approach to the musculoskeletal disease condition. Biological science has now provided us with the knowledge and ability to naturally optimize the human experience at the endurance limits of the physical machine.

### Conclusion

Arthritis causes pain globally and results in great disability and lost time at work. This predictably progressive disease is typically detected at late stages, when results from treatment have been less successful, more invasive and more complicated. Reports have demonstrated that many patients have been able to defer or forego joint replacement or lumbar fusion when appropriately selected. This number would be higher with appropriate education and treatment standardization in molecular orthopedics. Most patients currently undergoing joint replacement could be candidates for autologous biologics and should be made aware of the techniques in the setting of informed consent for joint replacement. T2 wetmap imaging provides early insight into organic joint disease and arthritis that specifically directs clinical treatment and may help patients avoid late or salvage interventions like surgery. Applications of available and future biologic products will likely continue to enjoy larger roles in all medical specialties. With clinical application of available technology, knowing the patient's individual expectations and the specific recreational and vocational pursuits they intend to return to is vital to avoiding expectation/result mismatch.

We initially used bone marrow concentrates in the setting of chondral defects in 2005 and have experienced no significant complications in over a decade of safely performing the procedure. These molecular strategies have led to more significant and more durable clinical pain relief than initially expected [32]. Subchondral coring and signaling cell concentrate injection has greatly enhanced results and clinical durability of the immunobiologic procedure in our hands. Earlier diagnosis and treatment will likely continue to have a profound effect on patient outcomes. T2 wetmap sequencing combined with currently available and future autologous and pharmacologic disease modifying biologics represent the future of orthopedic and neurosurgical management of arthritis and spondylosis. Further study should focus on determining the long-term success and cost-effectiveness of signaling cell biologic procedures in multiple controlled settings.

### Bibliography

1. G Livshits and A Kalinkovich. "Hierarchical, imbalanced pro-inflammatory cytokine networks govern the pathogenesis of chronic arthropathies". *Osteoarthritis Cartilage* 26.1 (2018): 7-17.



2. MEPS Topics: Health Care Costs/Expenditures.
3. DJ Gaskin and P Richard. "Relieving Pain in America: A Blueprint for Transforming Prevention, Care, Education and Research". The economic costs of pain in the United States.
4. Ramappa A., *et al.* "MRI of microfractured chondral defects". *Journal of Knee Surgery* 20 (2007): 228-234.
5. F Su., *et al.* "Cartilage Morphology and T1rho and T2 Quantification in ACL Reconstructed Knees: A two year follow up". *Osteoarthritis Cartilage* 21.8 (2013): 1058-1067.
6. CR Chu., *et al.* "Quantitative Magnetic Resonance Imaging UTE-T2\* Mapping of Cartilage and Meniscus Healing after Anatomic Anterior Cruciate Ligament Reconstruction". *American Journal of Sports Medicine* 42.8 (2014): 1847-1856.
7. HJ Yu., *et al.* "In Vivo Quantification of Lumbar Disk Degeneration: Assessment of ADC Value Using a Degenerative System Based on Pfirrmann Framework". *European Spine Journal* 24.11 (2015): 2442-2448.
8. Gunnar Andersson. "New Imaging Technique to Improve Assessment of Surgical Patients with Lumbar Degeneration". *Spinal News International* 17.45 (2017): 1-2.
9. R Kijowski., *et al.* "T2 Mapping Sequence for Detecting Cartilage Lesion within the Knee Joint at 3.0T: Diagnostic Performance in 114 Patients with Surgical Correlation". *Proceedings of the International Society for Magnetic Resonance in Medicine* 20 (2012).
10. TJ Mosher and BJ Dardzinski. "Cartilage MRI T2 Relaxation Time Mapping: Overview and Applications". *Seminars in Musculoskeletal Radiology* 8.4 (2004): 355-368.
11. J Pan., *et al.* "Knee Cartilage T2 Characteristics and Evolution in Relation to Morphologic Abnormalities Detected at 3T MR Imaging". *Radiology* 261.2 (2011): 507-515.
12. TJ Mosher., *et al.* "Functional Cartilage MR T2 Mapping: Evaluating the effect of age and training on knee cartilage response to running". *Osteoarthritis Cartilage* 18.3 (2010): 358-364.
13. Frisbie DD., *et al.* "Arthroscopic subchondral bone plate microfracture technique augments healing of large osteochondral defects in the radial carpal bone and medial femoral condyle of horses". *Veterinary Surgery* 28 (1999): 242-255.
14. Frisbie DD., *et al.* "Effects of calcified cartilage on healing of chondral defects treated with microfracture in horses". *American Journal of Sports Medicine* 34 (2006): 18-24.
15. WJ Shi., *et al.* "Biologic Injections for Osteoarthritis and Articular Cartilage Damage: Can we modify disease?". *The Physician and Sports Medicine* 45.3 (2017): 203-223.
16. P Fernandez-Pemas., *et al.* "CD105+ Mesenchymal Stem Cells Migrate into Osteoarthritic Joint in the Animal Model". *Plos One* 12.11 (2017): 00188072.
17. SM Richardson., *et al.* "Mesenchymal Stem Cells in Regenerative Medicine: Focus on Articular Cartilage and Intervertebral Disk Regeneration". *Methods* 99 (2016): 69-80.
18. CA Sutton., *et al.* "The Wnt5a Receptor, Receptor Tyrosine Kinase-Like Orphan Receptor 2, Is a Predictive Cell Surface Marker of Human Mesenchymal Stem Cells, with an Enhanced Capacity for Chondrogenic Differentiation". *Stem Cells* 35.1 (2017): 2280-2291.

19. CJ Xian and BK Foster. "Repair of Injured Articular and Growth Plate Cartilage Using Mesenchymal Stem Cells and Chondrogenic Gene Therapy". *Current Stem Cell Research Therapy* 1.2 (2006): 213-229.
20. A Caplan. "Mesenchymal Stem Cells: Time to Change the Name!". *Stem Cells Translational Medicine* 6.6 (2017): 1445-1451.
21. Statement from FDA Commissioner Scott Gottlieb.
22. M Yubo., et al. "Clinical Efficacy and Safety of Mesenchymal Stem Cell Transplantation for Osteoarthritis Treatment: A meta-analysis". *Plos One* 12.4 (2017): e0175449.
23. YS Kim., et al. "Mesenchymal Stem Cell Implantation in Osteoarthritic Knees: Is fibrin glue effective as a scaffold?." *American Journal of Sports Medicine* 43.1 (2015): 176-185.
24. A Goldberg., et al. "The Use of Mesenchymal Stem Cells for Cartilage Repair and Regeneration: A systematic review". *Journal of Orthopaedic Surgery and Research* 9.12 (2017): 39.
25. SA Shapiro., et al. "A Prospective, Single-Blind, Placebo Controlled Trial of Bone Marrow Aspirate Concentrate for Knee Osteoarthritis". *American Journal of Sports Medicine* 45.1 (2017): 82-90.
26. E Kon., et al. "Clinical Outcomes of Knee Osteoarthritis Treated with Autologous Protein Injection: A 1-Year Pilot Double Blinded Randomized Controlled Trial". *American Journal of Sports Medicine* 46.1 (2018): 171-80.
27. FP Luyten., et al. "Contemporary concepts of inflammation, damage and repair in rheumatic diseases. Best Practices". *Research Clinical Rheumatology* 20 (2006): 829-848.
28. S Bajada., et al. "Updates on Stem Cells and Their Applications in Regenerative Medicine". *Topics in Tissue Engineering* 2.4 (2008): 169-83.
29. E Belykh., et al. "Apparent Diffusion Coefficient Maps in the Assessment of Surgical Patients with Lumbar Spine Degeneration". *Plos One* 12.8 (2017).
30. EC Argentieri., et al. "Magnetic Resonance Imaging of Articular Cartilage within the Knee". *Journal of Knee Surgery* (2018).
31. E Pelechas., et al. "ABP 501 for the Treatment of Rheumatoid Arthritis". *Expert Opinion on Biological Therapy* (2018):
32. T Turajane., et al. "Avoidance of Total Knee Arthroplasty in Early Osteoarthritis of the Knee with Intra-articular Implantation of Autologous Activated Peripheral Blood Stem Cells versus Hyaluronic Acid: A Randomized Controlled Trial with Differential Effects of Growth Factor Addition". *Stem Cells International* (2017): 8925132.

**Volume 11 Issue 2 February 2020**

**©All rights reserved by Austin Yeargan and Brittany LaRussa.**