

## The Outcome of Operation between Younger and Older than 12 Months for Development Dysplasia of the Hip

Nguyen Ngoc Hung<sup>1\*</sup>, Nguyen Do Ngoc Hien<sup>2</sup> and Hoang Hai Duc<sup>1</sup>

<sup>1</sup>Vietnam National Hospital for Pediatrics, Hanoi, Vietnam

<sup>2</sup>Hanoi Medical University, Hanoi, Vietnam

**\*Corresponding Author:** Nguyen Ngoc Hung, Associate Professor, Vietnam National Hospital for Pediatrics, Hanoi, Vietnam.

**Received:** April 10, 2019; **Published:** May 28, 2019

### Abstract

**Background:** Anterior open reduction approach to treat developmental dysplasia in the hip in children.

**Materials and Methods:** From 2008 to 2014, 141 hips of 127 patients with developmental hip dislocation underwent surgeries. The patients were divided into two variants based on age at the time of open reduction: 12 months - less than 18 months (Variation 1) and less than 12 months (Variant 2). There are 129 hips in V1 and 12 hips in V2. Patients with pre-surgery do not use traction of skin or bone, or femoral osteotomies. All patients with reduced surgery approach first. Dislocations are classified according to the Tönnis system. Acetabular indicators are commonly measured. Clinical evaluation of revised McKay criteria and Severin Roentgenographic evaluation.

**Results:** There are 99 (78.0%) patients who are girls and 28 (22.0%) are boys. Twenty-eight (19.9%) patients were bilaterally affected. The right hip in 23 (16.3%), and the left hip in 90 cases (63.8%). Tönnis Class: Tönnis 3 of 32 (22.7%), Tönnis. 4 out of 109 (77.3%). Patients were performed at an average age of 12.05 months (9 to 18) and the latest average follow-up age was 66.2 months (53 to 102), and the average follow-up period was 47.3 months. (31 to 64 months). Favorable general results 133 hips (94.3%) and unfavorable results 8 hips (5.7%). Roentgenographic results are 79.8%, Good 15.2%, Fair 3.5%, Poor 1.5%. There is Redislocation 11 (7.8%) and avascular necrosis 34 (24.1%).

**Conclusion:** This Operation is safe and effective. In the latest results, both Variations younger and Older than 12 months are not significantly different.

**Keywords:** Hip Dysplasia; Congenital Dislocation of the Hip; Innominate Osteotomy; Development Dysplasia of the Hip; Allograft

### Introduction

The main goal of treatment in developmental dislocations of hip joints is to obtain and maintain concentric reduction and stability for normal development of the hip joint. In young children, this can mostly be done by non-surgical methods. The goal of treating congenital hip dislocation (CDH) is to return the femoral head in the acetabulum and maintain this position until the pathological changes have reversed. Early reduction implies that there has been less adaptive change and reduced the time required for femoral head, acetabulum and capsule structure to return to normal configuration [1].

In general, everyone agrees that the closed reduction of hip joints in newborns should be tried first, but this will fail in a proportion of patients; some due to the intervention of soft tissue [2-4]. Persistence of subsequent conservative treatment may result in permanent defect joints.

The earliest age that open reduction can be safely done is controversial [5,6]. Chuinard 1972 [7] stated that the Law of Wolves withdraws from common operations; If this is true, the sooner the concentric reduction is, the better.

Normally, these hips will be repositioned in the cast and rearrangement may be necessary, often undergoing open reduction. The underdeveloped acetabular wall may be the result of the failure of Pavlik harness or improper use of Pavlik extraction treatment [8,9] or part of the acetabular dysplasia head [10,11].

Reduced open is necessary in children when concentric reduction and stability cannot be achieved by closed methods [12,13].

The age of the patient is one of the most important factors in determining treatment in dislocated hip joints. When surgery is indicated, while should only be reduced in children under 12 months of age (before walking) [14,15], acetabular or femoral procedures have been proposed at the time of open reduction, patients older than 18 months [15,16].

It is unclear in the literature whether a concurrent bone procedure is needed in children 12 - 18 months and dislocations of the hip. Although only reduced is recommended by a number of authors [4,15], others recommend performing bone surgery (acetabular, femur or both) at the time of open reduction [17,18].

We have reviewed our patients with developmental dislocations of hips that have undergone open reduction. The purpose of this study is to determine whether concomitant bone surgery is needed in a 12 - 18 month old patient treated with reduced intermediate open. Patients under 12 months of age at the time of open reduction are compared with patients 12 - 18 months.

The earliest age that open reduction can be safely done is controversial [5,6]. Chuinard 1972 [7] declared that the Law of Wolves withdraws from common operation; If this is true, the sooner the concentric reduction is better. Any subsequent X-ray or clinical evidence of instability leads to hospitalization for arthroscopic treatment and subcutaneous surgical removal under general anesthesia. If concentric reduction is achieved, the patient is placed in a plaster tube, but X-ray evidence of soft tissue replacement is a sign of reduced openness, regardless of the patient's age or bone status.

### Purpose of the Study

The purpose of this paper is to review our experience with the management of Congenital Dislocation of the hip in children in whom treatment was younger and older than 12 months with open reduction. Based on this experience, a safe and effective approach to this problem will be presented.

### Materials and Methods

Between 2008 and 2014, 141 hips of 127 patients with DDH underwent open reduction. 99 (78.0 %) of the patients were girls and 28 (22.0%) were boys. Fourteen (11.0%) patients were affected bilaterally. 113 (89.0%) patients were affected unilaterally. The right hip was involved in twenty three (18.1%) and the left hip in ninety (70.9%) cases (Table 1). Tönnis system type 3 in 23 hips (22.7%) and Type 4 in 109 hips (77.3%) hips.

Patients had teratologic dislocations, neuromuscular disorders and connective tissue, and patients with a history of a previous open hip procedure at another hospital were excluded from the study. Patients Tönnis grades I and II were excluded. Only patients presenting with grades III and IV were included in this study.

The operations were performed by a single surgeon (Author) and the evaluation by two independent orthopedic surgeons, who were not members of the department.

Informed consent was obtained from all participants. The study had the approval of the Ethical Review Committee of our Institute and was carried out in accordance with the tenets of the Declaration of Helsinki.

The patients were divided into two Variants based on the age at the time of OR: less than 12 months (Variant 1 - V1) and upper 12 months (Variant 2 - V2). There were 129 hips in V1 and 12 hips in V2. None had preoperative skin or skeletal traction, nor derotational varus or valgus osteotomies. The patient was performed at an average age of 12.05 months (9 to 18) and the average at latest follow-up was 62.2 months (53 to 102), and the average time follow-up was 43.7 months (31 to 64months).

Dislocations of the hip according to use Tönnis system [19]. The acetabular index was measured as common procedure to evaluate the correction of the acetabular dysplasia and the subsequent maintenance there of [20].

We elected not use the central-edge angle of Weiberg (CE angle), as the femoral heads in the majority of hips were partially ossified.

### Surgical technique

Total hips, the position of maximum stability was assessed at the time of OR. The hips which required flexion with abduction for stability and/or had an acetabular angle above 30° on the pre-operative radiograph, were judged to require an innominate osteotomy. If under general anesthesia could not abductor hip above 60° should adduction of mucusless tenotomy.

### Operation

#### Indication

All sides cannot be reduced or reduced without maintenance if there is no mandatory position (> 90, 100) or > 60 degrees of abduction) when examined without anesthesia. Traction force is not used in any patient. All patients were tested under general anesthesia. An indication that open reduction is the inability to reduce the hip with gentle manipulation or the inability to maintain it without a required position.

#### Surgical techniques

During the anterior approach, following sterile staining and draping under general anesthesia, the patient was laid down in the supine position while the hips were in flexion, abduction and external rotation. An approximately 4 cm long longitudinal incision was performed starting from 1.5 - 2.0 cm distal to the pubic tubercle and over adductor longus muscle.

Adductor tenotomy was performed passing through subcutaneous layers. A blunt entry was conducted through the muscle plane created placing adductor longus and brevis muscles in anterior and with adductor magnus and gracilis muscles in posterior. In deep plane, Lessertrochanter was palpated, and iliopsoas tendon was dissected from adhesion site to the lessertrochanter. Following, the joint capsule was exposed bluntly and revealed longitudinally from inferomedial aspect to expose the hip joint. At this stage, its avoided to injure medial circumflex artery and its branches. Ligamentum Teres tendon was excised and intra articular pulvinar tissue was removed. Following control of the reduction, only subcutaneous tissue and skin were sutured, the pelvipedal casting was applied to the hips in their most stable position. This stability was generally achieved in 30° - 40° abduction, 90° flexion and 10° - 15° internal rotation. Following totally 3 months application of casting, Dennis-Brown Bar was used during whole day and night for 3 months and then during only night time for 3 months.

If the hip was still unstable and in these Kirschner wires were used to maintain concentric reduction. The wire was passed through the greater trochanter and into the ilium (Figure 1).

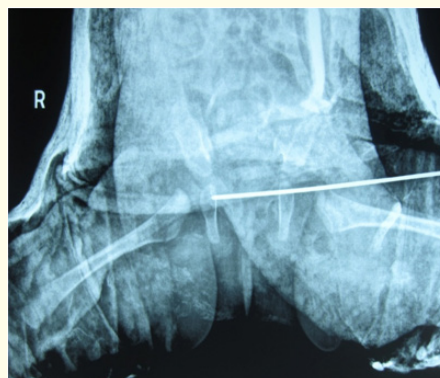
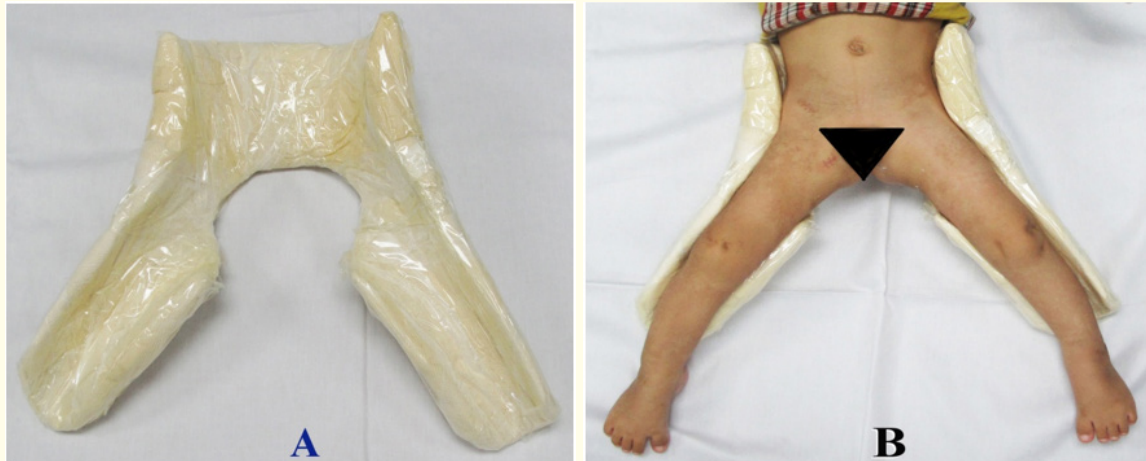

Figure 1: Kirschner wires was passed through the greater trochanter and into the ilium.

**Postoperative care**

The double spica cast was applied immediately after surgery, hip in 30°- 40° abduction, 90° flexion and 10° - 15° of internal rotation.

Three months after surgery, the entire cast is removed, and Patients is gradually weaned haft spica cast it only at night and nap time until acetabular development is normal. The haft spica cast (Figure 2) is usually worn for an average of 12 to 24 months after surgery.



**Figures 2A and 2B:** A: The haft spica cast; B: The patient is gradually weaned from the brace to wear haft spica cast it only at night.

A bilateral hip spica cast with the hips in human position was applied at surgery. Hip spica was maintained for 3 months and then a full-time abduction brace was used for 3 months. Afterwards, the brace was worn at night for an additional 3 months for a total brace time of 6 months.

**Evaluating Result**

The patients were scheduled to return to the outpatient clinic at three months intervals during the first time postoperatively 3 months, 6 months, 1 year, and 2 years after surgery and then at yearly intervals.

Patients were evaluated clinically for each visit such as the range of motion of affected hips, the quality of walking, the Trendelenburg test, and the presence of any pain.

Radiation of each hip was performed to assess quality of decline, AI, and presence or absence of AVN. The preoperative radiographic image of each patient was evaluated to determine the AI and the station.

Leg length variation can be measured by a physician during a physical examination and through X-rays. Usually, the doctor measures the hip level when the child is standing barefoot

Assessment of AVN of the femoral head was classified according to Kalamchi and MacEwen’s classification [21]: Grade 1: Changes affecting the ossific nucleus; Grade 2: Lateral physical damage; Grade 3: Central physical damage; Grade 4: Total damage to the head and physics.

Details of radiological classified according to the Severin [22] was used for the radiologic assessment of postoperative results: Grade 1: Normal; Grade 2: Moderate deformity of femoral head or neck or acetabulum; Grade 3: Dysplastic no subluxed; Grade 4: Subluxed; Grade 5: Head articulating with secondary acetabulum in upper of the original acetabulum; Grade 6: Dislocated; Grade 7: Arthritic.

Barrett’s modification of McKay’s criteria [16] was classified for the clinical assessment of postoperative results: Excellent result: Stable, painless hip, no limp, negative Trendelenburg sign, full range of motion; Good result: Stable, painless hip, slight limp, slight degree in range of motion; Fair result: Stable, painless hip, limp, positive Trendelenburg sign, and limited range of motion, or a combination of these; Poor result: Unstable or painful hip, or both, positive Trendelenburg sign.

**Statistical analysis**

The data were analyzed with Epi Info 6.04 software public domain statistical software for epidemiology, developed by Centers for Disease Control and Prevention (CDC) in Atlanta, Georgia, USA, <http://wwwn.cdc.gov/epiinfo/html/prevVersion.htm>. We performed the  $\chi^2$  test for percentage and the t-student test for mean comparison between the preoperative and postoperative groups. P-values less than 0.05 was regarded as statistically significant. All values were provided as mean values along with the appropriate standard deviation.

**Results**

There were 127 patients (141 hips) who had intraoperative instability and received an OR. Number patient: 127; Sex: Boy are 28 (21.9%), Girl are 99 (78.1%); Number hip: 129 hips (91.5%) in V1, 12 hips (8.5%) in V2, total: 141 hips; Side: Bilateral are 14 (11%), Left are 90 (70.9%), Right are 23 (18.1%); Tönnis grade: Tönnis 3 in 32 (22.7%), Tönnis 4 in 109 (77.3%).

	No. Patient	Sex		Side			Tönnis grade		Age at Operation (months)	Age La. F-U (months)	Time F-U
		Boy (%)	Girl (%)	Left (%)	Right (%)	Bilate. (%)	Tön. 3 (%)	Tön. 4 (%)			
Variant 1	115	25	90	80	21	14	28	101	14.4 (12 - 18)	69.7 (58 - 102)	41.8 (31-52)
			129 Hips (91.5)								
Variant 2	12	3	9	10	2	0	4	8	9.9 (9-11)	62.6 (53-74)	52.75 (43-64)
			12 Hips (8.5)								
	127	28 (22.0)	99 (78.0)	90 (70.9)	23 (18.1)	14 (11.0)	32 (22.7)	109 (77.3)	12.05 (9-18)	66.2 (53-102)	47.3 (31-64)
			141 Hips								

**Table 1:** Data of the patient.

No. Patient: Number Patients; Bilate.: Bilateral; Age La.F-U: Age at latest Follow-up;

Time F-U: Time Follow-up; Age La.F-U: Age at latest Follow-up; Time F-U: Long time Follow-up.

Number patient: 127; Sex: Boy are 28 (22.0%), Girl are 99 (78.0%); Number hip: 129 hips (91.5%) in V1, 12 hips (8.5%) in V2, total: 141 hips; Side: Bilateral are 14 (11%), Left are 90 (70.9%), Right are 23 (18.1%); Tönnis grade: Tönnis 3 in 32 (22.7%), Tönnis. 4 in 109 (77.3%). Age at Operation: 12.05 months (9 - 18 months). Age at latest Follow-up: 66.2 months (31 - 64).

Long time Follow-up: 47.3 months (31 - 64).

	No Hip	Surgical procedures							
		Adductor Tenotomy (%)	Ligament Teres (%)	Limbus (%)	Psoat Tendon (%)	Remove Puvinar (%)	Transverse Ligament (%)	Capsulorrhaphy (%)	Kirschner wire* (%)
Variant 1	129	112 (86.8)	119 (92.2)	113 (87.6)	129 (100)	129 (100)	115 (89.1)	112 (86.8)	129 (100)
Variant 2	12	12 (100)	12 (100)	11 (91.7)	12 (100)	12 (100)	12 (100)	12 (100)	12 (100)
P valuate		0.001611					0.3042		

**Table 2:** Details of anterior open reduction approach.

Kirschner wire\*: Kirschner wire was passed through the greater trochanter and into the ilium.

Variant 1/Variant 2: Adductor tenotomy in 112 (86.8%)/12 (100%); Cutting Ligament teres 119 (92.2%)/12 (100%); Cutting Limbus 113 (87.6%)/11 (91.7%); Tenotomy Psoat tendon 129 (100%)/12 (100%); Removed Puvinar 129 (100%)/12 (100); Removed Transverse Ligament 115 (89.1%)/12 (100%); Capsulorrhaphy 112 (86.8%)/12 (100%); Kirschner Wire\*: 129 (100%)/12 (100%).

	Number hip	Modified McKay criteria for clinical evaluation			
		Excellent (%)	Good (%)	Fair (%)	Poor (%)
Variant 1	129	98 (76.0)	24 (18.6)	5 (3.9)	2 (1.5)
Variant 2	12	8 (66.7%)	3 (25.0%)	0	1 (8.3%)
	141	106 (75.2)	27 (19.1)	5 (3.6)	3 (2.1)
P valuate					

**Table 3:** Modified McKay criteria for clinical evaluation [24].

V1/V2 with accepted result 122 hips (94.6%)/11 hips (91.7%) with P valuate > 0.05 (no significance. statistical), and none accepted 7 hips (5.4%)/1 hips (8.3%). Overall favorable result 133 hips (94.3%) and unfavorable result 8 hips (5.7%).

	Number hip	Severin criteria					
		Type I (%)	Type II (%)	Type III (%)	Type IV (%)	Type V (%)	Type VI (%)
Variant 1	129	102 (79.1)	20 (15.5)	0	5 (3.9)		2 (1.5)
Variant 2	12	5 (41.7)	4 (33.3)	2 (16.7)	1 (8.3)	0	0
		107 (75.9)	24 (17.0)	2 (1.4)	6 (4.3)	0	2 (1.4)

**Table 4:** Deformity of femoral head or neck or acetabulum according to Severin [23].

V1/V2 with favorable result 122 hips (94.6%)/9 hips (75.0%) and none favorable 7 hips.

	Redislocation	Avascular necrosis (%)	Coxa magna (%)	Coxa vara (%)	Fracture (%)	Trendelenburg gait (%)	Infection (%)	Limb Discrepancy (%)
V1 n= 129	10 (7.8%)	33 (25.6)	3 (2.3%)	3 (2.3%)	2 (1.6%)	3 (2.3%)	0	10 (7.7)
V2 n= 12	1 (8.3%)	1 (8.3)	0	0	0	1 (8.3%)	0	
Overall	11 (7.8%)	34 (24.1)	3 (2.1)	3 (2.1)	2 (1.4)	4 (2.8)	0	10 (7.1)
P valuate		0.325494						

**Table 5:** Complications.

Complications: 1) Redislocation: 11 (7.8%); 2) Avascular necrosis: 34 (24.1%); 3) Coxa magna: 3 (2.1%) 4) Coxa vara: 3 (2.1%); 5) Fracture: 2 (1.4); 6) Trendelenburg gait: 4 (2.8%); 7) Infection: 0 (0%); 8) Limb Discrepancy: 0 (%).

Redislocation V1/2 with P valuate > 0.05 (no significance. statistical), and AVN V1/2 with P valuate > 0.05 (no significance. statistical).

	Mean follow-up	Age (months)	Number of hips	Subsequent bony surgery	Avascular necrosis	Severin 3 and 4
Koizumi., et al. [25]	18.7 years	< 12	14	28% (4/14)	64% (9/14)	71% (10/14)
Castillo., et al. [26]	81 months	< 12	13	0% (0/13)	8% (1/13)	8% (1/13)
Konigsberg., et al. [27]	11 years	< 12	34	15% (5/34)	23% (8/34)	20% (7/34)
Roose., et al. [28]	31 months	< 12	15	13% (2/15)	0%	NR
Hung (In this study)	52.75 months	< 12	12	8.3% (1/12)	8.3% (1/12)	8.3% (1/12)

**Table 6:** The results of previous studies.

Age at Operation: < 12 months; Number of Hips 12 - 34. Subsequent bony surgery: 0 - 28%; AVN: 8 - 64%; Severin 3 and 4: 8 - 71%.

	Mean follow-up	Age (months)	Number of hips	Subsequent bony surgery	Avascular necrosis	Severin 3 and 4
Koizumi., <i>et al.</i> [23]	20.6 years	≥ 12 - 18	11	36% (4/11)	27% (3/11)	36% (4/11)
Castillo., <i>et al.</i> [24]	86 months	≥ 12 - 18	10	60% (6/10)	20% (2/10)	40% (4/10)
Konigsberg., <i>et al.</i> [25]	10 years	≥ 12 - 18	6	50% (3/6)	50% (3/6)	50% (3/6)
Roose., <i>et al.</i> [26]	28 months	≥ 12 - 18	7	43% (3/7)	0%	
Isiklar., <i>et al.</i> [27]	21 years	≥ 12 - 18	23	39% (9/23)	13% (3/23)	22% (5/23)
Hung (in this study)	41.8 months	≥ 12 - 18	129	7.8% (10/129)	25.6% (33/129)	5.4% (7/129)

**Table 7:** The results of previous studies.

Age at Operation: ≥ 12 - 18 months; Number of Hips 6 - 129. Subsequent bony surgery: 7.8 - 60%; AVN: 13 - 50%; Severin 3 and 4: 5.4 - 50%.

	Mean follow-up	Age (months)	Number of hips	Subsequent bony surgery	Avascular necrosis	Severin 3 and 4
V 1	41.8 months	≥ 12 - 18	129	7.8% (10/129)	25.6% (33/129)	5.4% (7/129)
V 2	52.75 months	< 12	12	8.3% (1/12)	8.3% (1/12)	25% (3/12)

**Table 8:** The results of previous studies.

## Discussion

### Age at operation

Statistical analysis using the squared test and Student t-test showed a significant correlation between the age of activity and the final outcome. Children treated before age two are more likely to do better (p = 0.01), as well established in world literature. The results of activities performed before 12 months of age (before the appearance of the capital femoral epiphelium) were significantly better (p = 0.01) than those performed between the ages of 12 and 24. month (after the appearance of the capital femoral procedure) [28]. In 11 patients (16 hips) who had opened open before six months of age, only one hip joint had avascular necrosis. It seems the results are better after reducing the opening sooner, regardless of the patient’s age or the fossil state of the capital. However, we have not found the necessary open reduction in patients under four months of age [28] (Table 1).

### Open reduction

Reducing hip joint anatomy and maintaining reduction to provide the normal development of the femoral head and acetabulum is the main goal in all types of treatment in DDH, regardless of age [19,29]. It is known that a tight iliopsoas tendon and hip joint addictive substances are the main factors outside the joint and a poorly lasting joint follicle. In this study, we performing Variant 1/Variant 2: Adductor tenotomy in 112 (86.8%)/12 (100% ); Cutting Ligament teres 119 (92.2%)/12 (100%); Cutting Limbus 113 (87.6%)/11 (91.7%); Tenotomy Psoat tendon 129 (100%)/12 (100%): Removed Puvinar 129 (100%)/12 (100); Removed Transverse Ligament 115 (89.1%)/12 (100%); Capsulorrhaphy 112 (86.8%)/12 (100%); Kirchner Wire\*: 129 (100%)/12 (100%) (Table 2).

Tight horizontal cross ligaments, long ligaments and abnormal hypertrophy, labrum inversion and extended pulvinar are the most common factors to prevent concentric reduction in DDH [19,29]. Based on this classic knowledge, we propose that tight iliopsoas and sub-ribs, with longus as the primary additive, always require segmentation to obtain concentric reduction in treatment of unstable hips. but cannot be treated with age-restricted braces their use. Our data show that even after releasing two major joint barriers, a concentric reduction recorded by endoscopic methods cannot be achieved near half of the hip. It is clear that this ratio must be higher at the initial treatment by reducing the closure by different techniques. The algorithm presented seems to be a more active treatment for closed

reduction, but it can be considered a limited surgical procedure because it is not always necessary to open it. In this algorithm, in case of concentric reduction in writing, there is no need to reduce the opening or advancing one more unnecessary step. However, the superiority of this limited surgery Close-down reduction procedures can usually only be understood after conducting a prospective randomized study. We think that the long-term results are not acceptable for the two studies Support our proposal for regular need to cut iliopsoas tendons during the reduction of dislocated hips. Koizumi, *et al.* [23] reported high rates of long-term unacceptable (an average of 20 years) x-ray results (54%) and AVN (43%, excluding mild AVN) in hips of dysplasia treated by reducing the anterior opening without dividing iliopsoas. Malvitz and Weinstein [30] evaluated the results of 119 adult patients on the skeleton treated initially by reducing closure by various techniques. Forty-six percent of hips have X-ray results were satisfactory and 60% had a growth disorder of the femur after 30 years of follow-up (Table 3).

Ferguson [31,32] claims that there is no need to cut or remove cross ligaments or cross ligaments to achieve concentric reduction after follicle removal posterity approach. We believe that if it is necessary to reduce the opening, the cross ligament must be cut and the ligament is removed. We observed that Reverse labrum is a barrier to concentric reduction only at the hips in which the joint capsule has not been opened. Natural labrum reverse automatic recording documents ejected after performing the previously mentioned intracranial soft tissue release at all hips. Therefore, labrum incision to concentrate the femoral head in the opening process seems to be unnecessary in this age group.

Our results show that the need to reduce openness after longus and iliopsoas supplements is directly related to the degree of preoperative dislocation. With the numbers available in the current study, we can say that the higher the degree of pre-surgery dislocation, the less likely the concentric reduction without opening the hip joint despite the tendency of release and need reduce open. In this study, V1/V2 with accepted result 122 hips (94.6%)/11 hips (91.7%) with *P valuate* > 0.05 (no significance. statistical), and none accepted 7 hips (5.4%)/1 hips (8.3%). Overall favorable result 133 hips (94.3%) and unfavorable result 8 hips (5.7%).

It is known that AVN is an iatrogen complication. In our opinion, the main reason is that inadequate soft tissue release leads to increased intra-articular pressure after reduction, rather than an intermediate method. During the surgical procedure presented, there were no extra-tissue or endothelial soft tissue barriers during the reduction at all sides, and the rate of early AVN, leading to considerable femoral head deformity, was only first%.

The Iowa group [33,34] performed an open reduction in combination with iliopsoas and tenotomies supplemented through a transverse incision and performed laparoscopic surgery after surgery to remove the supplement but before removing the appendage. iliopsoas. The surgical approach and the time of radiography in Iowa studies differ from our study. Lehman [35] approached the hip joint by using both the anterior and posterior incisions, performing a closed reduction under fluorescent control without endoscopic surgery, after iliopsoas tendon excision and opening of the follicle If the closing is not successful. Surgical methods and methods to reduce surgery in Lehman's study, differ from our research.

### Approach

This is a retrospective evaluation of patients with dislocated groin development who underwent open reductions through prior open reduction methods. Our treatment regimen includes only open reduction (when the method of closure is unsuccessful) and performing additional bone surgery if necessary during follow-up. Hips below 12 months of age at the time of open reduction are compared with hip 12 years and 18 months.

Different results have been reported in the literature after the first open reduction to treat hip dislocations in patients under 18 months of age. Although the results of the current study are within the scope of previous reports, there are some differences. Although unsatisfactory radiological results and higher AVN were reported by a number of authors in 12-month patients 18 months of age [24,35] and in patients younger than 12 months of age [23], the negligible difference in our study.



One could argue that the radiological results of group 1 (V1) (patients 12 months and 18 months of age) are as good as group 2 (V2) (patients younger than 12 months) due to secondary surgery performed. shown in group 1 (V1). However, even if patients undergoing secondary surgery were excluded, the difference in the rate of unsatisfactory results between the two groups was not significant

In the treatment of DDH, it is necessary to achieve stable and concentric reduction in early age Develop the femoral head and acetabulum with normal values. Therefore, all structures In which preventing reduction should be intervened to get concentric reduction. Medical approach facilitates and fasten to achieve these structures. Two major and serious complications that can occur under this method are inadequate stability of the hip after a reduction and avascular necrosis due to trauma to the peritoneal femoral artery [36]. It has been reported that this technique has been applied more successfully in infants under 12 months of age although it is usually performed in children under 18 months of age [36,37]. Our findings also support data obtained from other studies in the document. Castillo and Shearman [24] have had 26 hip surgeries in case of mass disease and achieved the most favorable results in children aged 5 - 14 months. We also observed in our study that the difference between acetabular preoperative and postoperative indicators was higher in active hips between the ages of 3 - 12 months.

### Additional bone surgery

The results of the current study showed no significant difference whether the patient was younger than 12 months or 12 months of age when considering AVN and X-ray results (Table 1).

On the other hand, additional bone surgery is needed at a higher rate for patients 12 years and 18 months. A continuous improvement until the maturity of the skeleton of the AI angle, CE angle and sharp angle is noted.

One can take one of two main approaches to bone surgery in patients 12 years and 18 months. The first is to perform bone surgery and reduce open concurrent. The lower rate of additional surgery is the advantage of this method. The second is to perform bone surgery if necessary during the follow-up process. Similar to previous studies, supplemental bone surgery is required at a higher rate in 12-month patients in the current study [24-26]. Based on these results, one may recommend performing bone surgery at the time of open reduction to avoid the need for additional surgery. We, however, argue against this positive method. First, the development of acetabular improved after reducing developmental dislocations of the hip as long as concentric reduction was maintained [6,14], a finding also supported by current research with tracking to bone maturity. Secondly, to carry out bone surgery simultaneously at the time of open reduction may not further reduce bone surgery. It has been reported that the need for additional surgery has not been eliminated by adding bone surgery to reduce open [6,38]. Third, by adding bone surgery to reduce openness, one can increase the rate of AVN of the femoral head [19,39].

Acetabular bone surgery can damage acetabular growth plates which in turn can lead to residual dysplasia. Only 39% of 12-year-old 18-month-old patients underwent further bone surgery in the current study, and therefore bone surgery was not necessary for 61% of patients. Therefore, we believe that to perform concurrent bone surgery at the time of openness in patients with 12 children 18 months of age will be an excessive treatment and we recommend only bone surgery when necessary during follow-up.

All patients in the current study were skeletal maturity results, which is correct to carry out the Dislocation removal process of hip. On the other hand, this learning is open to type 2 (V2) due to the different sizes of users. Therefore, a prospective randomized study with the results of treatment (open reduction only versus open reduction plus bone surgery at the time of open reduction) in patients 12 - 18 months old with a follow-up to skeletal maturity or longer necessity of surgery. concomitant bony action at reopening time for this period

In this study, deformity of femoral head or neck or acetabulum according to Severin [22], V1/V2 with favorable result 122 hips (94.6%)/9 hips (75.0%) and none favorable 7 hips (Table 4).

### Avascular necrosis and age at operation

It is evident that the iatrogenic complication of avascular necrosis in CDH occurs after all kinds of treatment. The goal is therefore to minimize it. In our entire series of avascular necrosis diseases have been seen at 2% and partly by 20%. Changing Kalamchi and MacEwen in groups II and III or IV is only seen in 10%, mainly in children over 24 months of age [21]. The incidence of avascular necrosis correlates significantly with increasing age: in the pre-chemistry group is 14% (four hips), but three are in group I and therefore have a great prognosis. Significant necrosis occurs only on one side (3%). Two of the four patients were less than one year old, but with one nucleus, showed changes in blood vessels but the sample was too small for statistical analysis.

After 12 months of age, there was a steady increase in the rate of avascular necrosis: both sides with a total change of 19 months and 40 months left. Although level I changes prevail in the 12 to 24 months group and can recover almost completely, but in older age groups, level II and III changes predominate (Table 5).

Previous studies on age factors related to avascular necrosis have conflicted results. Kalamchi and MacEwen 1980 [21] found serious changes in blood vessels when treatment started before six months of age and similar findings were reported by Gregosiewicz and Wosko 1988 [40]. However, Grill, *et al.* 1988 [41], analyzing the use of Pavlik mining, concluded that treatment began within the first three months of life, only producing 50% of the avascular necrosis rate seen during treatment beginning in the first month. three to six months. This is supported by vascular studies of Ogden and Moss 1978 [42] demonstrated that partial head necrosis after interrupting coronary arteries before the age of five, but overall necrosis later in life. In addition, chronic dislocated hip contractions may put vessels at risk of tension and compression, outside the joints (Hensinger 1979 [1]). Surgical release of addictive substances and iliopsoas will significantly reduce this risk.

A comparison of our incidence of avascular necrosis with other series is difficult, because of the criteria for various avascular necrosis: some studies include only cases of avascular necrosis (Table 6-8). Ross and his colleagues 1988 [5], reporting on 161 hips treated with reduced openness, found that the incidence of avascular necrosis was more serious when the open reduction was done before the capital fossil. They used a similar activity to ours, regularly dividing psoas tendons. However, our series began much later, with the benefit of reports emphasizing the need to avoid extreme kidnapping and external revolving during the real estate process (Salter, Kostuik and Dallas 1969 [43]; Gage and Winter 1972 [44]). The difference in immobilization can explain the rate of reduction of our avascular necrosis. Gibson and Benson 1982 [45], reported an incidence of avascular necrosis of 5.4%, in 147 not treated with surgical removal of the extremities and bone resection, between the ages of 12 months and three years. However, they only use the criteria of Salter exit for avascular necrosis. Scaglietti and Calandriello 1962 [46] reported 24% of avascular necrosis after reducing openness in children under one year to five years old, with 22% requesting secondary procedures, but not mentioning the criteria used for Avascular necrosis.

### Avascular necrosis and conservative management

Two recent series reported incidence of avascular necrosis after conservative treatment. Grill, *et al.* 1988 [41], reported incidence of 2.38% at 3611 hips of children under 11 months of age treated with Pavlik belts. However, they only include total necrosis at the Tonni level I, II and III. In Tonni IV, the rate of avascular necrosis increased to 16%. Gregosiewicz and Wosko 1988 [40] reported incidence of 21% avascular necrosis in 254 protected treatments at different ages. They used the criteria of Kalamchi and MacEwen 1980 [21].

It is clear that iatrogenic complications of avascular necrosis in CDH occur after all types of treatment. The goal is therefore to minimize it. Our research has made certain facts clearer. The age of early declines and fossil status of the capital may not be of great significance. More importantly, it is not reduced and maintained without excessive stress on the surrounding soft tissues or undesirable pressure on the bone surface. In the case of unsuccessful closing, this is done as soon as an open operation is more likely to be a good result. Close attention to surgical and technical details is essential. Other factors that can help reduce the risk of avascular necrosis after a reduction in openness are preoperative traction, psoas tendon division, and ligament removal.

### Redislocation of the Hip

Redislocation of the hip Putti [47] distinguishes sublimation and dislocation based on the relationship between the joint of the thigh and the acetabulum. He notes that the femoral head in sublimation is placed in an unusual position in the socket, while in the dislocated position, the head lies completely out of the acetabulum. Although the surfaces are in contact with each other, the femoral head is not in a concentric or concentric position in the acetabulum. In the current study, two patients were restructured hip joints (4.5%). Rudolf and his colleagues [48] reported 3 of 54 hips with repositioning, Grill [41] reported 12 of 50 hips with repositioning and repositioning (Table 6-8).

Ruszkowski and Pucher [49] reported one of the 33 hips in 26 children with repositioning. Both Tachdjian [50] and Fixsen [51] assumed that the reasons for not maintaining hip reduction were due to poorly performed bone resection surgery, loose capsulorrhaphy and anti-femoral fever.

An exact technique of capsulorrhaphy helps to prevent the rear movement of the femur in the early postoperative period, while the hip is not repaired. Iliac bone resection in this study with improved AI is therefore easy to treat with capsulorrhaphy, lax before and can prevent hip dislocation. In this study, there were 14 hips of 198 hips (7.1%) with redistribution (Table 7).

We propose that technical failure is often the cause of reassortment with all those with an intact front follicle, with a horizontal ligament, limbus reversal, tight psoas and follicles before dense. We made with all the hips that were removed scar tissue; tenotomy add-ons; not required to release the psoas tendon, limbus transposition; Release of ligaments is required.

### Limitation of the Study

The limitation of this study is all the patients were not followed to skeletal maturity. Data of Patients in V 2 was too small. Compared V1 and V2 were non significant difference.

### Conclusion

We conclude that it is always necessary to section the adductor longus and iliopsoas tendons before attempting a reduction in the unstable or unreducible hips of infants younger than 12 months. If an arthrographically documented concentric reduction can be achieved following the tenotomies. If one fails to obtain a concentric reduction after performing these tenotomies, an open reduction is needed to obtain an anatomic reduction. The need for an open reduction increases when the preoperative dislocation grade is high. We believe that the anterior open reduction approach interval can easily and safely. The patients were divided into two Variant based on the age at the time of open reduction: older 12 months (Variant 1) and younger 12 months (Variant 2). All patients have operated hips according to Anterior open reduction approach. At latest results, both Variant were non significant difference ( $P$  valuate  $> 0.05$ ).

### Bibliography

1. Hensinger RN. "Clinical dislocation of the hip". *Clinical Symposia* 31.1 (1979): 1-31.
2. Leveufj. "Results of open reduction of "true" congenital luxation of the hip". *Journal of Bone and Joint Surgery-American Volume* 30A.4 (1948): 875-882.
3. Somerville EW. "Open reduction in congenital dislocation of the hip". *Journal of Bone and Joint Surgery-British Volume* 35B.3 (1953): 363-371.
4. Renshaw 'I'S. "Inadequate reduction of congenital dislocation of the hip". *Journal of Bone and Joint Surgery-American Volume* 63A.7 (1981): 1114-1121.
5. Ross ERS., *et al.* "Factors influencing the incidence of avascular necrosis in anterior open reduction for the congenitally dislocated hip". *Journal of Bone and Joint Surgery-British Volume* 70B (1988): 680.

6. Zions LE and MacEwen GD. "Treatment of congenital dislocation of the hip in children between the ages of one and three years". *Journal of Bone and Joint Surgery-American Volume* 68A.6 (1986): 829-846.
7. Chuinard EG. "Femoral osteotomy in the treatment of congenital dysplasia of the hip". *Orthopedic Clinics of North America* 3.1 (1972): 157-174.
8. DeRosa GP and Feller N. "Treatment of congenital dislocation of the hip: management before walking age". *Clinical Orthopaedics and Related Research* 225 (1987): 77-85.
9. Hedequist D., et al. "Use of an abduction brace for developmental dysplasia of the hip after failure of Pavlik harness use". *Journal of Pediatric Orthopaedics* 23.2 (2003): 175-177.
10. Zamzam MM., et al. "One-stage bilateral open reduction through a medial approach in developmental dysplasia of the hip". *Journal of Bone and Joint Surgery-British Volume* 91.1 (2009): 113-118.
11. Buckley SL., et al. "The acetabulum in congenital and neuromuscular hip instability". *Journal of Pediatric Orthopaedics* 11.4 (1991): 498-501.
12. Gabuzda GM and Renshaw TS. "Reduction of congenital dislocation of the hip". *Journal of Bone and Joint Surgery-American Volume* 74A.4 (1992): 624-631.
13. Vitale MG and Skaggs DL. "Developmental dysplasia of the hip from six months to four years of age". *Journal of the American Academy of Orthopaedic Surgeons* 9.6 (2001): 401-411.
14. Harris NH., et al. "Acetabular development in congenital dislocation of the hip. With special reference to the indications for acetabuloplasty and pelvic or femoral realignment osteotomy". *Journal of Bone and Joint Surgery-British Volume* 57B.1 (1975): 46-52.
15. Herring JA. "Developmental dysplasia of the hip". In: Herring JA, editor. Tachdjian's pediatric orthopaedics. 3<sup>rd</sup> edition. Volume 1. Philadelphia: WB Saunders (2002): 513-654.
16. Barrett WP., et al. "The effectiveness of the Salter innominate osteotomy in the treatment of congenital dislocation of the hip". *Journal of Bone and Joint Surgery-American Volume* 68A.1 (1986): 79-87.
17. Berkeley ME., et al. "Surgical therapy for congenital dislocation of the hip in patients who are twelve to thirty-six months old". *Journal of Bone and Joint Surgery-American Volume* 66.3 (1984): 412-420.
18. Huang SC and Wang JH. "A comparative study of nonoperative versus operative treatment of developmental dysplasia of the hip in patients of walking age". *Journal of Pediatric Orthopaedics* 17.2 (1997): 181-188.
19. Tönnis D. "Review of the Literature on Open Reduction of the Hip in Congenital Dysplasia and Dislocation of the Hip in Children and Adults". In: D. Tönnis, Ed., Die Angeborene Huftdysplasie und Huftluxation im Kindes- und Erwachsenenalter, Springer, Berlin Heidelberg New York (1987): 332-342.
20. Kleinberg S and Lieberman HS. "The Acetabular Index in Infants in Relation to Congenital Dislocation of the Hip". *Archives of Surgery* 32.6 (1936): 1049-1054.
21. Kalamchi A and MacEwen GD. "Vascular Necrosis Following Treatment of Congenital Dislocation of the Hip". *The Journal of Bone and Joint Surgery* 62.6 (1980): 876-888.

22. Severin E. "Contribution to knowledge of congenital dislocation of hip joint: late results of closed reduction and arthrographic studies of recent cases". *Acta Chirurgica Scandinavica* 84.63 (1941): 1-142.
23. Koizumi W, *et al.* "Ludloff's medial approach for open reduction of congenital dislocation of the hip. A 20-year follow-up". *Journal of Bone and Joint Surgery-British Volume* 78.6 (1996): 924-929.
24. Castillo R and Sherman FC. "Medial adductor open reduction for congenital dislocation of the hip". *Journal of Pediatric Orthopaedics* 10.3 (1990): 335-340.
25. Konigsberg DE, *et al.* "Results of medial open reduction of the hip in infants with developmental dislocation of the hip". *Journal of Pediatric Orthopaedics* 23.1 (2003): 1-9.
26. Roose PE, *et al.* "Open reduction for congenital dislocation of the hip using the Ferguson procedure. A review of twenty-six cases". *Journal of Bone and Joint Surgery-American Volume* 61A.6 (1979): 915-921.
27. Isiklar ZU, *et al.* "Is concomitant bone surgery necessary at the time of open reduction in developmental dislocation of the hip in children 12-18 months old? Comparison of open reduction in patients younger than 12 months old and those 12-18 months old". *Journal of Pediatric Orthopaedics B* 15.1 (2006): 23-27.
28. Dhar S, *et al.* "Early open reduction For Congenital Dislocation of the Hip". *Journal of Bone and Joint Surgery-British Volume* 72B.2 (1990): 175-180.
29. Weinstein SL. "Developmental hip dysplasia and dislocation". In: Morrissy RT, Weinstein SL, eds. Lovell and Winter's pediatric orthopaedics. Philadelphia: Lippincott Williams and Wilkins (2001): 905-956.
30. Malvitz TA and Weinstein SL. "Closed reduction for congenital dysplasia of the hip functional and radiographic results after an average of thirty years". *Journal of Bone and Joint Surgery-American Volume* 76.12 (1994): 1777-1792.
31. Ferguson AB. "Primary open reduction of congenital dislocation of the hip using a median adductor approach". *Journal of Bone and Joint Surgery-American Volume* 55.4 (1973): 671-689.
32. Ferguson AB Jr. "Treatment of congenital dislocation of the hip in infancy using the medial approach". In: Tachdjian MO, ed. Congenital dislocation of the hip. New York: Churchill Livingstone (1982): 283-293.
33. Morcuende JA, *et al.* "Long-term outcome after open reduction through an anteromedial approach for congenital dislocation of the hip". *Journal of Bone and Joint Surgery-American Volume* 79.6 (1997): 810-817.
34. Weinstein SL and Ponseti IV. "Congenital dislocation of the hip open reduction through a medial approach". *Journal of Bone and Joint Surgery-American Volume* 61 (1979): 119-124.
35. Lehman WB. "Early soft-tissue release in congenital dislocation of the hip". *Israel Journal of Medical Sciences* 16.4 (1980): 267-271.
36. Mascio L, *et al.* "Open reduction of developmental hip dysplasia using a medial approach: A review of 24 hips". *Acta Orthopaedica Belgica* 74.3 (2008): 343-348.
37. Mergen E, *et al.* "Medial approach open reduction for congenital dislocation of the hip using the Ferguson procedure. A review of 31 hips". *Archives of Orthopaedic and Trauma Surgery* 110.3 (1991): 169-172.
38. Mardam-Bey TH and MacEwen GD. "Congenital hip dislocation after walking age". *Journal of Pediatric Orthopaedics* 2.5 (1982): 478-486.

39. Powell EN, *et al.* "Open reduction for congenital hip dislocation: the risk of avascular necrosis with three different approaches". *Journal of Pediatric Orthopaedics* 6.2 (1986): 127-132.
40. Gregosiewicz A and Wosko I. "Risk factors of avascular necrosis in the treatment of congenital dislocation of the hip". *Journal of Pediatric Orthopaedics* 8.1 (1988): 17-19.
41. Grill F, *et al.* "The Pavlik harness in the treatment of congenital dislocating hip: report of a multicenter study of the European Paediatric Orthopaedic Society". *Journal of Pediatric Orthopaedics* 8.1 (1988): 1-8.
42. Ogden JA and Moss HL. "Pathological anatomy of congenital hip disease". In: Weil UH, ed. Progress in orthopedic surgery Volume 2. Acetabular dysplasia. Skeletal dysplasia's in childhood. Berlin, etc. Springer-Verlag (1978): 1-45.
43. Salter RB, *et al.* "Avascular necrosis of the femoral head as a complication of treatment for congenital dislocation of the hip in young children: a clinical and experimental investigation". *Canadian Journal of Surgery* 12.1 (1969): 44-61.
44. Gage JR and Winter RB. "Avascular necrosis of the capital femoral epiphysis as a complication of closed reduction of congenital dislocation of the hip: a critical review of twenty years' experience at Gillette Children's Hospital". *Journal of Bone and Joint Surgery-American Volume* 54A.2 (1972): 373-88.
45. Gibson PH and Benson MKD. "Congenital dislocation of the hip: review at maturity of 147 hips treated by excision of the limbus and derotation osteotomy". *Journal of Bone and Joint Surgery-British Volume* 64B.2 (1982): 169-175.
46. Scaglietti O and Calandriello B. "Open reduction of congenital dislocation of the hip". *Journal of Bone and Joint Surgery-British Volume* 44B (1962): 257-283.
47. Putti V. "Early Treatment of Congenital Dislocation of the Hip". *Journal of Bone and Joint Surgery* 47 (1965): 602-606.
48. Rudolf G., *et al.* "Treatment Options for Developmental Dislocation of the Hip after Walking Age". *Journal of Pediatric Orthopaedics* 14.3 (2005): 139-150.
49. Ruskowski K and Pucher A. "Simultaneous Open Reduction and Degatransiliac Osteotomy for Developmental Dislocation of the Hip in Children under 24 Months of Age". *Journal of Pediatric Orthopaedics* 25.5 (2005): 695-701.
50. Tachdjian MO. "Deformities of the lower limb". In: Tachdjian MO, editor, Pediatric orthopaedic. volume 1. 1<sup>st</sup> edition. Philadelphia, London, Toronto: W.B. Saunders Company (1972): 129-176.
51. Fixsen JA. "Anterior and Posterior Subluxation of the Hip Following Innominate Osteotomy". *Journal of Bone and Joint Surgery* 69.3 (1987): 361-364.

**Volume 10 Issue 6 June 2019**

**©All rights reserved by Nguyen Ngoc Hung, *et al.***