

PFO - Proximal Fibular Osteotomy in Medial Compartment Arthritis of the Knee with Varus Deformity

L Prakash*

Institute for Special Orthopaedics, Chennai, India

*Corresponding Author: L Prakash, Institute for Special Orthopaedics, Chennai, India.

Received: January 28, 2019; Published: April 30, 2019

Abstract

Objective: Total knee replacement is the gold standard in surgical management of osteoarthritis of the knee [1]. However, this procedure is not without its risks and complications, and is more or less considered a final irreversible solution [2]. The other established modalities for treatment of Knee OA are unicompartmental knee replacement and High tibial Osteotomy [3].

In comparison to the above-mentioned procedures, the author has devised a much simpler procedure. The Proximal Fibular Osteotomy, which provides excellent short to medium term relief in cases with medial compartment osteoarthritis.

Methods and Results: From 2006 to 2017 a total of 51 patients (87 knee joints) with medial compartment OA were treated by proximal fibular osteotomy by the first author in his clinical practice. While as from 2015 to 2017, 37 patients, (62 additional knee joints) were treated by the second author. (Total 149 knee joints in 88 patients). The preoperative tibio femoral angle was $181^\circ \pm 1.9^\circ$ which changed to $178^\circ \pm 2.0^\circ$ post operatively, while the medial joint space widened from 1.2 ± 0.7 mm to 4.5 ± 1.1 mm, both being statistically significant ($P < .001$). Likewise, the lateral joint space showed uniform reduction post operatively. From 7.2 ± 1.2 mm to 5.2 ± 1 mm ($P < .001$). VAS score on a scale of one to ten, was averaged at 6.7 pre operatively, which came down to 2.2 post operatively. Mean Functional knee score was 77 points at the end of a year, compared to 54.4 preoperatively [$< P.001$].

Conclusion: The results showed that PFO is a simple easy procedure for early medial compartment arthritis of the knee and causes a significant reduction in pain, and restoration of function.

Keywords: Osteoarthritis (OA); Proximal Fibular Osteotomy (PFO); Knee

Introduction

Osteoarthritis [OA] of the knee is a chronic, progressive degenerative disease with accompanying joint pain, stiffness, and deformity [4]. Osteoarthritis is a common joint disease, with an incidence of 30% in the population elder to 60 years [5]. The disease involves mechanical, osseous, genetic, and environmental factors [6]. Varus deformities of the knee, characterized by a femorotibial axis of less than 180° on full-leg standing AP radiographs and narrowed medial joint space, are common in patients with knee OA and affect 74% of patients with idiopathic OA [7]. In healthy knees, the medial compartment bears 60% to 80% of the load as the mechanical axis is more frequently medial to the center of the knee joint [8].

High tibial osteotomy and total knee arthroplasty are the 2 main methods used for treating osteoarthritis of the knee [9]. High tibial osteotomy is a relatively difficult procedure and has occasional complications, including neurovascular injury, iatrogenic fracture and nonunion [10,11]. Though total knee arthroplasty corrects alignment, relieves pain, and improves function, it may not be the treatment of choice in relatively younger, active patients or patients with moderate OA [12].

The proximal fibular osteotomy as procedure came about, due to the author’s experiences in the prison, where he found a dramatic relief in symptoms of medial compartment arthritis of the knee in patients who had been involved in prison riots and fractured their proximal fibulae [13]. Riots are common occurrence in prison, and the guards are taught to hit the prisoners with their lathi (baton) only below the knees, resulting in a fractured fibula in many cases. The author found that there was a dramatic improvement of symptoms, and also some degree of varus correction in these patients who sustained a fracture of their proximal fibula [14].

The author theorizes that the medial part of knee has only a single cortex support in an otherwise fully cancellous bone. This support tends to be insufficient over a period of decades with mild collapse with increasing age. The lateral part of the knee, however is supported by three cortices. One being contributed by the tibia and two from the fibula, making it rigid and relatively less collapsible. This leads to increasing varus with age and causes medial compartment OA of the knee with a gradually decreasing medial joint space [15]. With this theory in mind, the author developed the procedure of removing a 10 mm piece of fibula six to nine cm below the fibular head, to relieve medial compartment pressure and consequently realign the knee.

This purpose of this retrospective study was to analyse the clinical and radiological outcome of this procedure in 149 knee joints in 88 patients knees, with a mean follow up of 23 months. The goal was to try and find its place in the treatment algorithm of knee osteoarthritis (Figure 1-4).

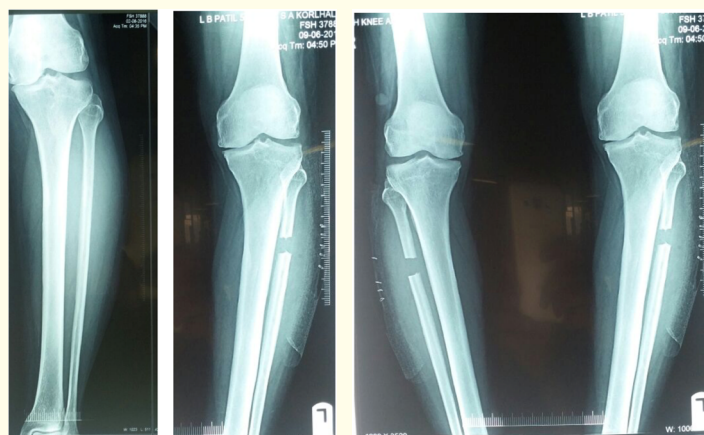


Figure 1: PFO produces consistent medial joint space widening almost immediately after surgery.

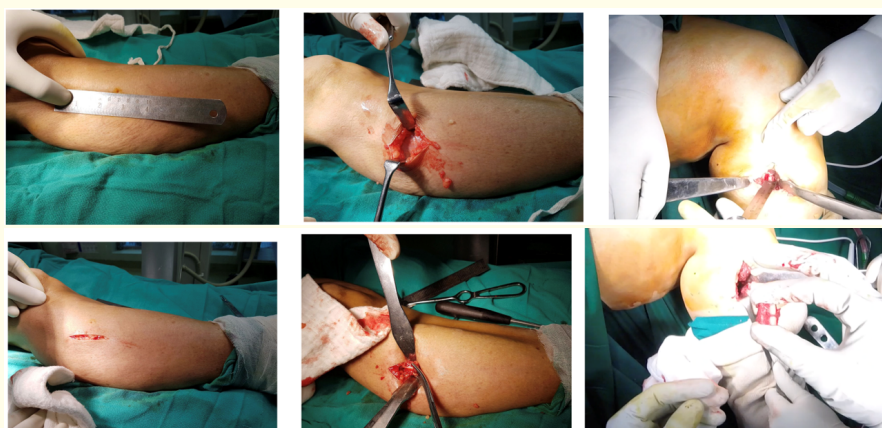


Figure 2: Surgical steps of proximal fibular osteotomy.



Figure 3: Patterns of police violence causing fibular fractures.



Figure 4: Trabecular compression causing medial collapse and OA in varus knees.

Materials and Methods

The study was independently performed in two places. The Institute for special orthopaedics Chennai and Rama Krishna Hospital Muzaffar Nagar U.P. A special consent was taken after explaining the experimental nature of this surgery to the patient.

Study population

Patients for this surgery were selected by the following criteria:

1. Medial compartment arthritis with significant symptoms of medial joint pain and knee score below 60 points.
2. Candidates who would, otherwise, be suitable for HTO or unicompartmental knee arthroplasty.
3. Those patients who gave consent for this procedure after being briefed about the complete procedure [discussion, video and clinical data].

Criteria of evaluation of results

1. Pain relief measured by VAS and Modified Oxford score [16,17].
2. Functional recovery by Modified Oxford score [17].
3. Radiological evaluation, by measurement of tibiofemoral angle, medial joint space, and lateral joint space, under standard magnification.

Surgical technique

The length of fibular segment resected was 1.5 to 2 cm, and the distance from fibular head to the proximal cut was 6 to 9 cm. The idea here was to remove the two fibular cortices, converting the knee to a more balanced joint, with unicortical support on either side, allowing correction of mechanical axis.

The resection was high enough to cause a mechanical axis shift, but not too high to damage the lateral popliteal nerve. The size of the resected segment and its distance from fibular head depends on the patient's height. Shorter patients had a 1.5 cm segment resected 6 cm below fibular head, tall patients had a 2 cm resection, some 8 to 9 cm below the fibular head.

The surgery was performed under spinal anaesthesia without a tourniquet. The tip of fibular head was marked with a skin marking pen and the appropriate distance measured.

Skin, and subcutaneous tissue were cut. The incision was a little more than twice the length of the resected segment. The fibular periosteum was exposed by separating the peroneus and soleus muscles. The periosteum was incised in line of skin incision, and a 1.5 to 2 cm piece of fibula resected with a narrow blade oscillating saw.

The wound was washed, closed in layers and a light compression bandage given. The patient was mobilized as soon as tolerated which in most cases was within a few hours. All but three cases were performed as a day care surgery.

Follow-up

Patients were followed up by the authors on day 15 (suture removal) and two, six and twelve months from the date of surgery. They were then followed up annually thereafter.

Statistical analyses

Statistical analyses were performed using PSPP software, Current Version: 0.78 (Mac); 0.10.2, from GNU.org. Continuous variables were expressed as mean \pm SD and dichotomous variables were expressed as percentages. Two-tailed *t* test was applied to analyse the Tibio Femoral angle, and lateral and medial joint spaces. The nonparametric test (Wilcoxon's signed rank test) was applied to analyse the VAS and Modified Oxford score data data. A *P* value less than .05 was considered to be significant.

Results

A total of 51 patients (87 knee joints) with medial compartment OA were treated by proximal fibular osteotomy by the first author in his clinical practice. While as from 2015 to 2017, 37 patients, (62 additional knee joints) were treated by the second author. (Total 149 knee joints in 88 patients).

In all cases a 1.5 to 2 cm section of fibula was resected 7 to 9 cm below the fibular head. A total of 88 patients [149] knees with a follow-up of more than one year were included in the study. There were 46 female, and 42 male patients. The average age of the study group was 56.3 years. The right knee was operated in 79 cases, left knee in 70 cases. In the AP and lateral standing X-rays, the Tibio femoral angle and the medial and lateral joint space were measured pre and postoperatively. In addition, the patients were evaluated on the basis of pre and post-operative Visual Analog Score, and knee scoring by the modified Oxford score developed by the author.

The preoperative tibio femoral angle was $181^\circ \pm 1.9^\circ$ which changed to $178^\circ \pm 2.0^\circ$ post operatively, while the medial joint space widened from 1.2 ± 0.7 mm to 4.5 ± 1.1 mm, both being statistically significant ($P < .001$).

Likewise, the lateral joint space showed uniform reduction post operatively. From 7.2 ± 1.2 mm to 5.2 ± 1 mm ($P < .001$).

VAS score on a scale of one to ten, was averaged at 6.7 pre-operatively, which came down to 2.2 post operatively.

Mean Functional knee score was 77 points at the end of a year, compared to 54.4 preoperatively [$P < .001$].

Preoperative complaints

- Average VAS score 6.7
- Average Modified Oxford score 54.4.

Pre-operative radiographs

- Average Tibio femoral angle $181^\circ \pm 1.9^\circ$.
- Average medial joint space 1.2 ± 0.7 mm.
- Average lateral Joint space 7.2 ± 1.4 mm.

Pre-operative clinical examination

- Range of movements 136.9 degrees.

Post-operative complaints

- Average VAS score 2.2
- Average Modified Oxford score 77.

Post-operative radiographs

- Average Tibio femoral angle $178^\circ \pm 2.0^\circ$.
- Average medial joint space 4.5 ± 2.7 mm.
- Average lateral Joint space 5.2 ± 1.4 mm.

Postoperative clinical examination

- Range of movements 137.2 degrees

As seen by the above data, all patients had significant pain relief and improvement of function. Though radiological changes were not very significant, yet there was a definite opening up of the medial joint space.

Radiological measurement	Pre-operative	Post-operative	t	P
Tibio femoral angle	$181^\circ \pm 1.9^\circ$	$178^\circ \pm 2.0^\circ$	14.7	< .001
Medial joint space	1.2 ± 0.7 mm	4.5 ± 2.7 mm	40.3	< 0.001
Lateral joint space	7.2 ± 1.4 mm	5.2 ± 1.4 mm	42.6	< 0.001

Clinical outcome	Pre-operative	Post-operative	P
VAS on ten point scale	6.7	2.2	< .001
Modified oxford score of 100 points	54.4	77	< 0.001

Discussion

Though high tibial osteotomy and unicompartmental arthroplasty have both been described for treatment of medial compartmental arthritis, both of these are relatively major procedures [18].

There is a relative paucity of published literature on the role of proximal fibular osteotomy in medial compartment osteoarthritis of the knee. One Chinese study showed uniformly good results up to four to five years [19].

With increasing age reduction of bone mass is a common occurrence. Just as in the vertebral column where there is a dorsal collapse due to a single cortical support, as opposed to stronger posterior support, in knee joints too, a gradual increasing varus occurs with age causing medial compartment arthritis [19]. Resecting a segment of fibula, loosens the lateral side allowing the upper tibia to settle into a more favorable lateral alignment, shifting the mechanical axis towards neutral or valgus [20].

The HTO is technically demanding. Several complications can occur. In a study by Lee, *et al.* the parameters of surgical errors were defined by three separate factors [21]:

1. Correction error (under- and overcorrection).
2. Excessive posterior slope change
3. The presence of a lateral hinge fracture.

The goals of HTO are to reduce knee pain and delay the need for a knee replacement. To achieve these goals, appropriate patient selection, precise surgical planning, precise surgical techniques, and prevention of complications are essential.

In contrast, the only point to be taken care of in doing a PFO is the stretching of the lateral popliteal nerve. In our study we observed a reversible foot drop (1 patient), EHL weakness (8 patients), and troublesome paresthesia (7 patients) over the dorsum of the foot.

Our study showed that proximal fibular osteotomy decreased the operation time, bleeding amount during operation and drainage volume after operation while shortened the full weight-bearing time; decreased the pain VAS and FTA and increased the JOA score of the knee joint; and decreased the incidence of complications [no risk of fracture or slope problems].

This study also shows that PFO is a reliable, and safe alternative to both HTO and unicompartmental replacement. We also observed that results are reproducible.

We acknowledge the limitations of the study. The small numbers, retrospective nature and short-term follow-up were areas where future studies are required to seal the debate conclusively.

Conclusions

1. PFO is a simple easy procedure for early medial compartment osteoarthritis of the knee and it causes a significant reduction in pain.
2. It is a relatively minor daycare procedure which is less invasive than High Tibial Osteotomy or Unicompartmental arthroplasty.
3. Care should be taken to avoid Lateral Popliteal Nerve injuries.

Disclaimers

No benefits of any form accrued to either author in any manner whatsoever.

Bibliography

1. Prakash L. "A beginner's guide to total knee replacement". CBS Publications, New Delhi (2016).
2. Tierney WM., *et al.* "Tricompartmental knee replacement: A comparison of orthopaedic surgeons' self reported performance rates with surgical indications, intraindications, and expected out-comes". *Clinical Orthopaedics* 305 (1994): 209-217.
3. Felson DT., *et al.* "The prevalence of knee osteoarthritis in the elderly: The Framingham Osteoarthritis Study". *Arthritis and Rheumatology* 30.8 (1987): 914-918.
4. Vincent KR., *et al.* "The pathophysiology of osteoarthritis: a mechanical perspective on the knee joint". *PM&R* 4.5 (2012): S3-S9.
5. Shiozaki H., *et al.* "Epidemiology of osteoarthritis of the knee in a rural Japanese population". *Knee* 6.3 (1999): 183-188.
6. Ahlbäck S. "Osteoarthrosis of the knee: a radiographic investigation". *Acta Radiologica* 277 (1968): 7-72.

7. Prakash L. "Varus Scenario in the Indian Knees". Indian Academy of Orthopaedic Surgeons, Instructional course lectures (2016).
8. Wu LD., *et al.* "A long- term follow-up study of high tibial osteotomy for medial compartment osteoarthritis". *Chinese Journal of Traumatology* 7.6 (2004): 348-353.
9. Sprenger TR and Doerzbacher JF. "Tibial osteotomy for the treatment of varus gonarthrosis: survival and failure analysis to twenty-two years". *Journal of Bone and Joint Surgery-American Volume* 85A.3 (2003): 469- 474.
10. Aglietti P, *et al.* "A high tibial valgus osteotomy for medial gonarthrosis: a 10- to 21-year study". *Journal of Knee Surgery* 16.1 (2003): 21-26.
11. Hanssen AD., *et al.* "Surgical options for the middle aged patient with osteoarthritis of the knee joint". *Joint Bone Spine* 67.6 (2000): 504-508.
12. Schnurr C., *et al.* "Pre-operative arthritis severity as a predictor for total knee arthroplasty patients' satisfaction". *International Orthopaedics* 37.7 (2013): 1257-1261.
13. Prakash L. "Orthopaedics Usual and unusual". Indian Academy of Orthopaedic Surgeons, Instructional course lectures (2016).
14. Prakash L. "Proximal Fibular Osteotomy". Indian Academy of Orthopaedic Surgeons, Instructional course lectures (2016).
15. Zhang Y, *et al.* "The pathogenesis research of non-uniform settlement of the tibial plateau in knee degeneration and varus". *Journal of Hebei Medical University* 35.2 (2014): 218-219.
16. Huskisson E. "Measurement of pain". *Lancet* 304.7889 (1974): 1127-1131.
17. Prakash L. "Knee Scoring and Outcome Prediction in developing a surgical paradigm of total knee replacement". Indian Academy of Orthopaedic Surgeons, Instructional course lectures (2016).
18. Hofmann S., *et al.* "Osteotomies of the knee joint in patients with monocompartmental arthritis". *Orthopade* 38.8 (2009): 755-769.
19. Yang ZY, *et al.* "Medial Compartment Decompression by Fibular Osteotomy to Treat Medial Compartment Knee Osteoarthritis: A Pilot Study". *Orthopedics* 38.12 (2015): e1110-e1114.
20. Wang F, *et al.* "Influence of knee lateral thrust gait to femorotibial angle and lateral joint space in the knee varus patients". *Chinese Journal of Orthopaedics* 25.9 (2005): 517-519.
21. Kim JH., *et al.* "Leg length change after opening wedge and closing wedge high tibial osteotomy: a metaanalysis". *PLoS One* 12.7 (2017): e0181328.

Volume 10 Issue 5 May 2019

©All rights reserved by L Prakash.